



## Just the facts: ultrasound guidance for arthrocentesis

Zafrina Poonja<sup>1,2</sup> · Justin S. Ahn<sup>1,3</sup> · Daniel J. Kim<sup>1,2</sup>

Received: 4 June 2021 / Accepted: 19 July 2021 / Published online: 4 August 2021

© The Author(s), under exclusive licence to Canadian Association of Emergency Physicians (CAEP)/ Association Canadienne de Médecine d'Urgence (ACMU) 2021

### Clinical Scenario

A 55-year-old male with a history of hypertension and diabetes presents to the emergency department (ED) with a 3 day history of atraumatic left ankle swelling. His ankle is swollen, tender, and mildly erythematous. He has been having increasing difficulty with weightbearing over the past few days. The clinician wonders whether this is septic arthritis or an inflammatory arthropathy.

### Key clinical questions

#### What is the accuracy of the physical examination for joint effusions?

Although knee effusions are commonly believed to be clinically obvious, the diagnostic accuracy of physical examination tests lack accuracy and varies with examiner experience. A recent systematic review found the bulge sign to be 33% sensitive and the patellar tap to be only 15% sensitive for knee effusion [1]. Multiple studies have demonstrated that ultrasound is superior to clinical examination in the detection and localization of a knee effusion, as the physical examination is 69% sensitive and 85% specific compared to ultrasound [1]. When reviewing the clinical examination for septic arthritis, only joint pain, history of joint swelling, and fever were found in more than 50% of patients [2]. Point of care ultrasound (POCUS) should be used as an adjunct to the physical examination for diagnosing joint effusion.

✉ Zafrina Poonja  
zafrinapoonja@gmail.com

<sup>1</sup> Department of Emergency Medicine, University of British Columbia, Vancouver, BC, Canada

<sup>2</sup> Department of Emergency Medicine, Vancouver General Hospital, 855 12th Ave W, Vancouver, BC V5Z 1M9, Canada

<sup>3</sup> Department of Emergency Medicine, Royal Columbian Hospital, New Westminster, BC, Canada

#### How can point-of-care ultrasound be used in the workup of a joint effusion?

POCUS is a helpful bedside tool that can assist in determining the etiology of an acutely swollen joint. It can determine if a joint effusion is present, the size of the effusion, and if the effusion is simple or complex. Effusions are typically characterized by an anechoic or sometimes heterogenous fluid collection in the joint space. The contralateral joint can be scanned to establish the appearance of a normal joint if there is uncertainty. Ultrasound is also helpful in identifying other causes of a swollen joint, like cellulitis, bursitis, hematoma, or abscess [3]. Ultrasound can be used to landmark for arthrocentesis, identify important adjacent structures (e.g. vessels, nerves) and provide real-time guidance which has been shown to improve arthrocentesis success by 21% and decrease procedure-related pain [4]. Real-time guidance is especially helpful for small effusions (e.g. ankle) or difficult-to-access joints (e.g. hip).

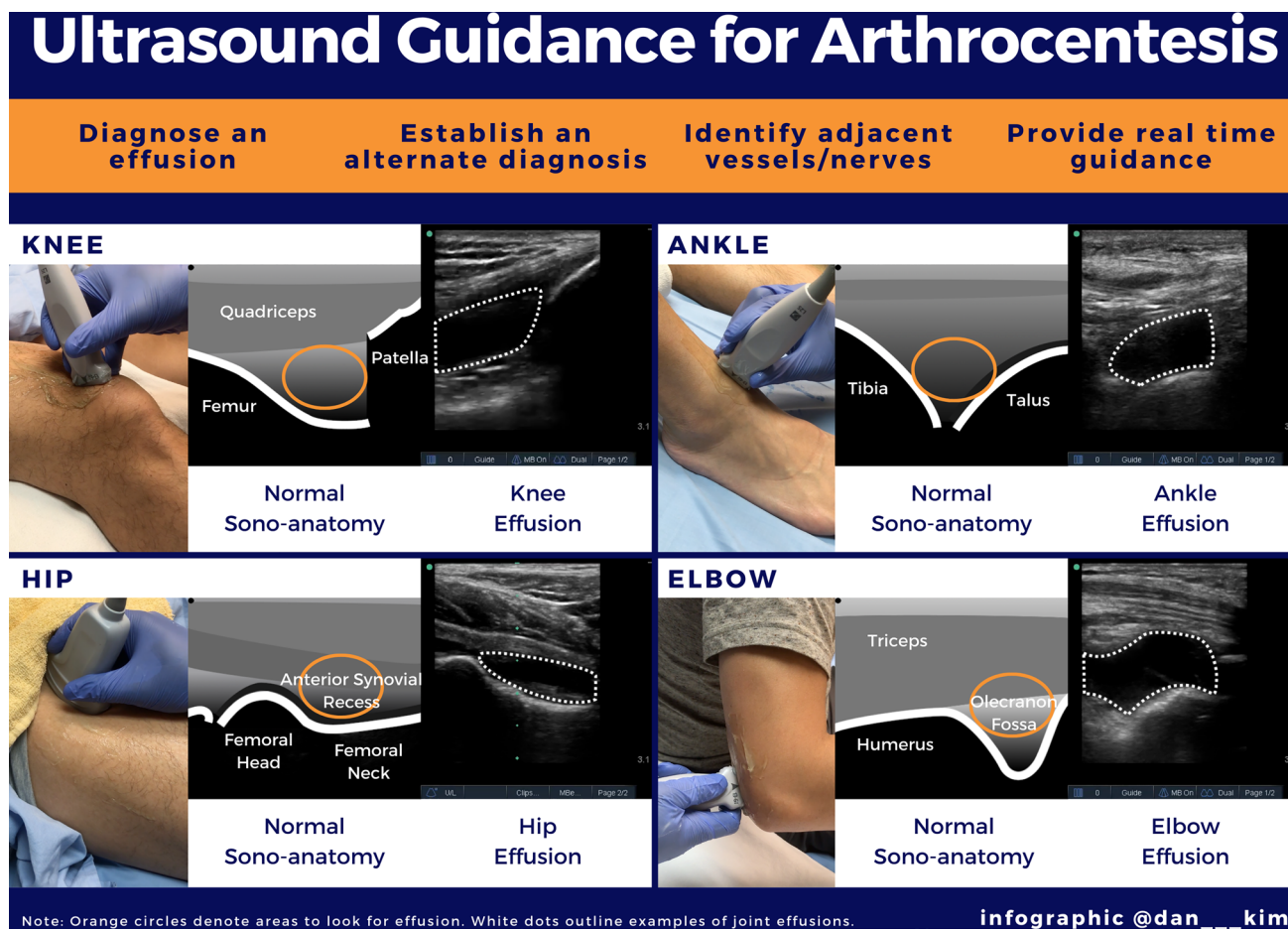
#### What is the ultrasound approach for identifying a joint effusion of the knee, ankle, hip, and elbow?

##### Knee

The suprapatellar bursa communicates with the knee joint, so if there is fluid in the suprapatellar bursa, the patient has a knee effusion. The suprapatellar bursa is located under the distal quadriceps tendon, just proximal to the patella. Using the linear probe in the longitudinal plane, slide the probe caudally in line with the long axis of the femur to the patella [5]. The area of interest is under the quadriceps tendon, anterior to the distal femur (Fig. 1).

##### Ankle

Using the linear probe in the longitudinal plane, slide the probe down the distal tibia until the tibiotalar joint is noted. The area of interest is the tibiotalar joint (Fig. 1). It is helpful



**Fig. 1** Approach to identifying joint effusions in the knee, ankle, hip, and elbow using point of care ultrasound

to identify the dorsalis pedis artery prior to aspiration of the joint [5].

### Hip

Using the curvilinear probe (or possibly linear probe in pediatrics), with the marker pointed to the umbilicus, place the probe in line with the femoral neck. Slide the probe towards the groin until the femoral head and neck are visualized. The area of interest is the anterior synovial recess anterior to the femoral neck (Fig. 1). Cartilage in this region can have the appearance of fluid, but cartilage follows the contour of the bone, does not distend outwards, and measures <5 mm in depth.

### Elbow

In elbow effusions, fluid develops in the posterior joint capsule which will appear as fluid in the olecranon fossa on ultrasound. Using the linear probe in the longitudinal plane,

slide the probe along the long axis of the humerus towards the olecranon until the olecranon fossa is visualized (Fig. 1).

### What laboratory testing should be performed on synovial fluid?

Synovial fluid should always be sent for culture and gram stain, cell count and differential, and crystals. Other laboratory tests like protein and glucose are not helpful [2]. If only a small amount of fluid is obtained, the priority test should be culture, as the sensitivity of gram stain is anywhere between 29 and 50% [2].

### How do you interpret the results of the synovial fluid analysis?

When looking at synovial fluid, the main values of interest are the synovial white cell count and percent polymorphonuclear cells (PMNs). Different synovial white cell counts have increasing interval likelihood ratios (LR) for the diagnosis of septic arthritis: <25,000 has a LR of 0.33, 25,000–50,000

has a LR of 1.06, 50,000–100,000 has a LR of 3.59, and > 100,000 has a LR of infinity [6]. Percent PMNs > 90% has a positive LR of 3.4 and a negative LR of 0.34 [2]. Typical practice invokes a synovial white cell count cut off of 50,000 to distinguish septic arthritis from inflammatory or non-inflammatory arthritis. However, no single value can determine if the fluid is indicative of a non-inflammatory, inflammatory, or infectious process. In particular, suspected prosthetic joint infections should be discussed with orthopedic surgery, as they may prefer to perform the procedure. Septic arthritis of a prosthetic joint has different synovial white cell count cut offs (1700) [7]. The clinical picture, along with these values, should be considered when determining if a patient requires further treatment.

Finally, when looking at synovial fluid for crystals, the presence of monosodium urate crystals indicates gout, while the presence of calcium pyrophosphate crystals indicates pseudogout. The presence of crystals does not necessarily rule out septic arthritis, but overall, rates of concomitant septic and inflammatory arthritis are not high (some case series have found rates up to 5%) [8].

## Case resolution

Using POCUS, the clinician identifies a small effusion in the tibiotalar joint and drains it using real-time guidance. The synovial fluid analysis reveals a white cell count of 30,000, percent PMNs 70%, and monosodium urate crystals. The patient is diagnosed with gout, started on nonsteroidal anti-inflammatories, and discharged home.

## Declarations

**Conflict of interest** ZP and JSA do not report any conflicts of interest. DJK is on the medical advisory board of Clarius Mobile Health.

## References

1. Meyer R, Lin C, Yenokyan G, Ellen M. Diagnostic utility of ultrasound versus physical examination in assessing knee effusions: a systematic review and meta-analysis. *J Ultrasound Med*. 2021. <https://doi.org/10.1002/jum.15676>.
2. Margaretten ME, Kohlwes J, Moore D, Bent S. Does this adult patient have septic arthritis? *JAMA*. 2007;297:1478–88.
3. Adhikari S, Blaivas M. Utility of bedside sonography to distinguish soft tissue abnormalities from joint effusions in the emergency department. *J Ultrasound Med*. 2010;29:519–26.
4. Wu T, Dong Y, Song HX, Fu Y, Li JH. Ultrasound-guided versus landmark in knee arthrocentesis: a systematic review. *Semin Arthritis Rheum*. 2016;45(5):627–32.
5. Fessell DP, Jacobson JA, Craig J, Habra G, Prasad A, Radliff A, van Holsbeeck MT. Using sonography to reveal and aspirate joint effusions. *AJR Am J Roentgenol*. 2000;174:1353–62.
6. Carpenter CR, Schuur JD, Everett WW, Pines JM. Evidence-based diagnostics: adult septic arthritis. *Acad Emerg Med*. 2011;18:781–96.
7. Osmon DR, Berbari EF, Berendt AR, Lew D, Zimmerli W, Steckelberg JM, Rao N, Hanssen A, Wilson WR. Diagnosis and management of prosthetic joint infection: clinical practice guidelines by the Infectious Diseases Society of America. *Clin Infect Dis*. 2013;56:e1–25.
8. Papanicolaos LE, Hakendorf P, Gordon DL. Concomitant septic arthritis in crystal monoarthritis. *J Rheumatol*. 2012;39:157–60.