
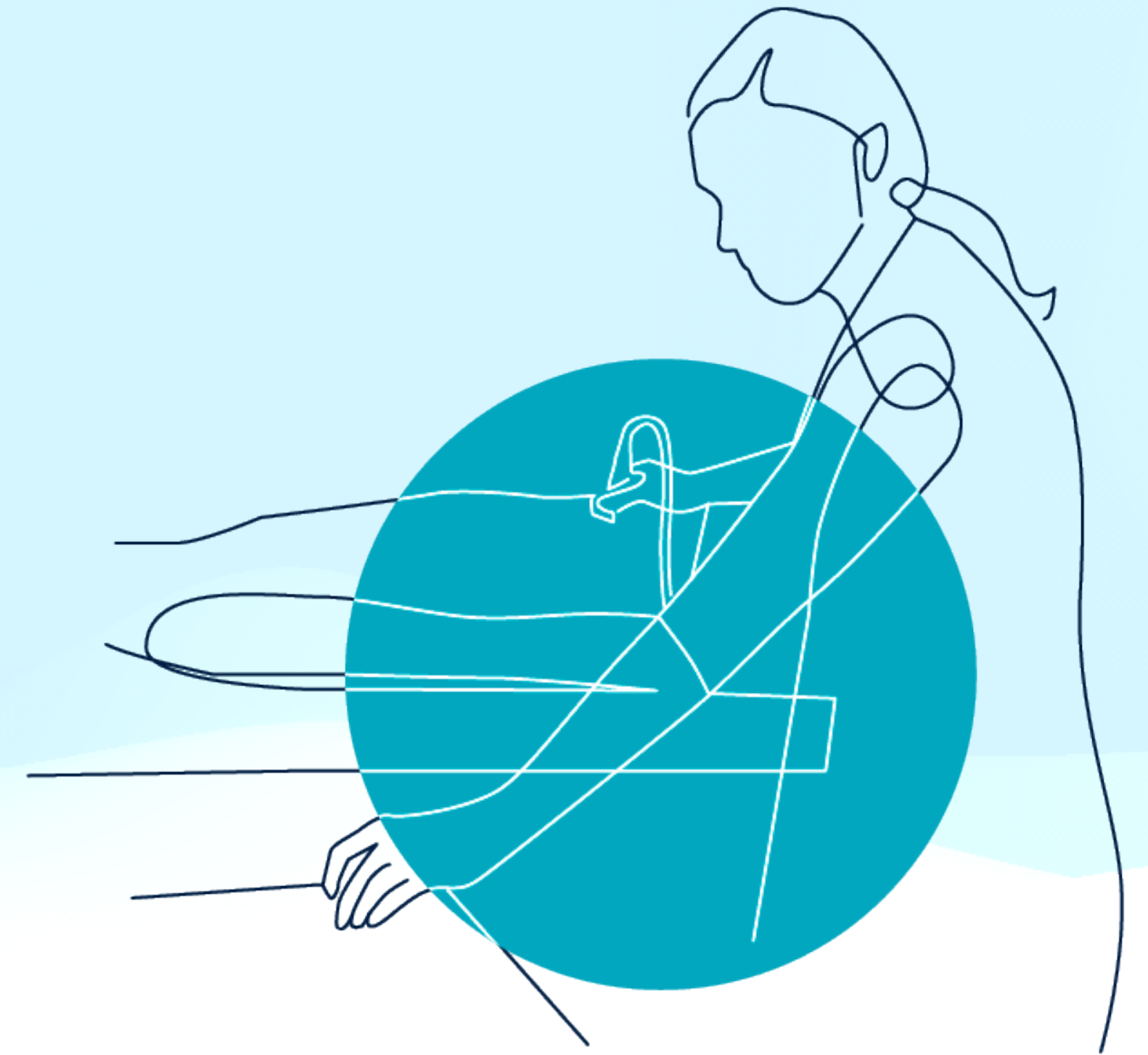

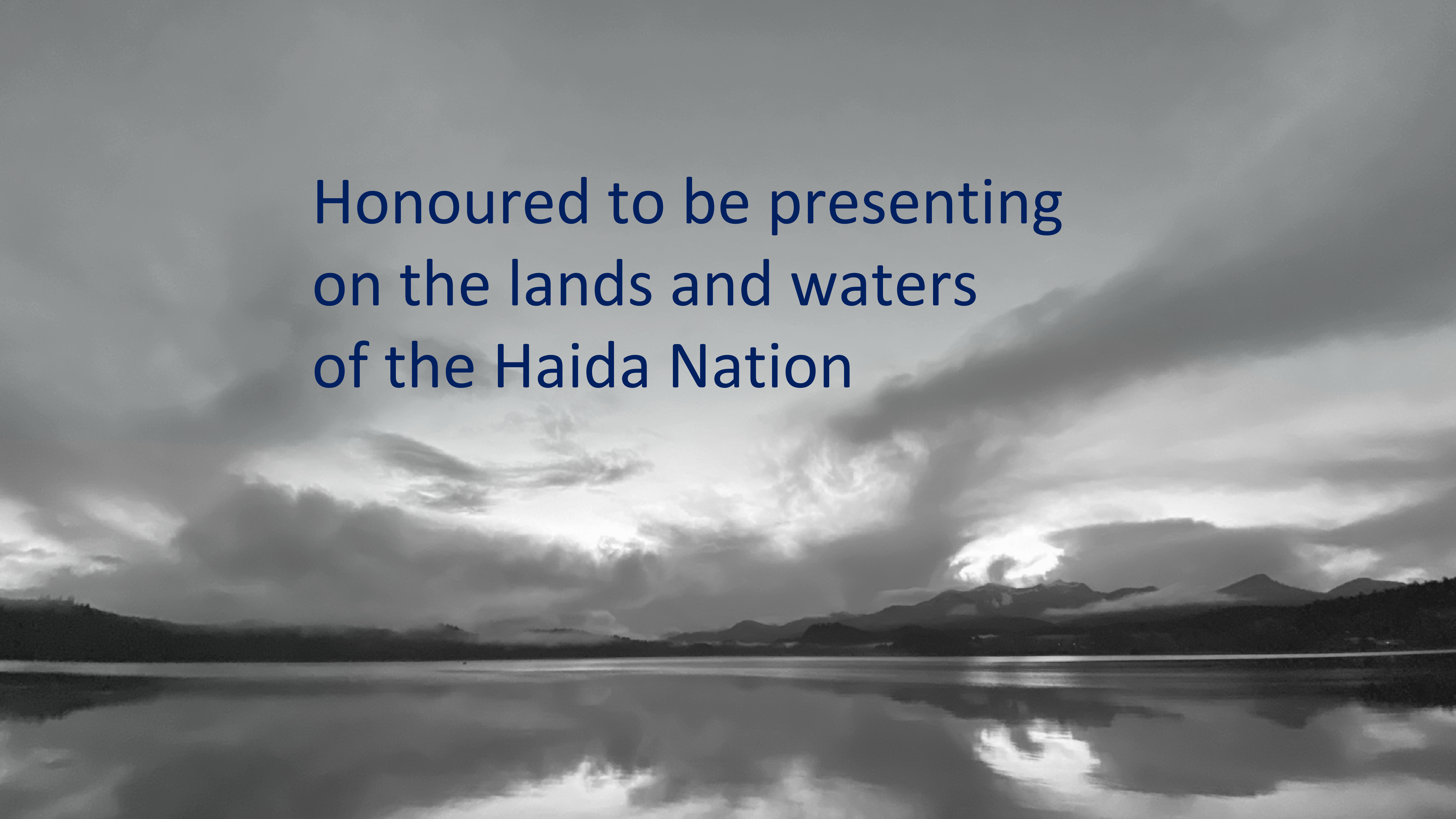
The Achilles

Tracy Morton MD
Oct 27 2023



THE UNIVERSITY OF BRITISH COLUMBIA
Continuing Professional Development
Faculty of Medicine

Honoured to be presenting
on the lands and waters
of the Haida Nation



Tracy Morton, MD CCFP
Haida Gwaii Hospital & Health Centre
Village of Daajing Giids, Haida Gwaii BC

Disclosures

Honoraria: RCCBC for POCUS work
UBC CPD for planning, development
and presenting

No commercial disclosures

Rural Coordination
Centre of BC



UBC Continuing
Professional
Development
CPD Medicine

Tracy Morton, MD CCFP
Haida Gwaii Hospital & Health Centre
Village of Daajing Giids, Haida Gwaii BC

Disclaimers

Rural generalist
POCUS – supplemental to exam
Get definitive imaging

Objectives

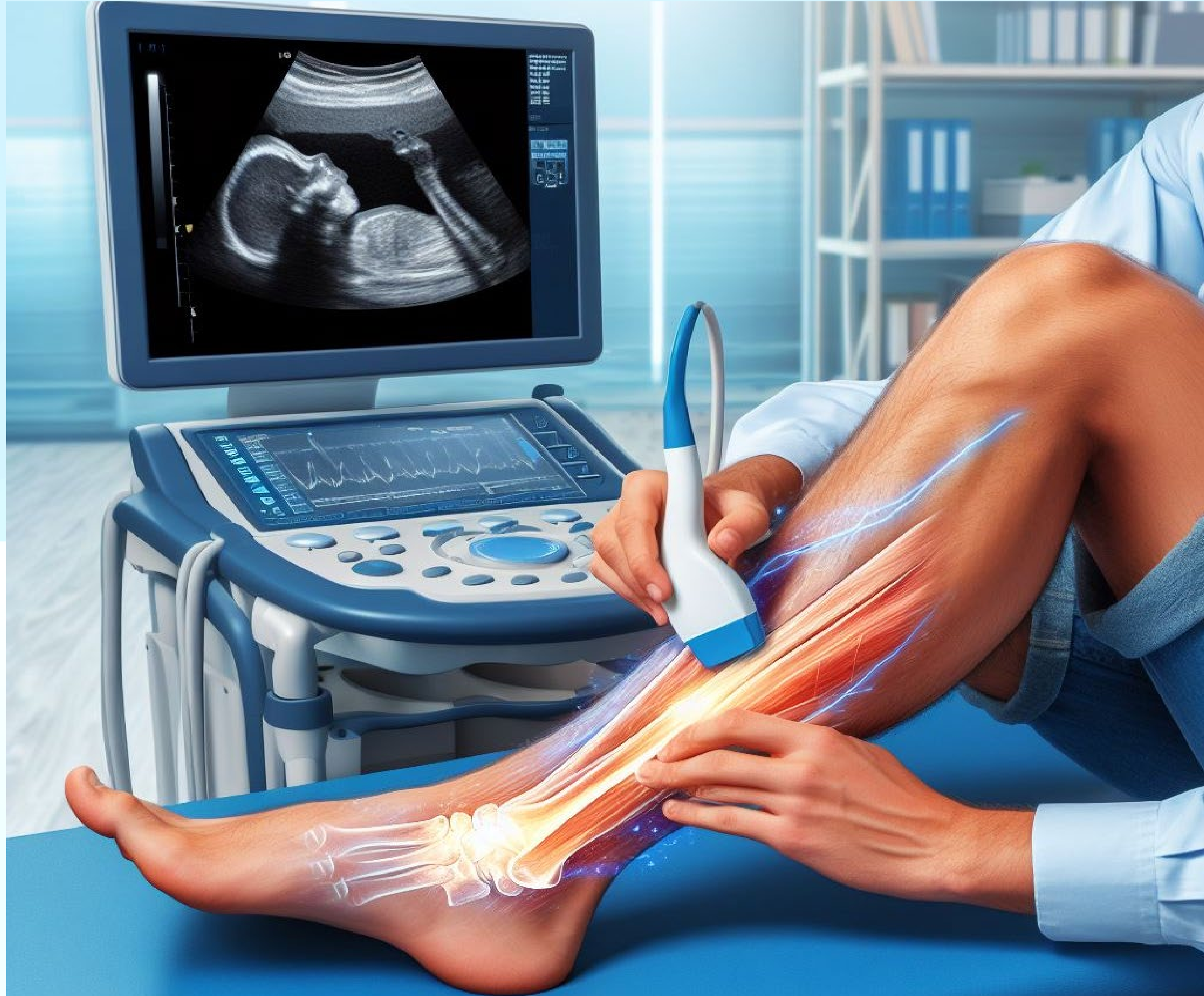

(Sono)anatomy

Tears

Tendinosis

Bursitis

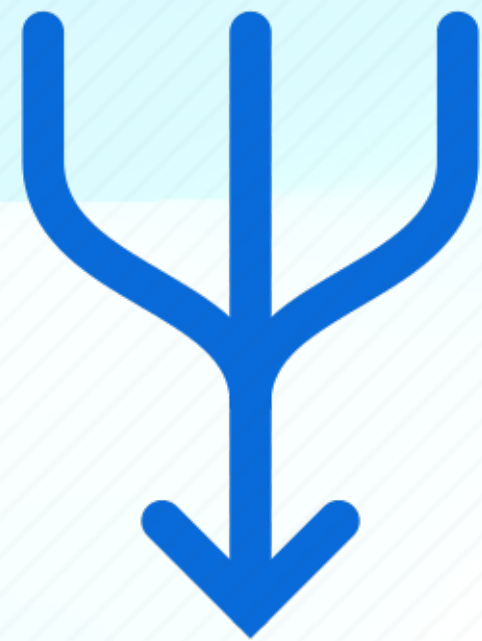



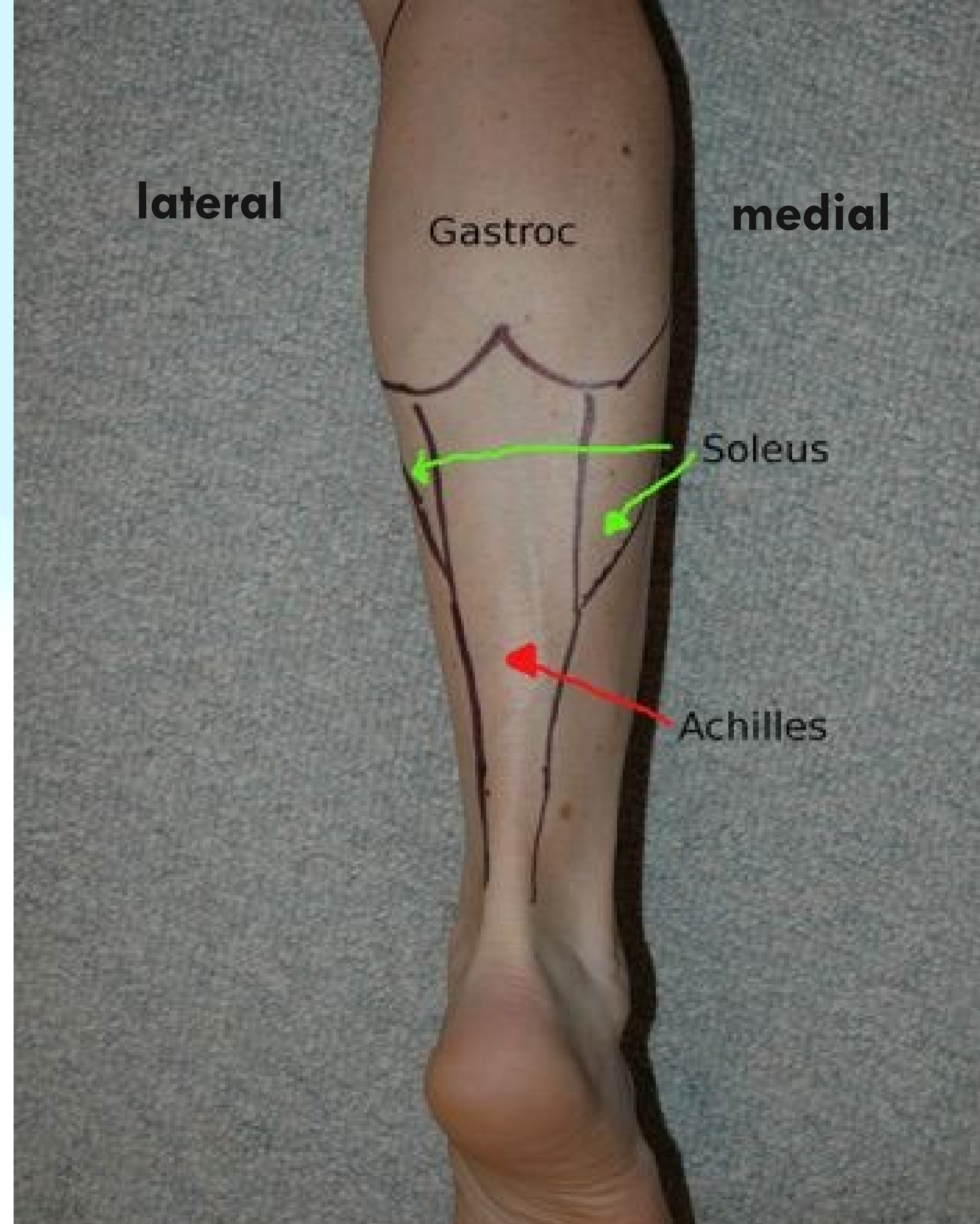
ANATOMY

ANATOMY

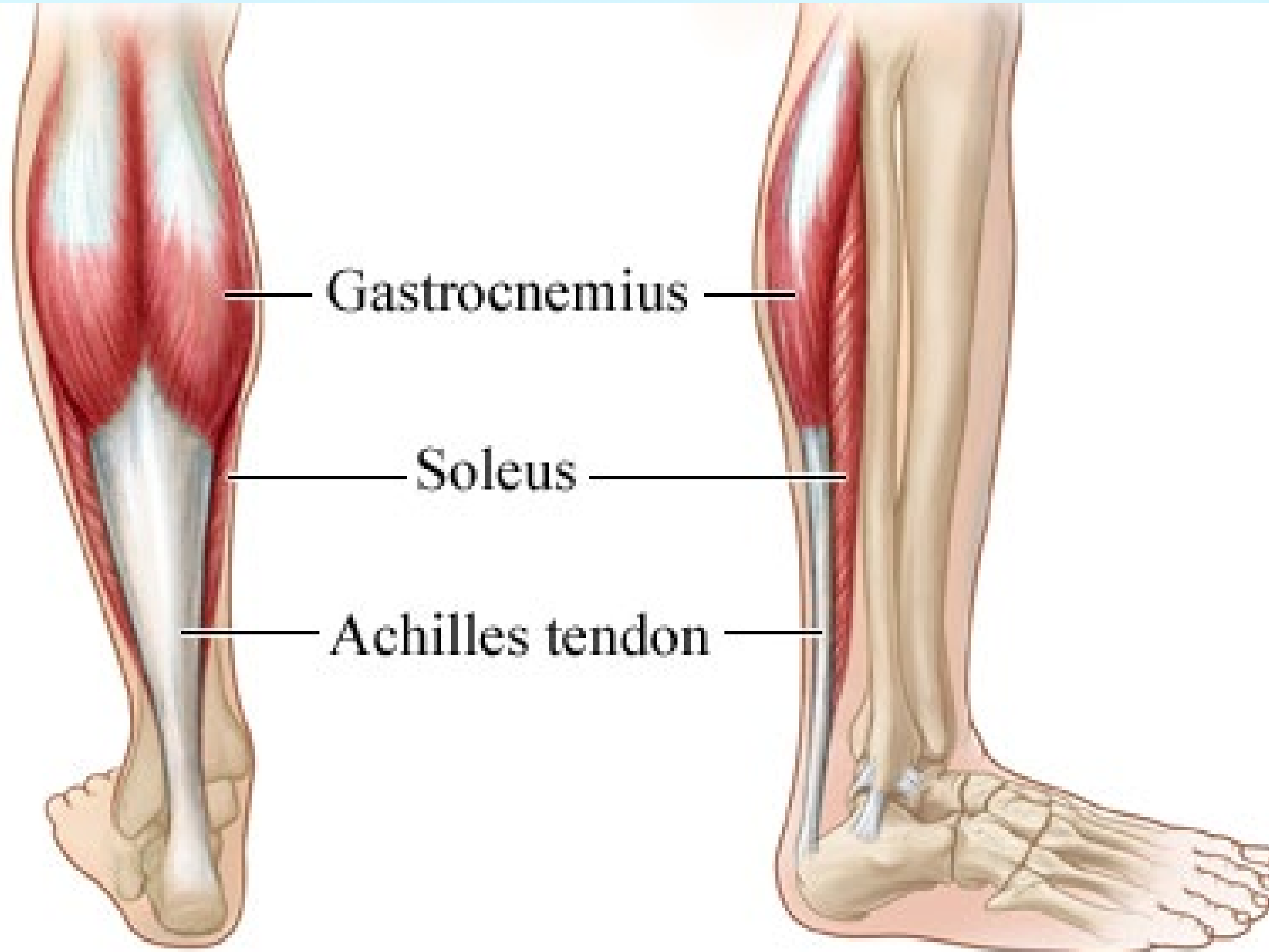
“Gastrocsoleus”



Achilles tendon



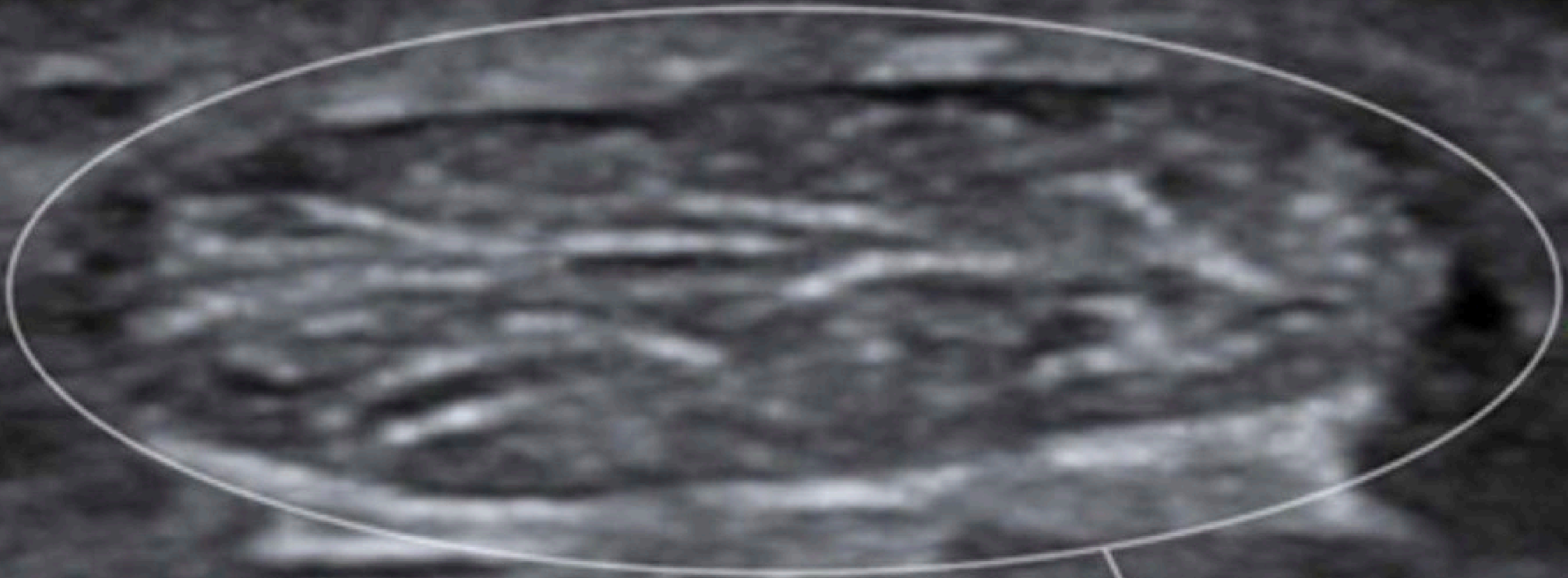
“GASTROCSOLEUS”



Soleus



B



Achilles Tendon

width:
12-25 mm

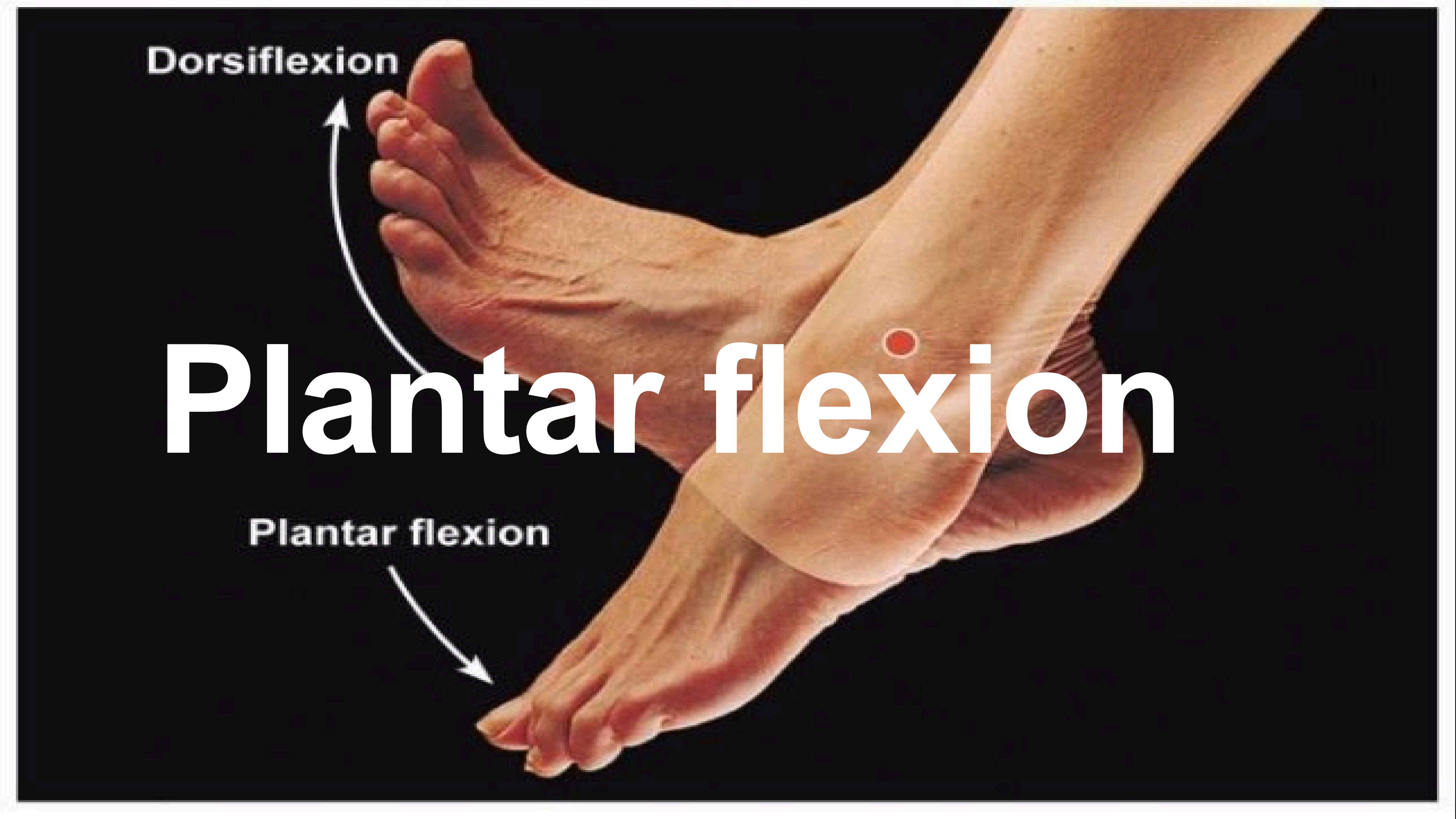


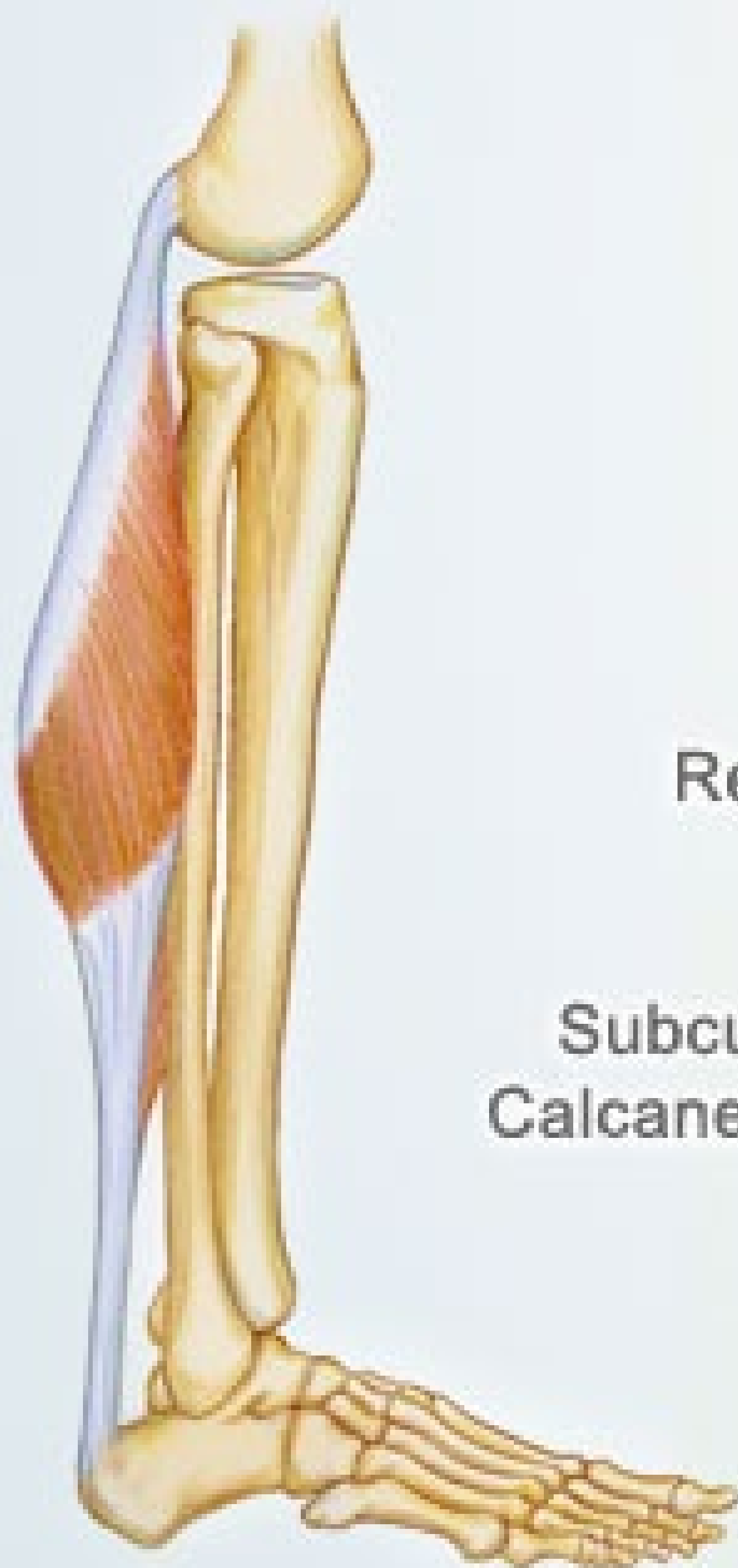Dorsiflexion



Plantar flexion

Plantar flexion



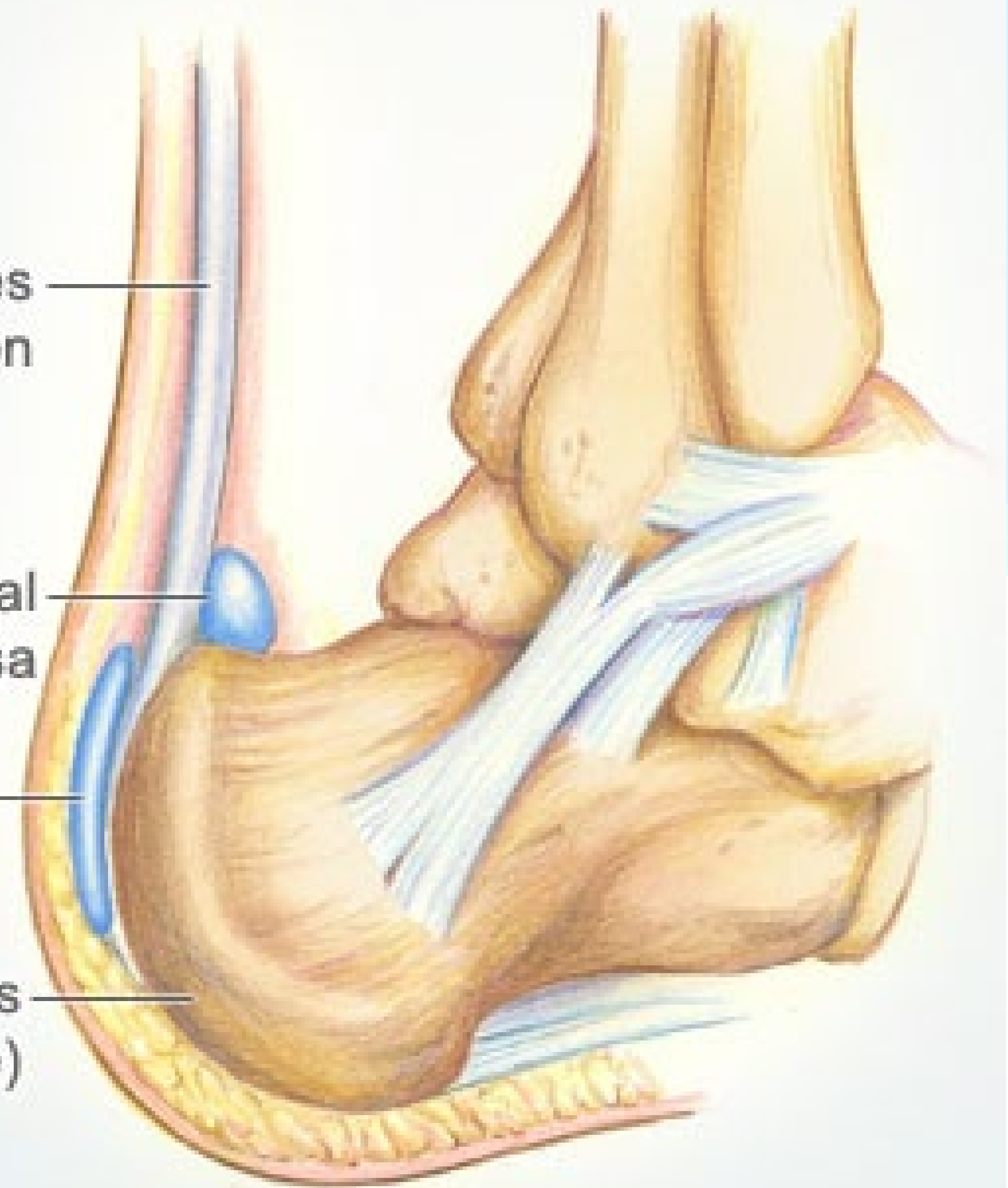


Achilles Tendon

Retro-calcaneal Bursa

Subcutaneous Calcaneal Bursa

Calcaneus (Heel Bone)

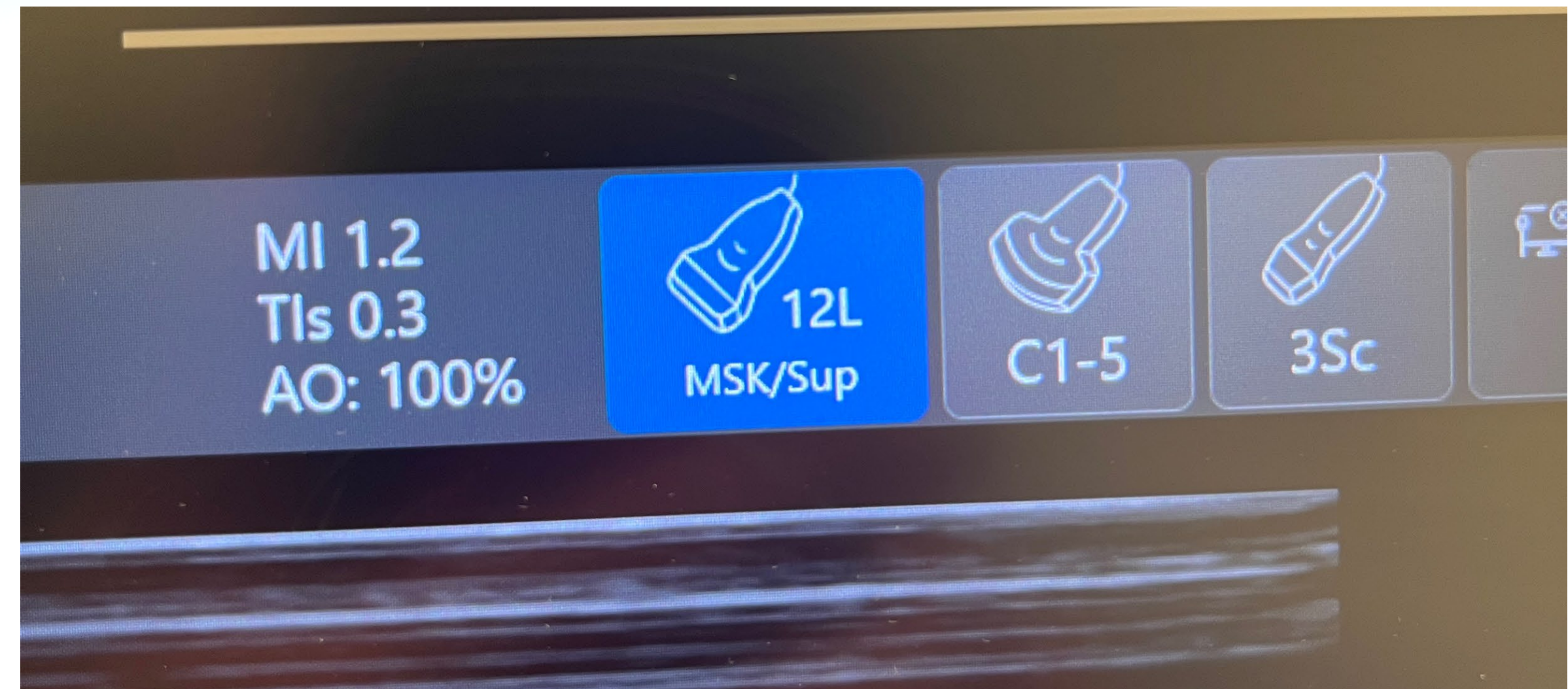


SONOANATOMY

Linear probe



MSK preset

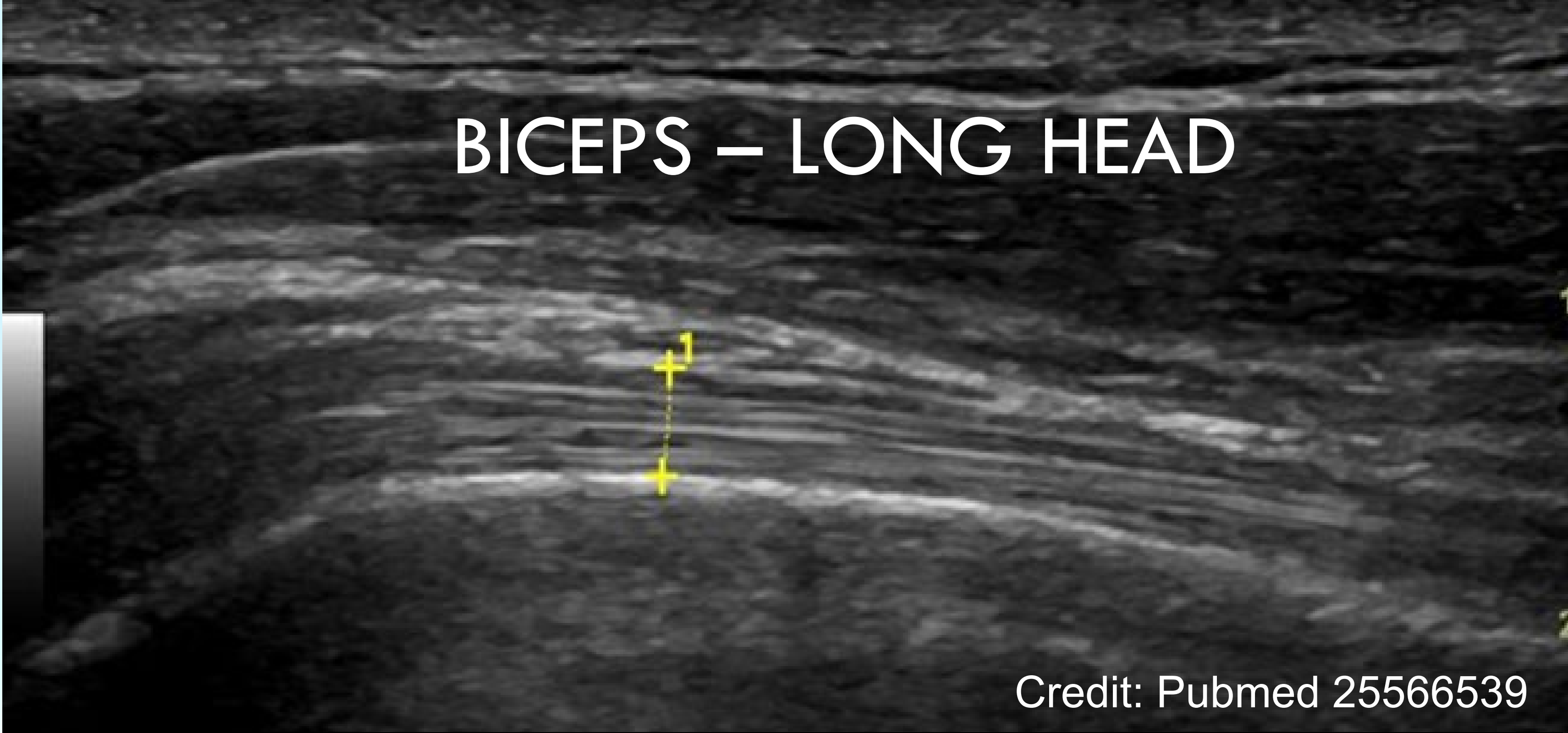


TENDONS ON ULTRASOUND

Hyperchoic

Parallel fibres

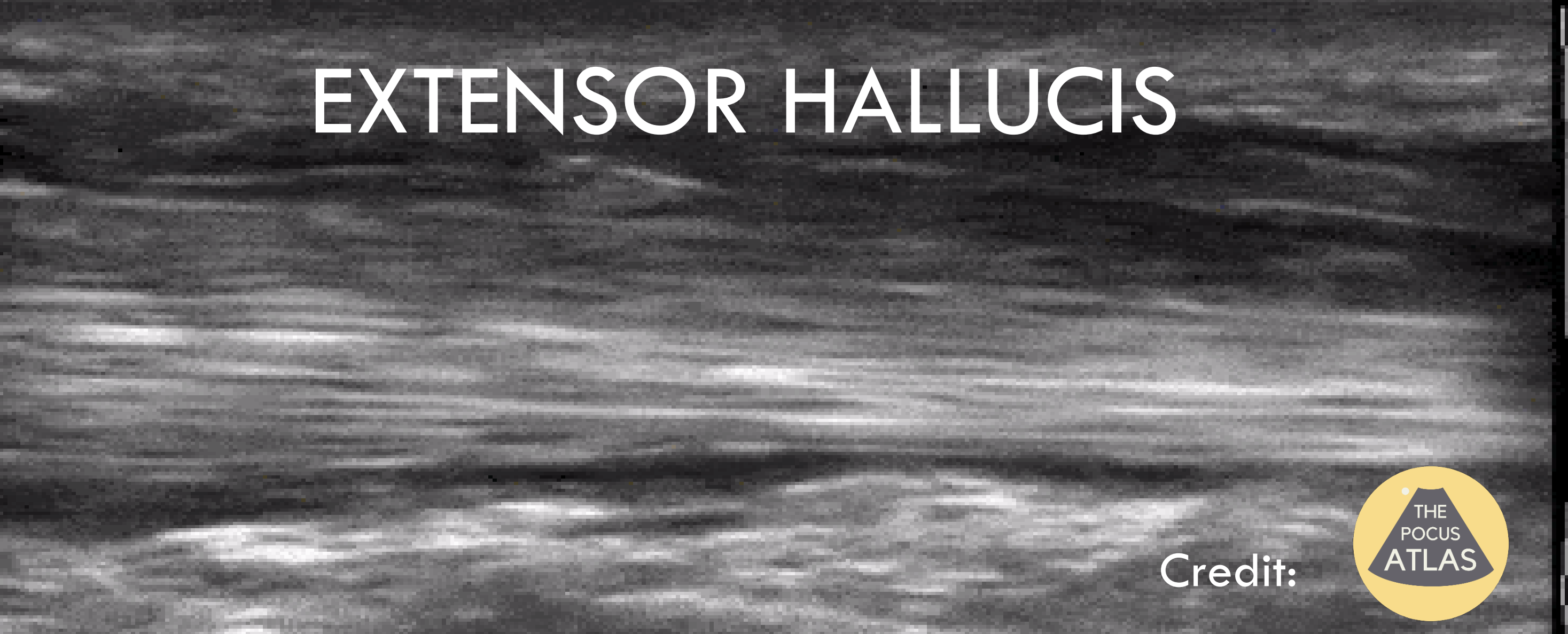Tendon sheath



BICEPS – LONG HEAD

Credit: Pubmed 25566539

P

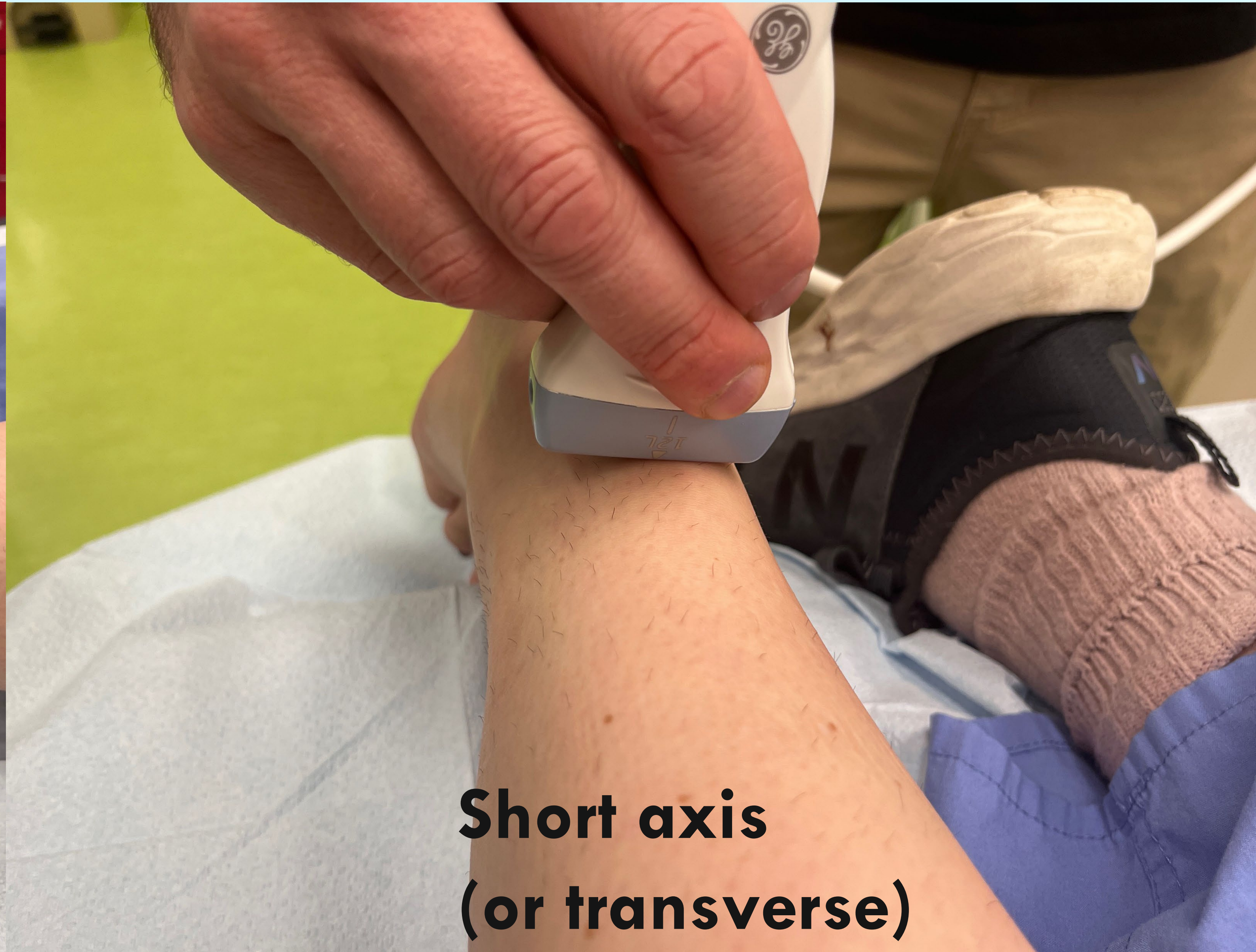
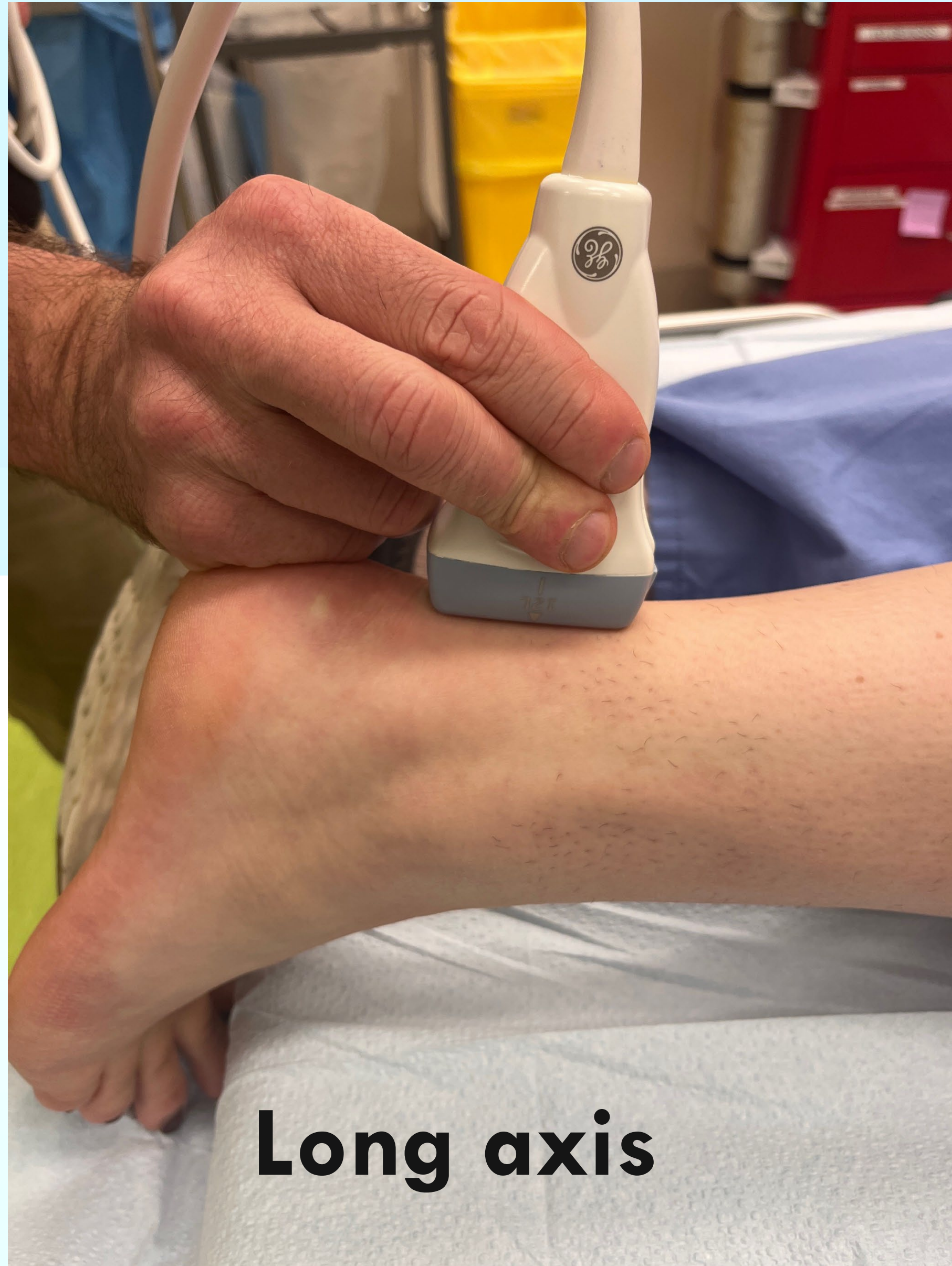
EXTENSOR HALLUCIS

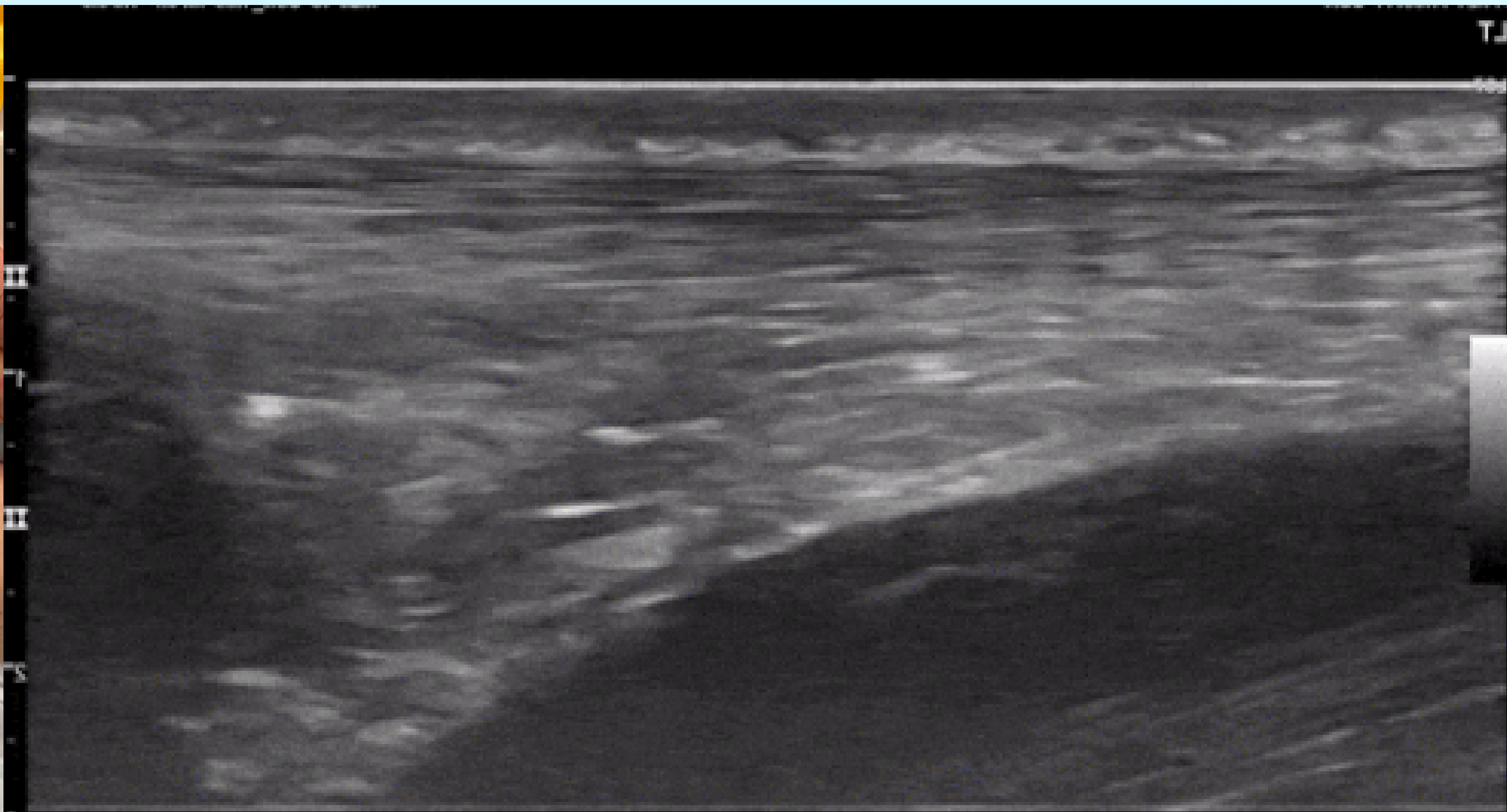
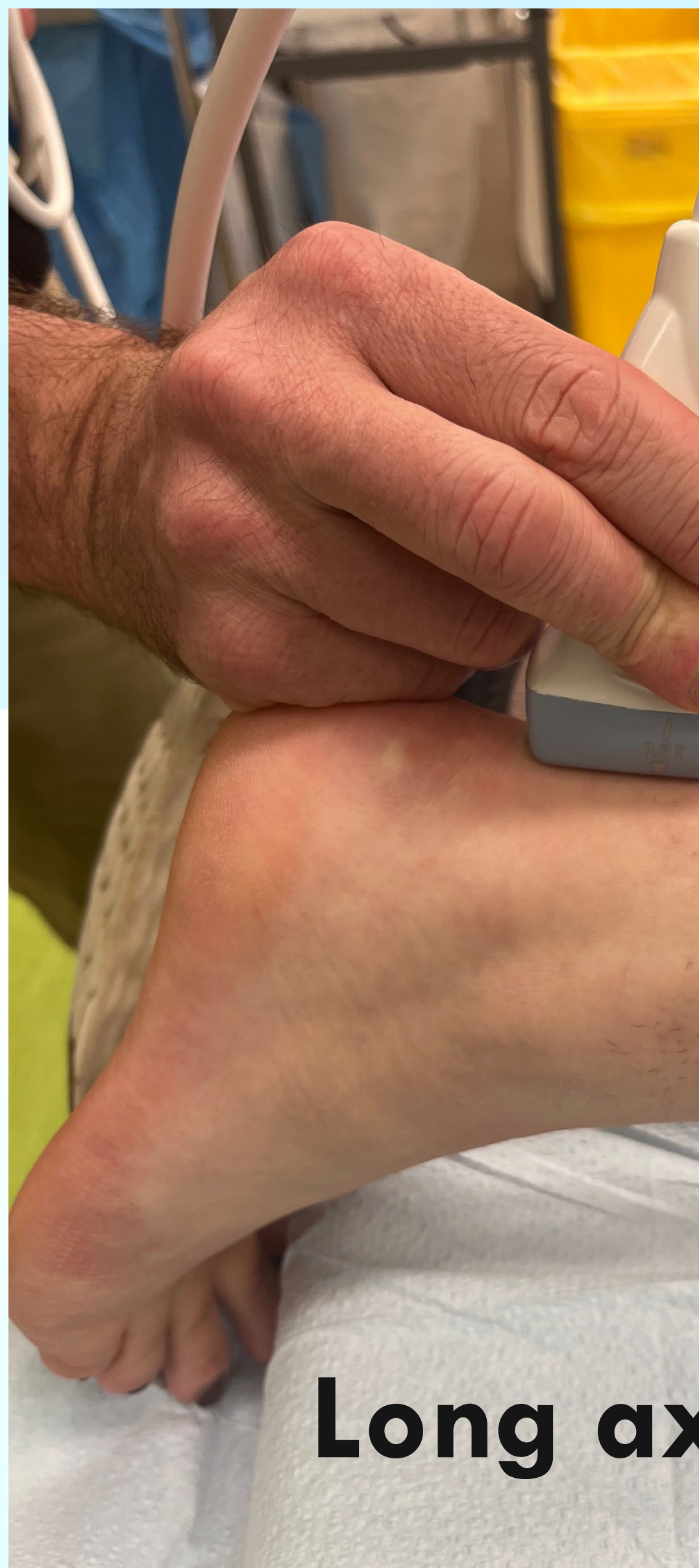Credit:



SONOANATOMY



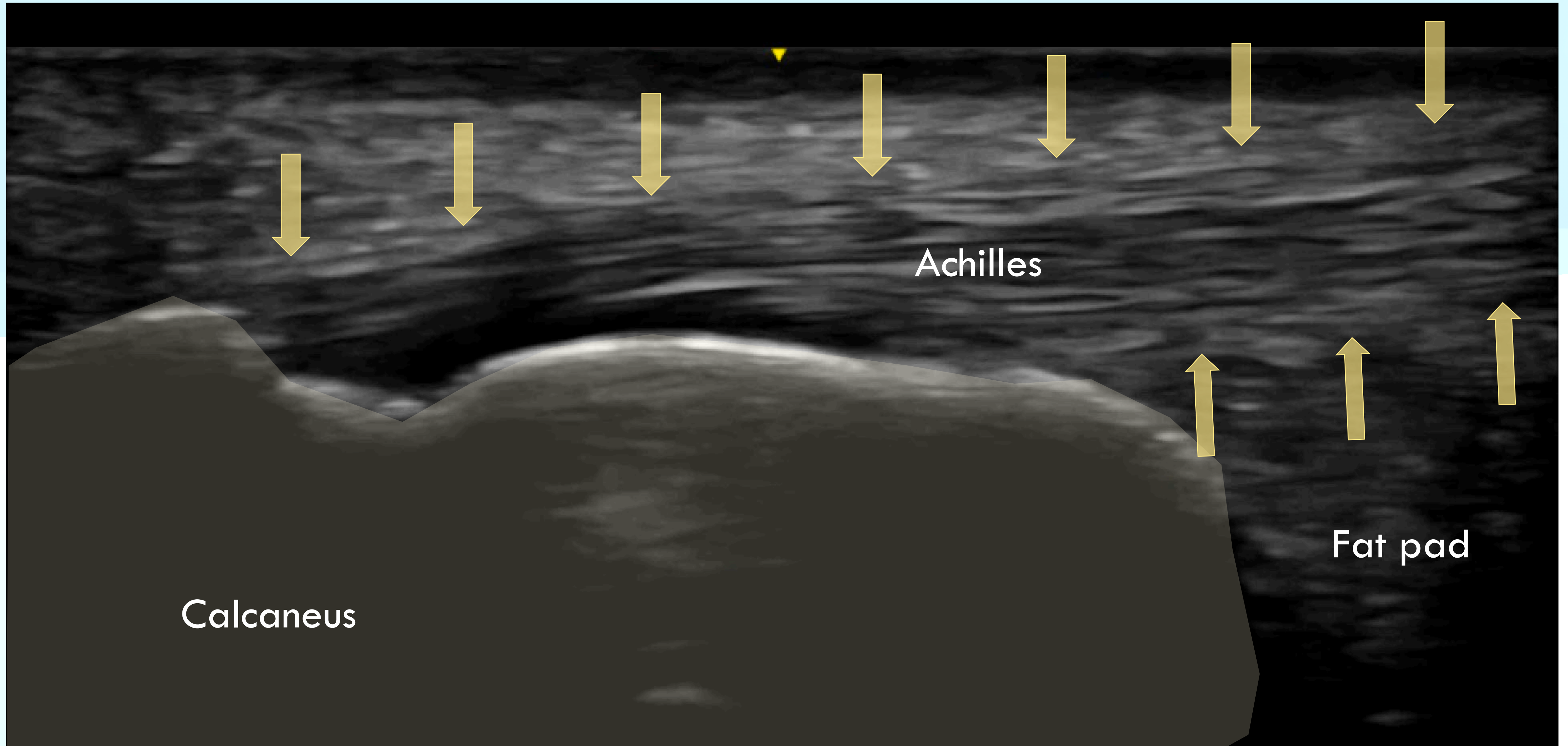
SONOANATOMY



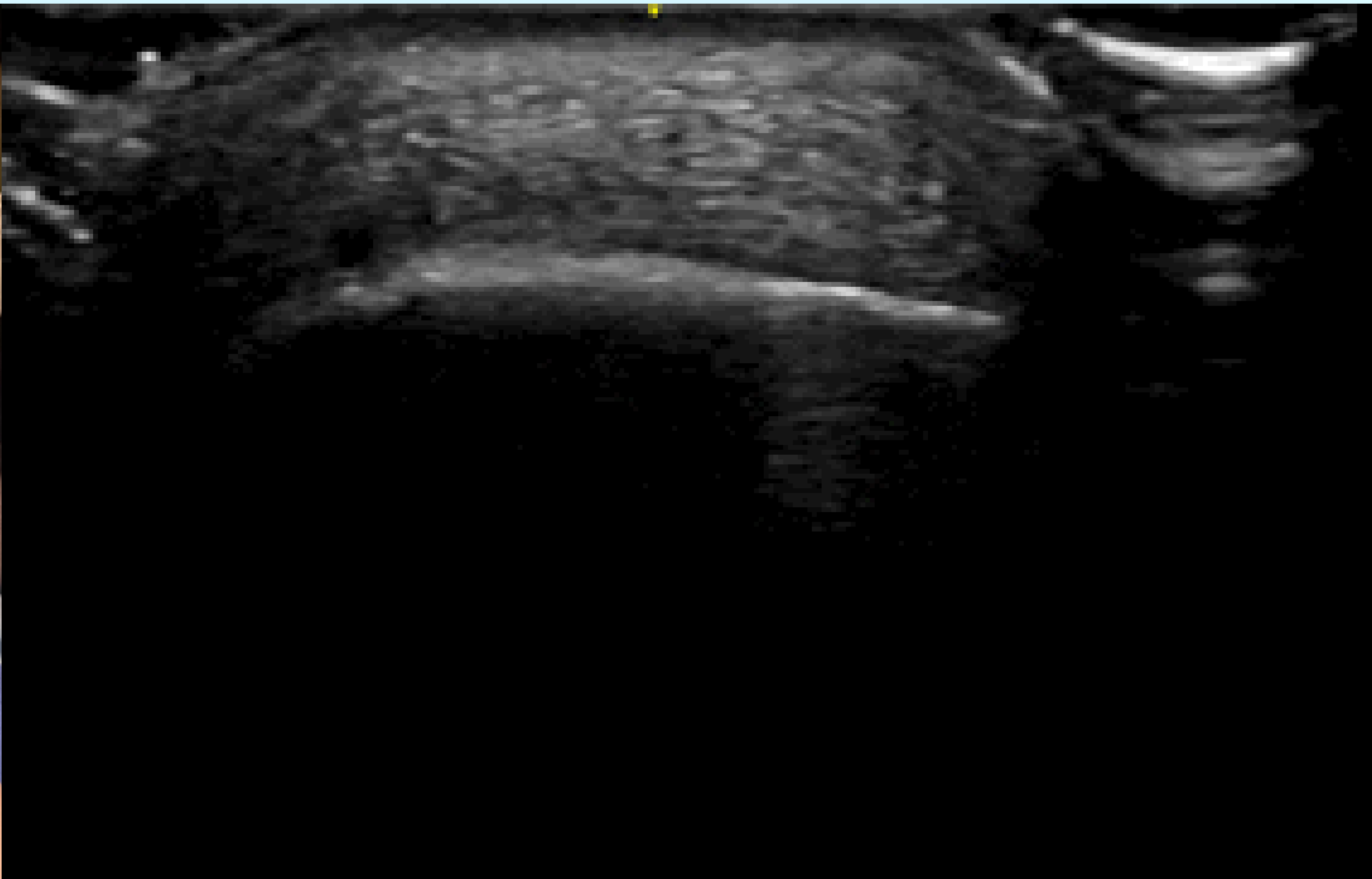
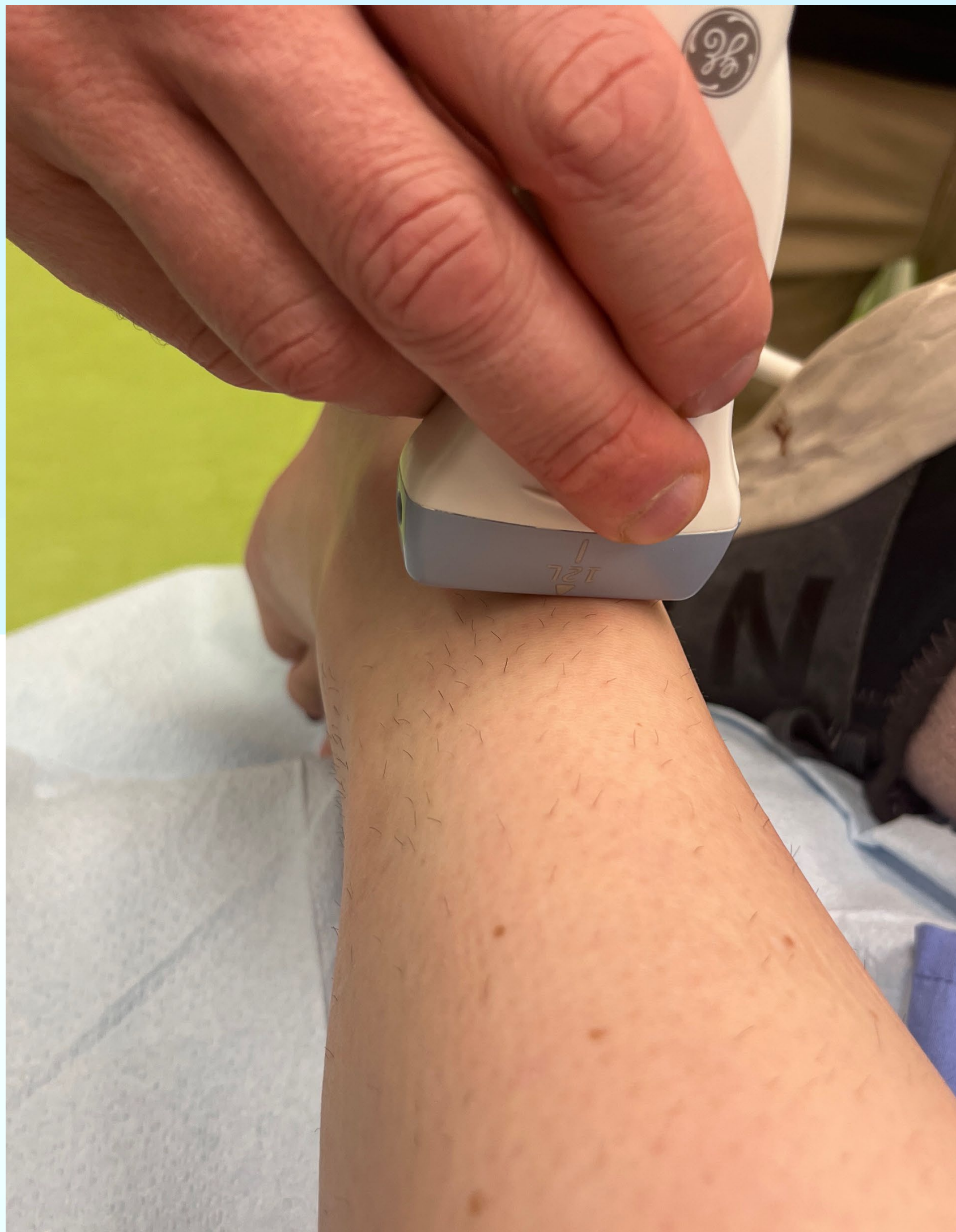Long ax



SONOANATOMY



SONOANATOMY



Short axis

Case #1

40M smoker, soccer night
Running for ball, “snap”
Fall, can’t walk

**Clinical
exam**

+

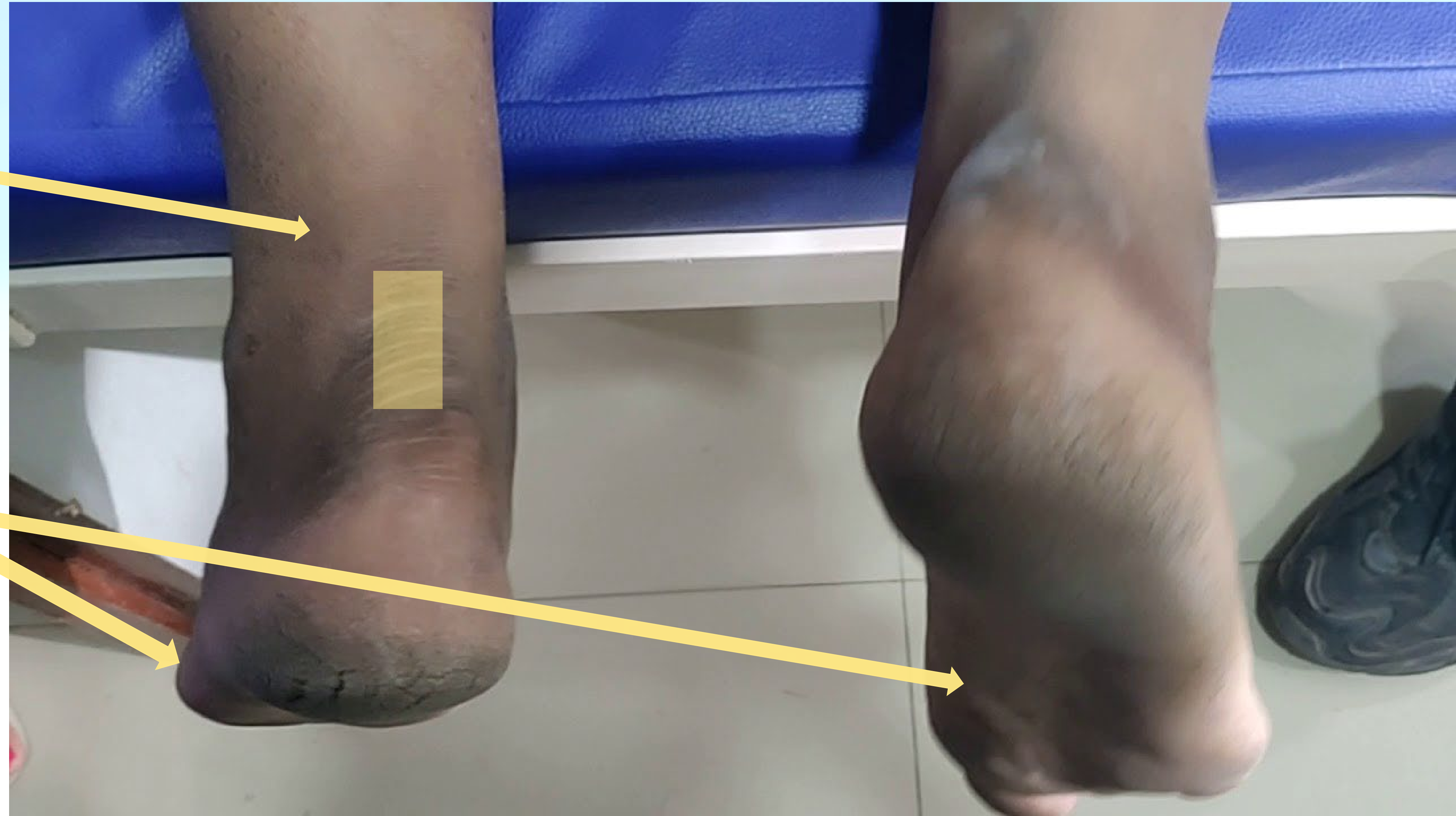
Ultrasound

40M smoker, soccer night
Running for ball, "snap"
Fall, can't walk

Swelling

Palpable "gap"

**Loss of resting
plantar tone**



THOMPSON TEST

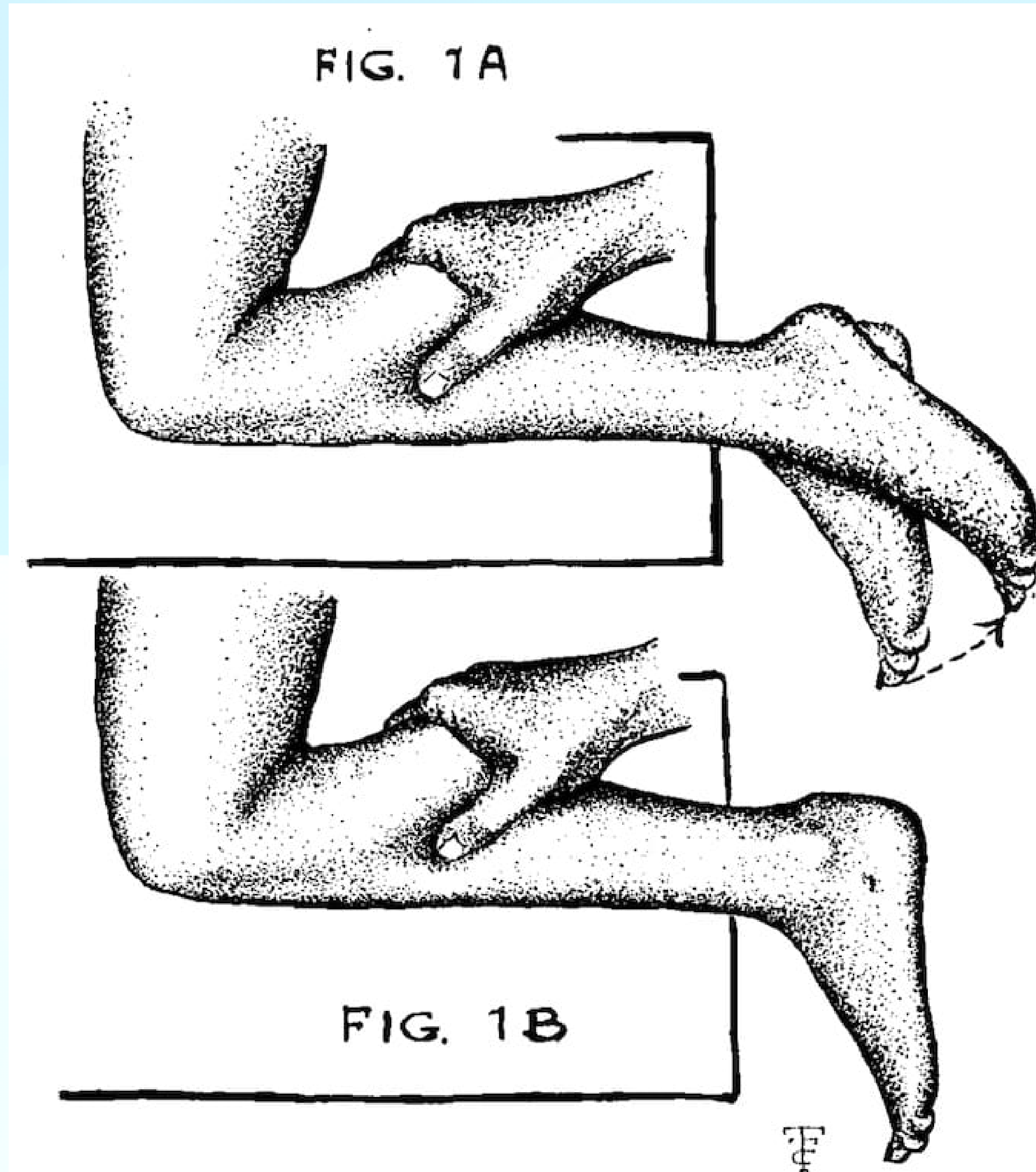


Fig. 1 a.
Squeezing calf produces plantar flexion of foot when heel cord is intact.

Fig. 1 b.
Squeezing calf produces no motion of foot in injured leg.

Achilles RUPTURE

- 30-50y, M>F

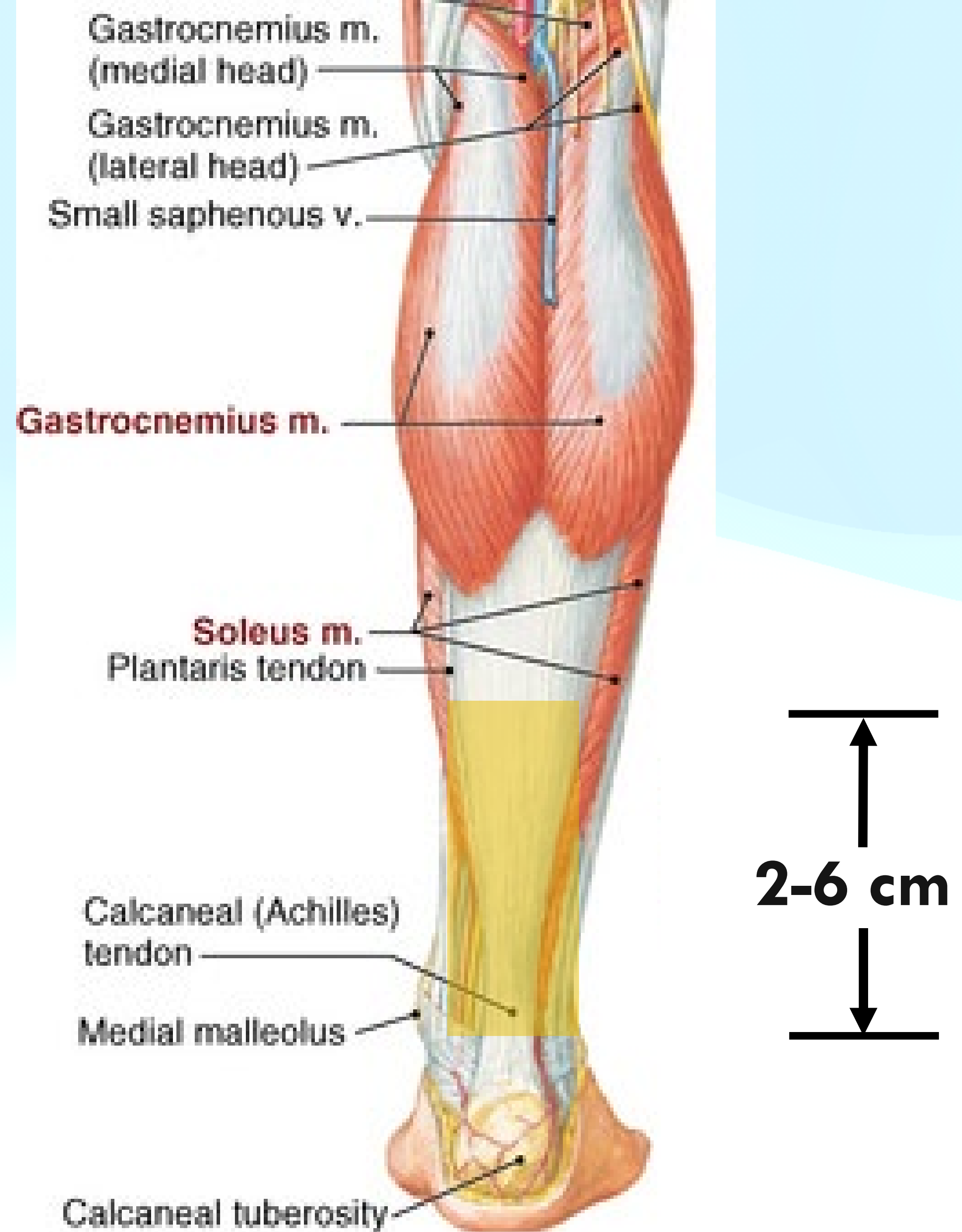
Risks

Smoking

Fluoroquinolone use

Steroid injection

Vascular risk factors

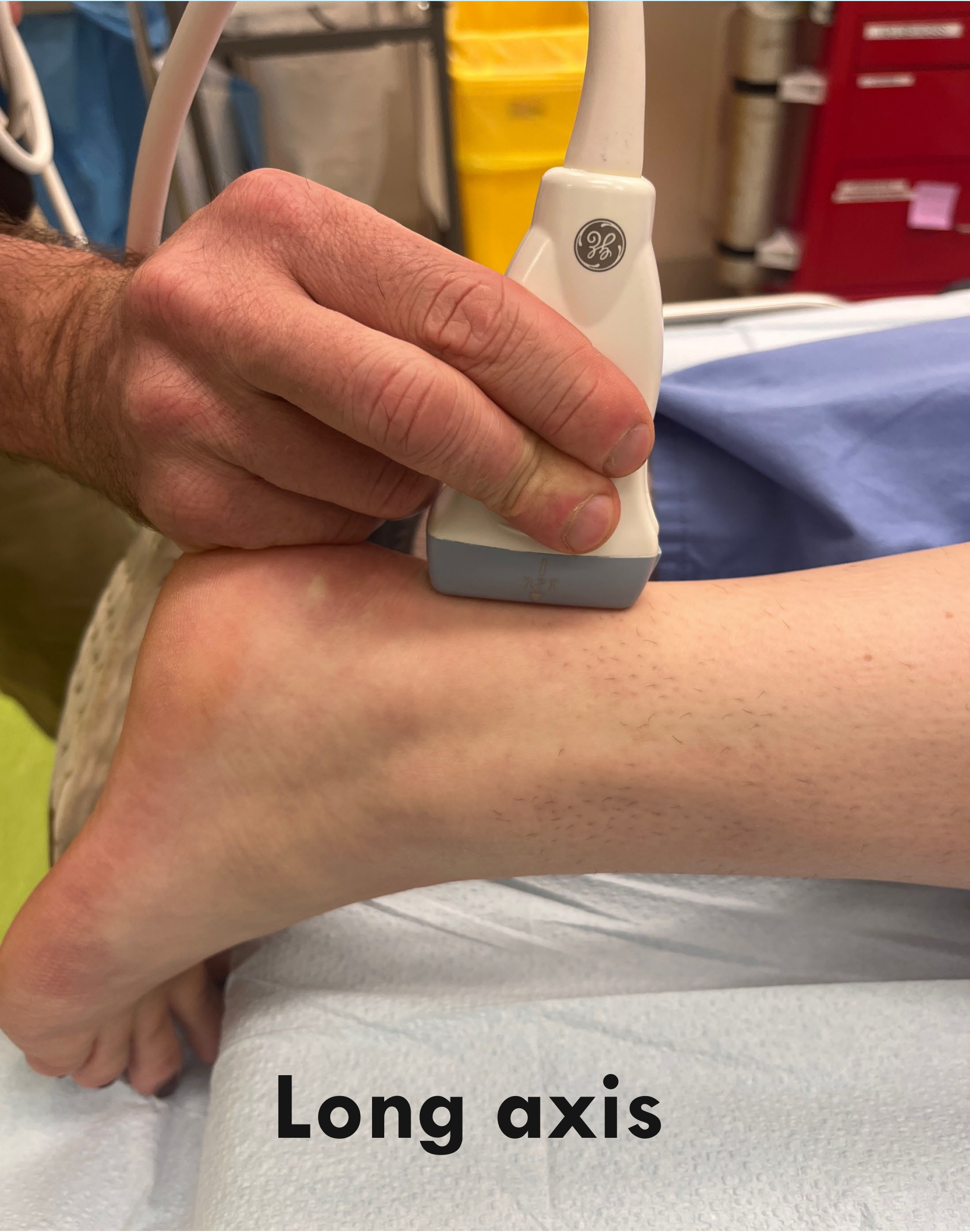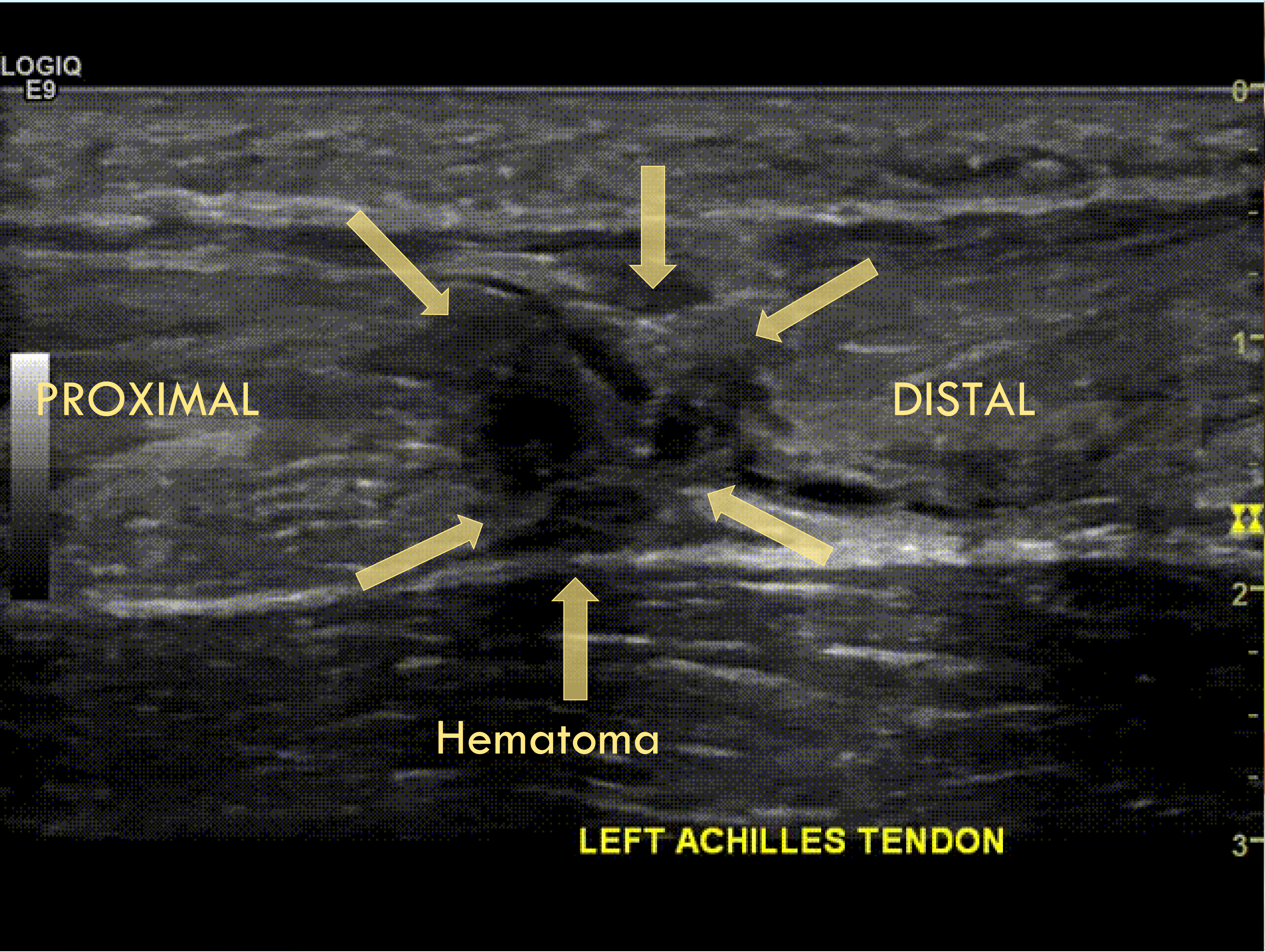




Clinical exam?

20% miss rate

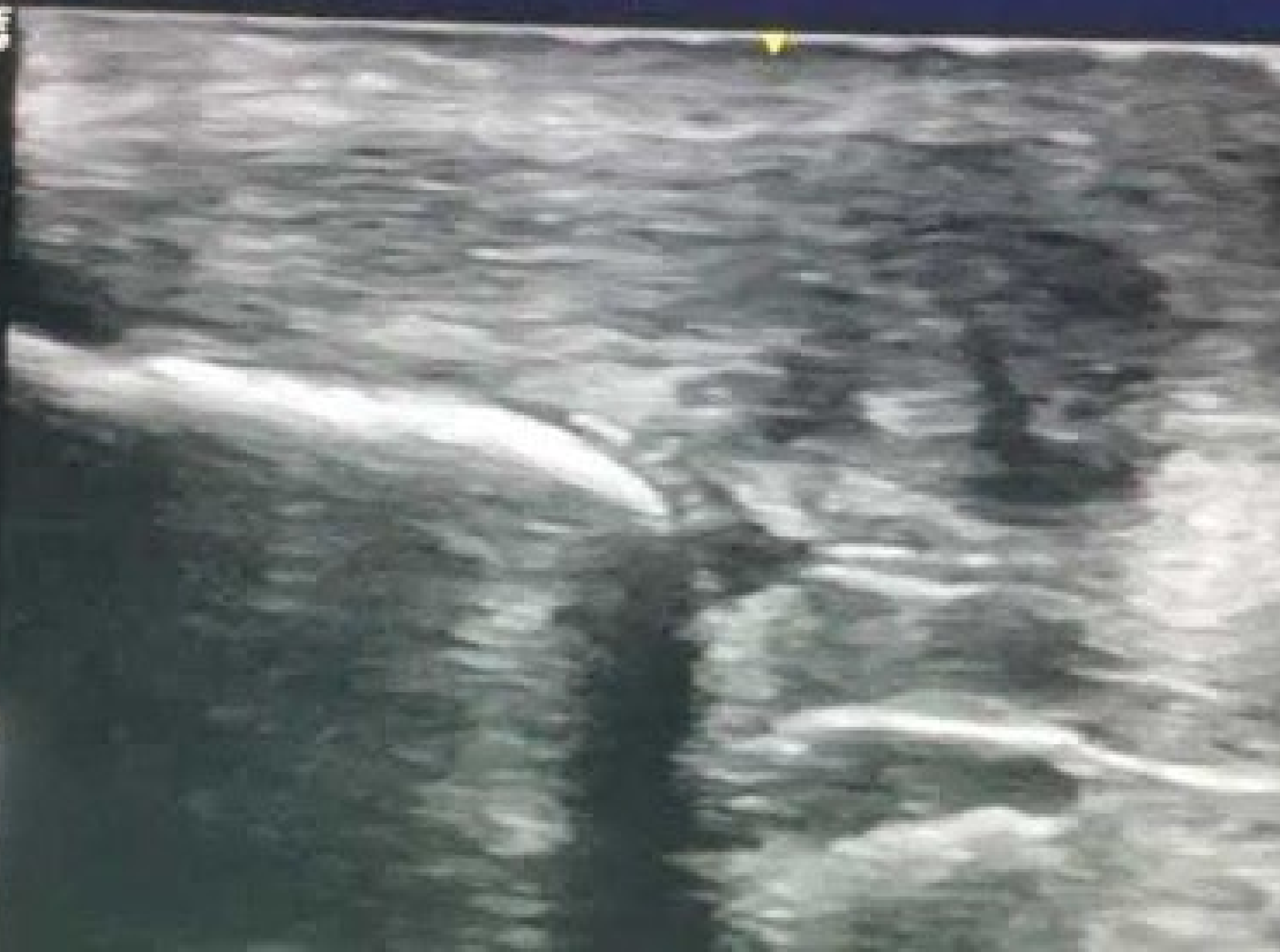Achilles RUPTURE: LONG axis

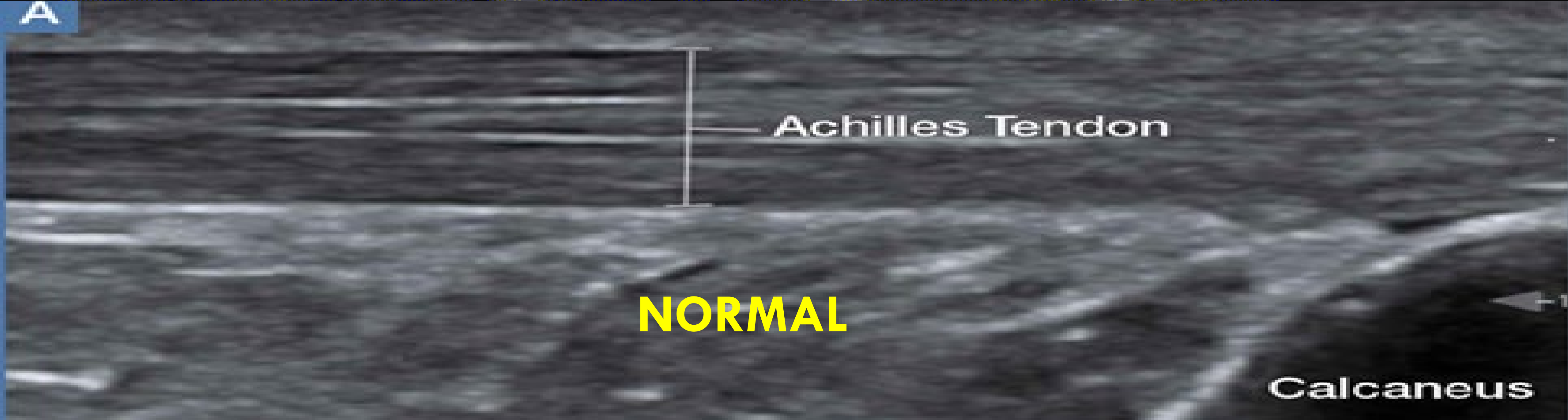
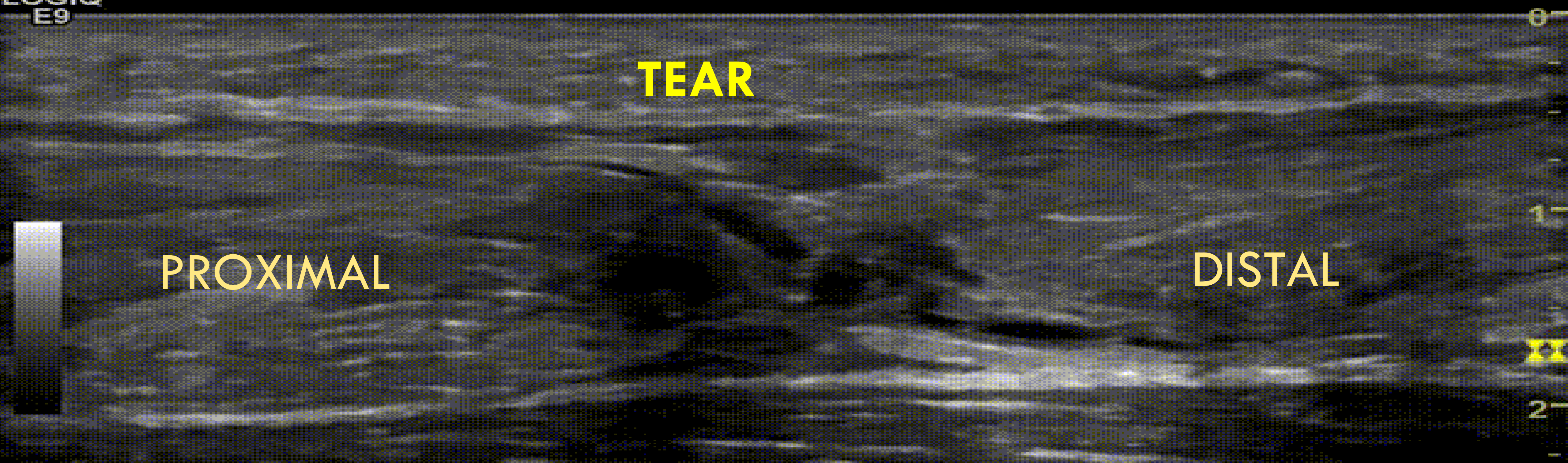




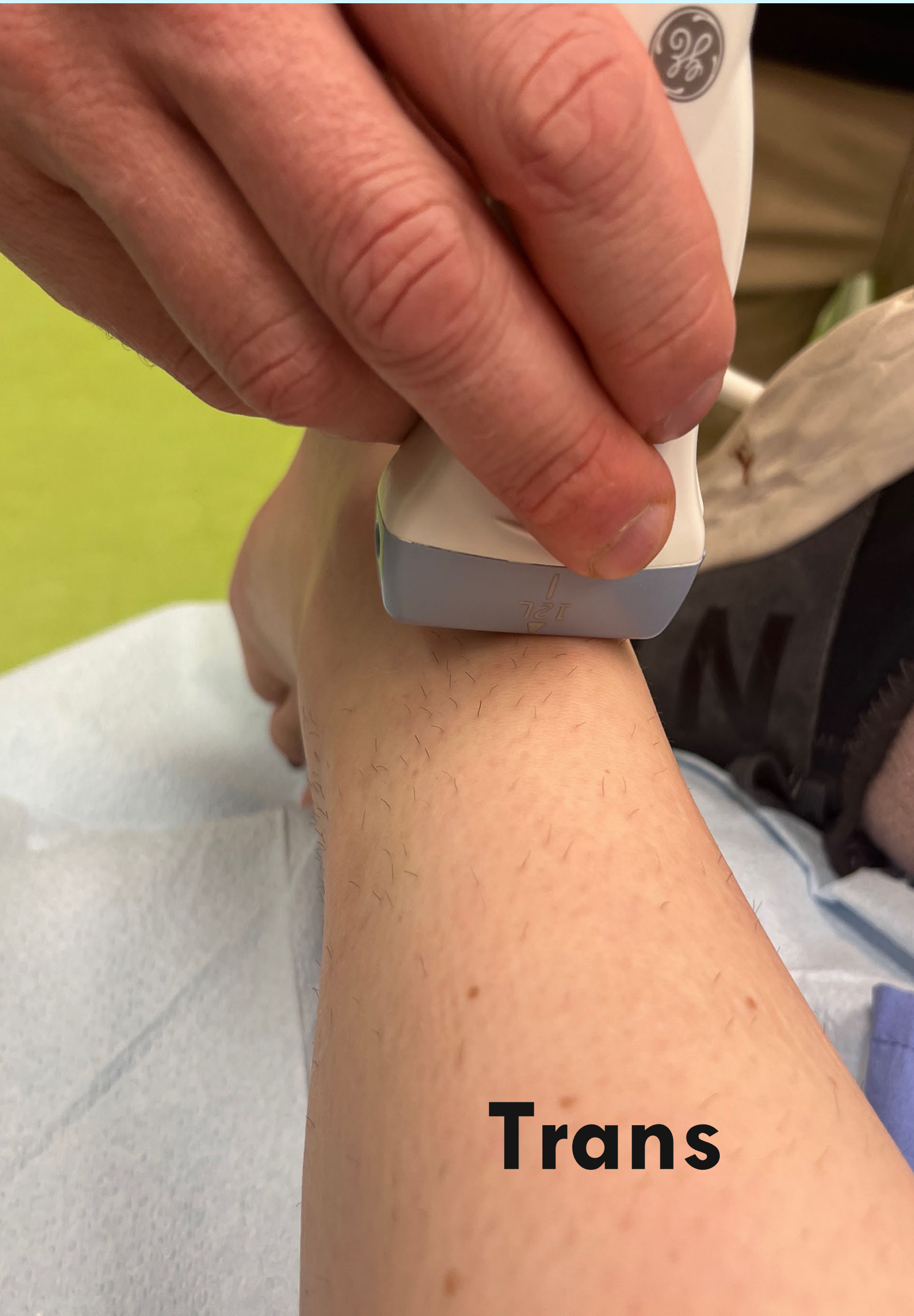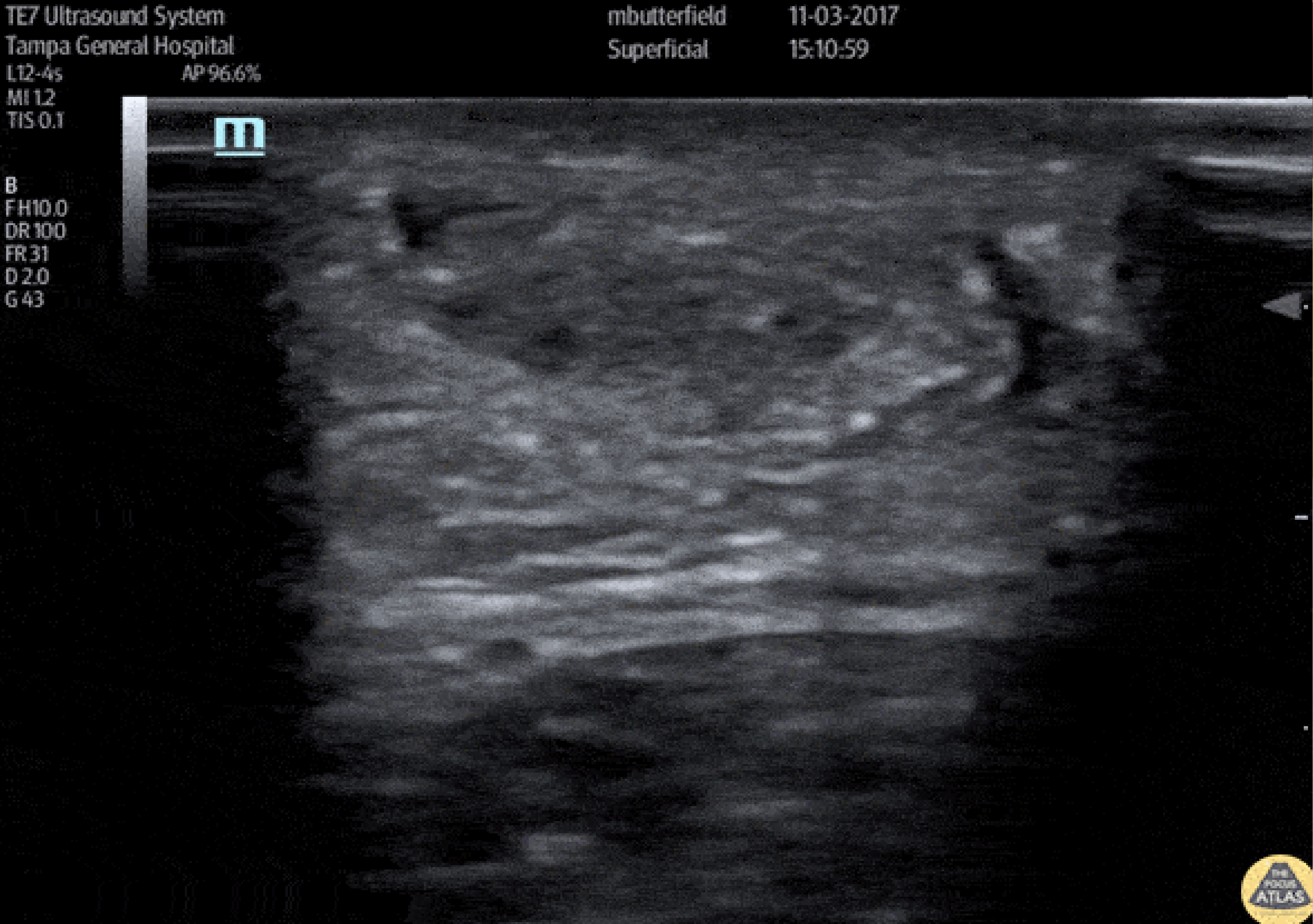
03/10/21 09:09:38AM

GE
LP





Achilles RUPTURE: TRANS axis



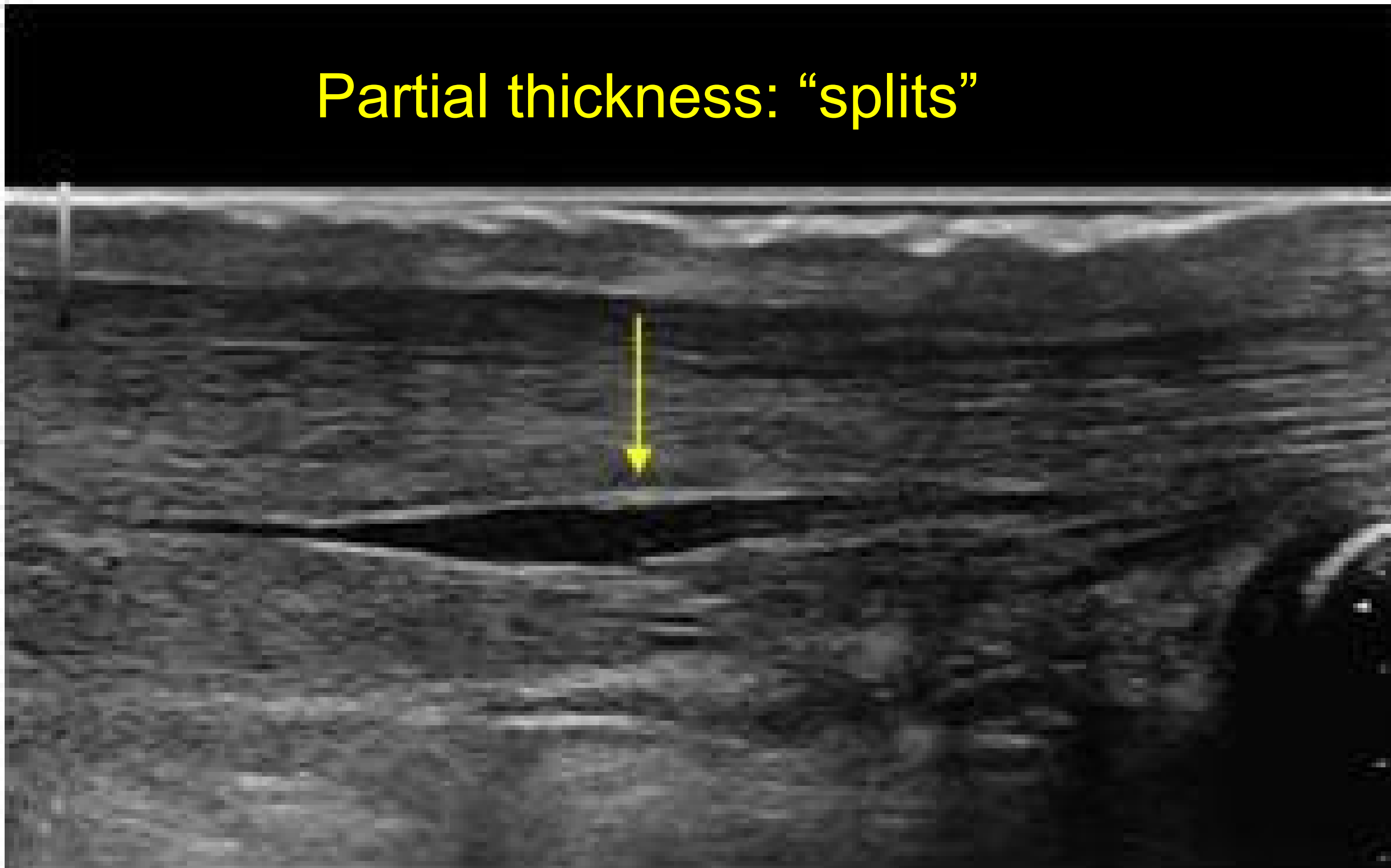
**PROXIMAL
STUMP**

HEMATOMA

LONG

FULL VS PARTIAL THICKNESS

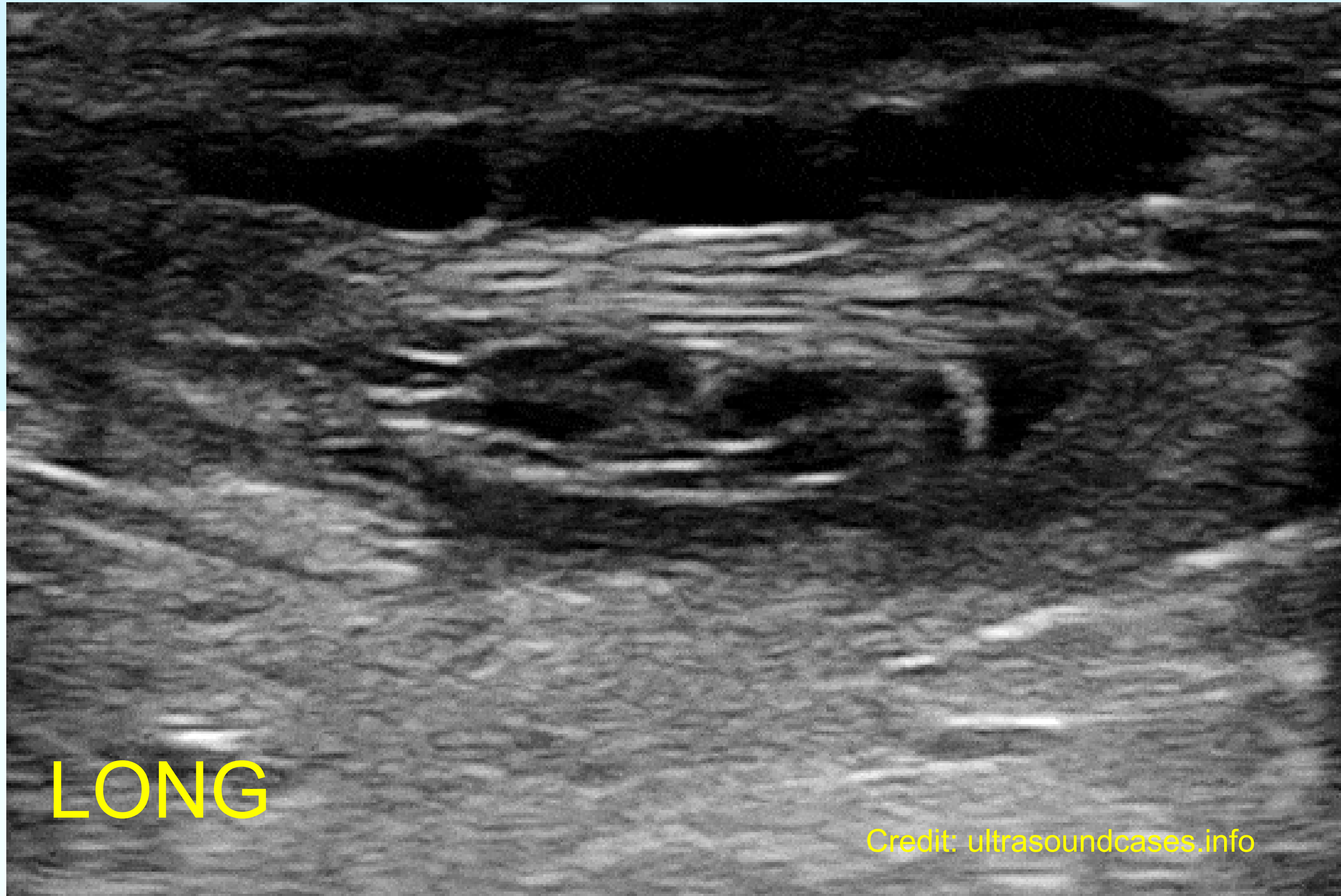
Partial thickness: “splits”



Partial thickness tears
co-exists with tendinopathy

Clinically indistinguishable
with tendinopathy

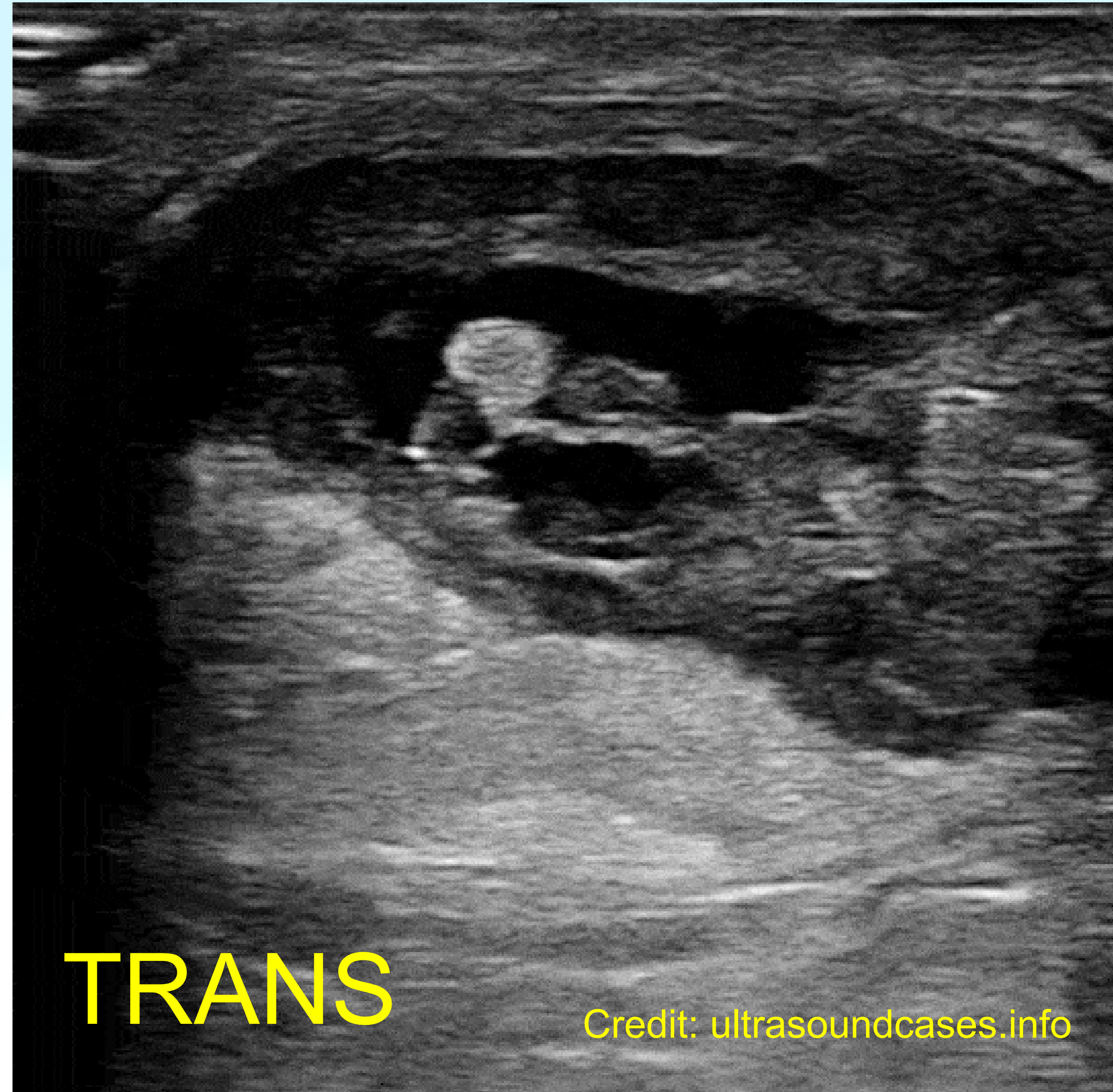
PARTIAL TEARS



LONG

Credit: ultrasoundcases.info

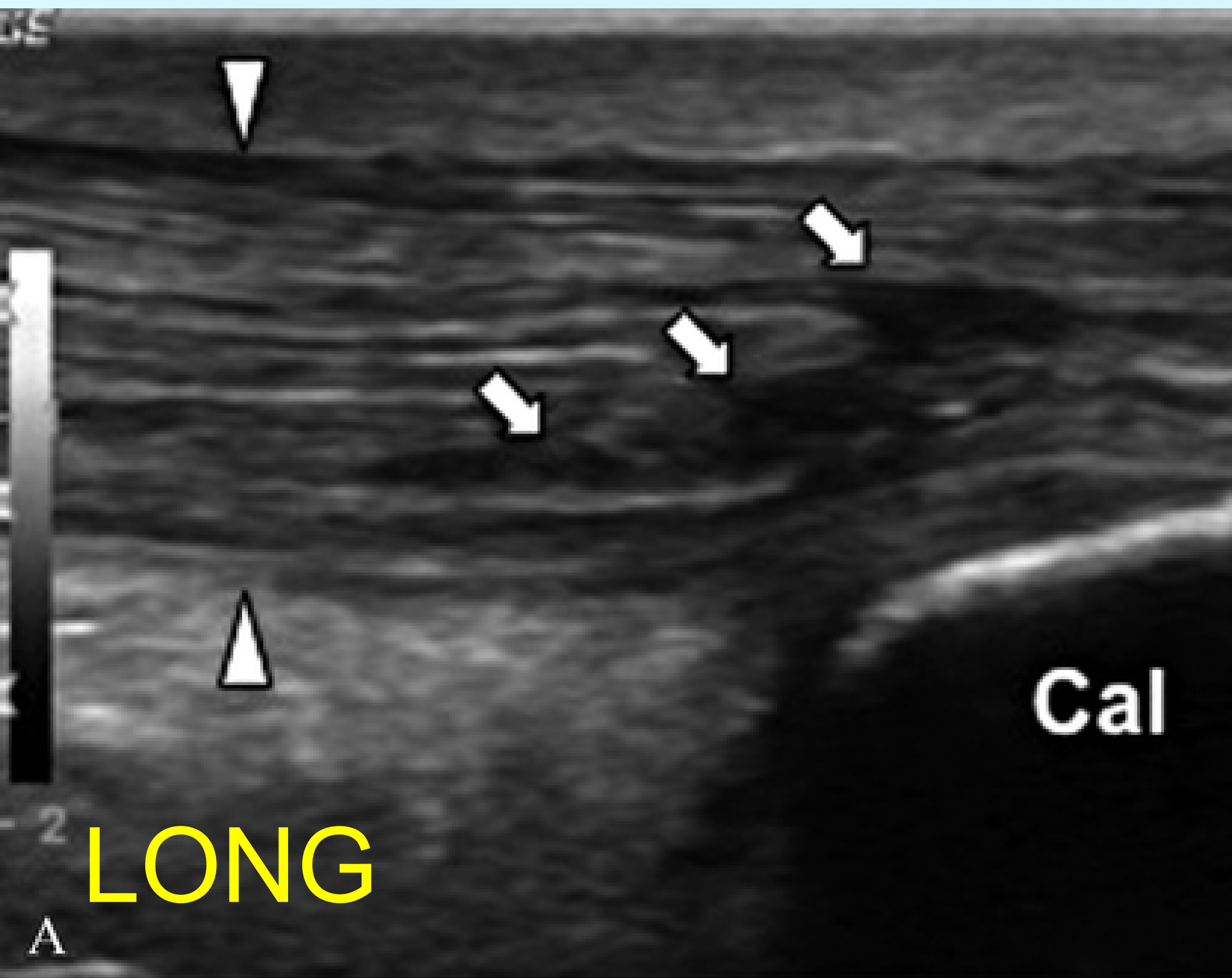
PARTIAL TEARS



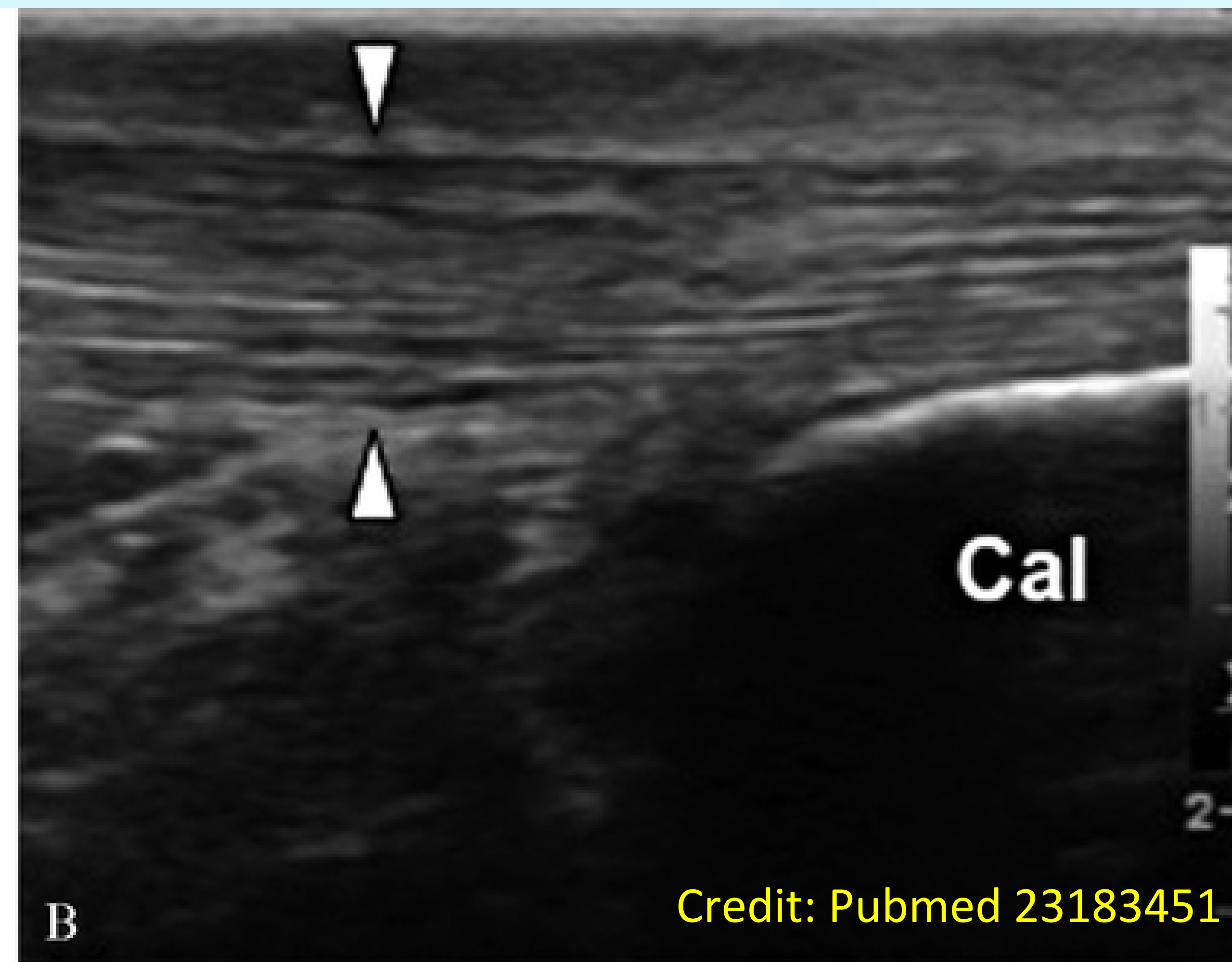
TRANS

Credit: ultrasoundcases.info

PARTIAL TEARS



Affected



Normal

Credit: Pubmed 23183451

TENDINOPATHY IS...

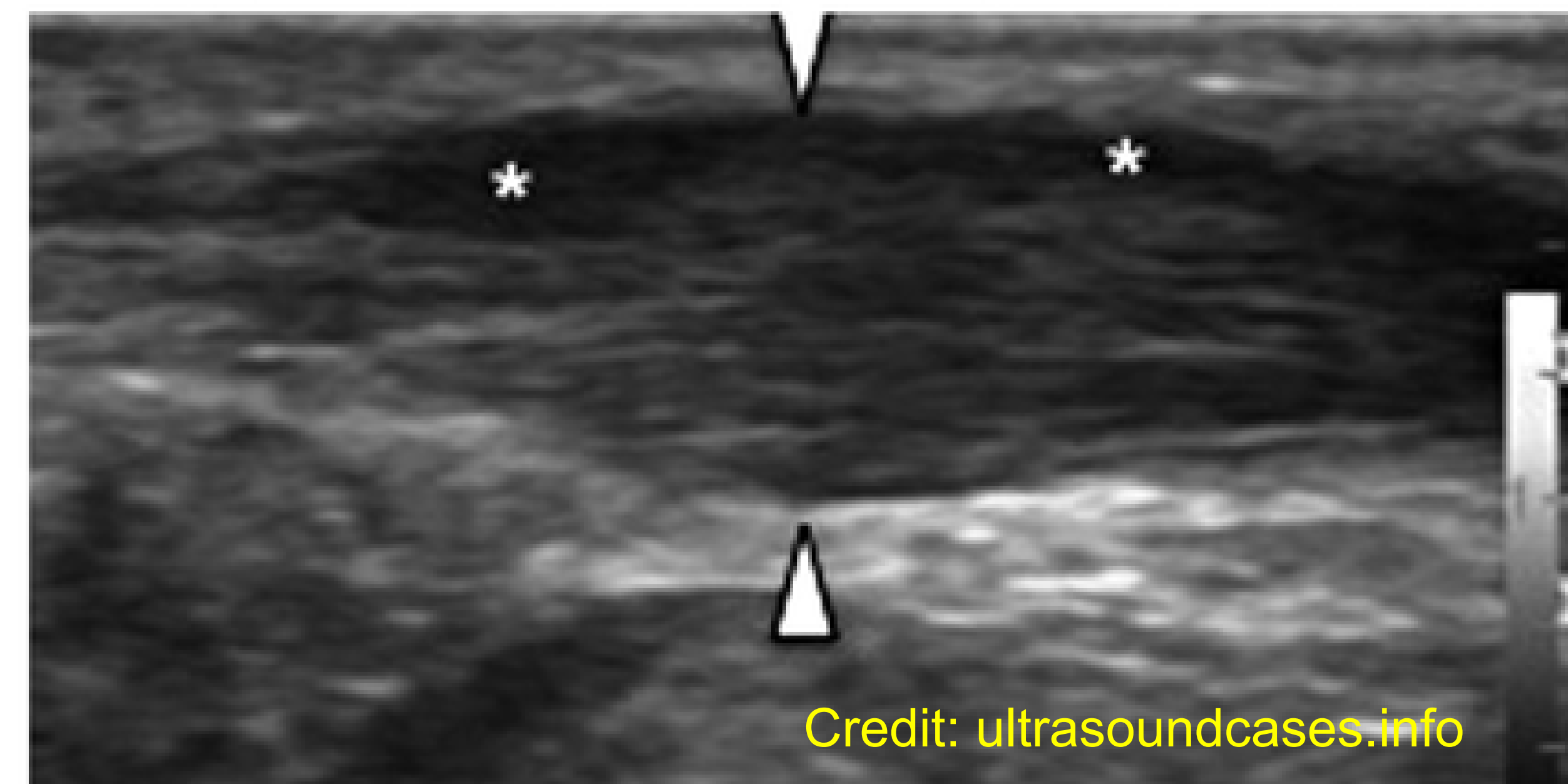
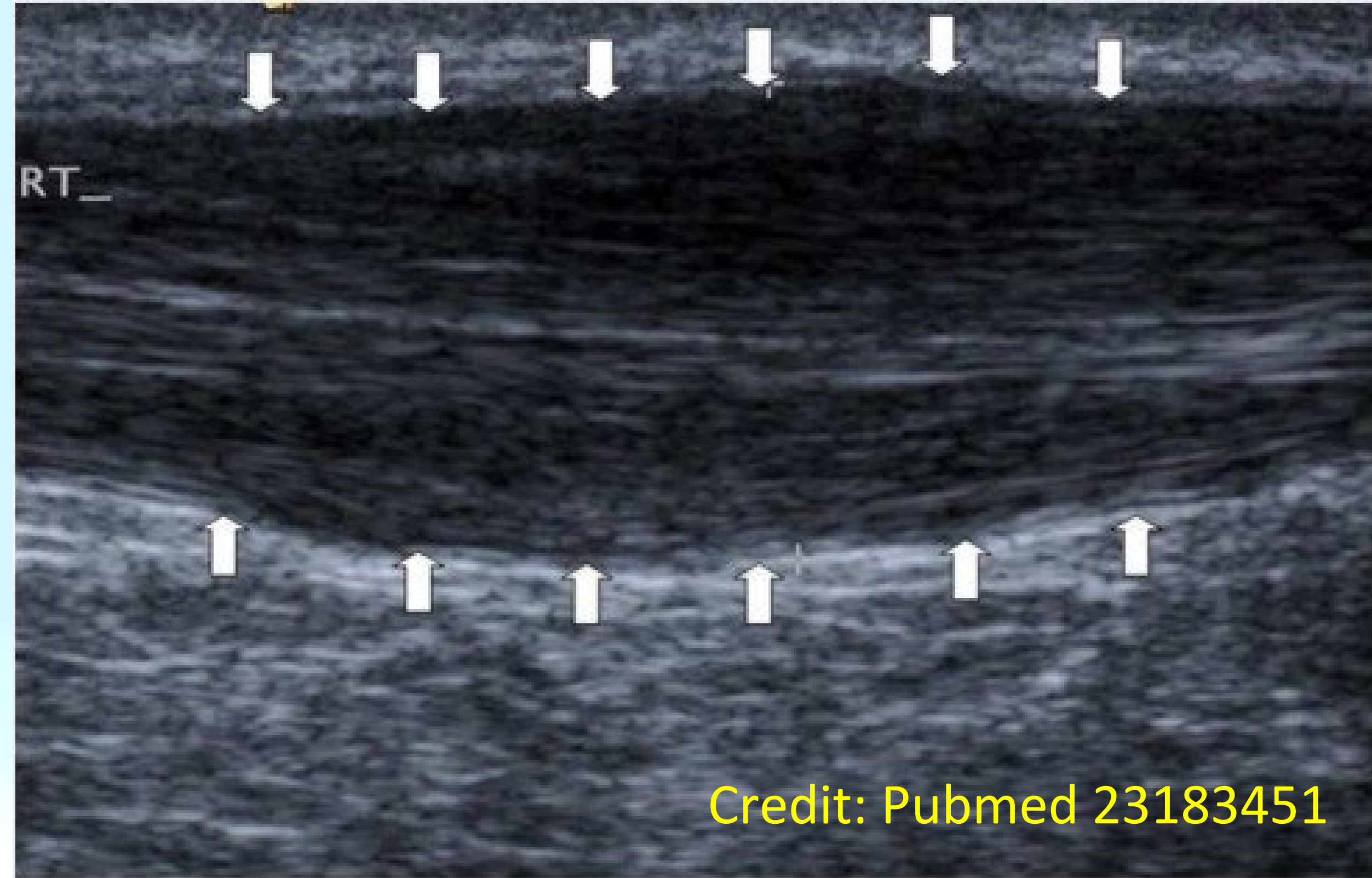
“A failed healing response,
haphazard proliferation of tenocytes,
disruption of collagen fibres,
increase in non-collagenous matrix”

TENDINOPATHY

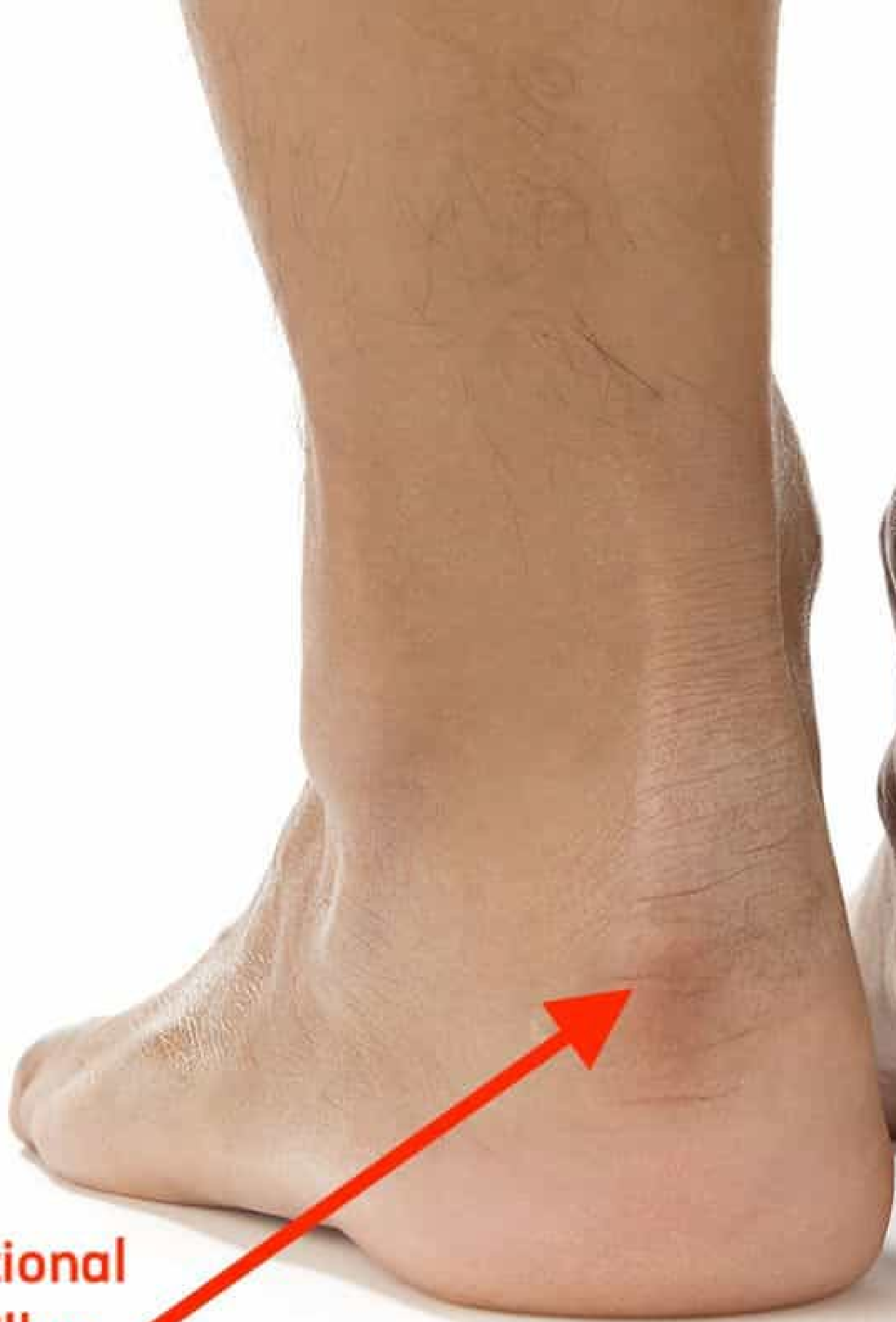Thickening

Fibre separation + disruption

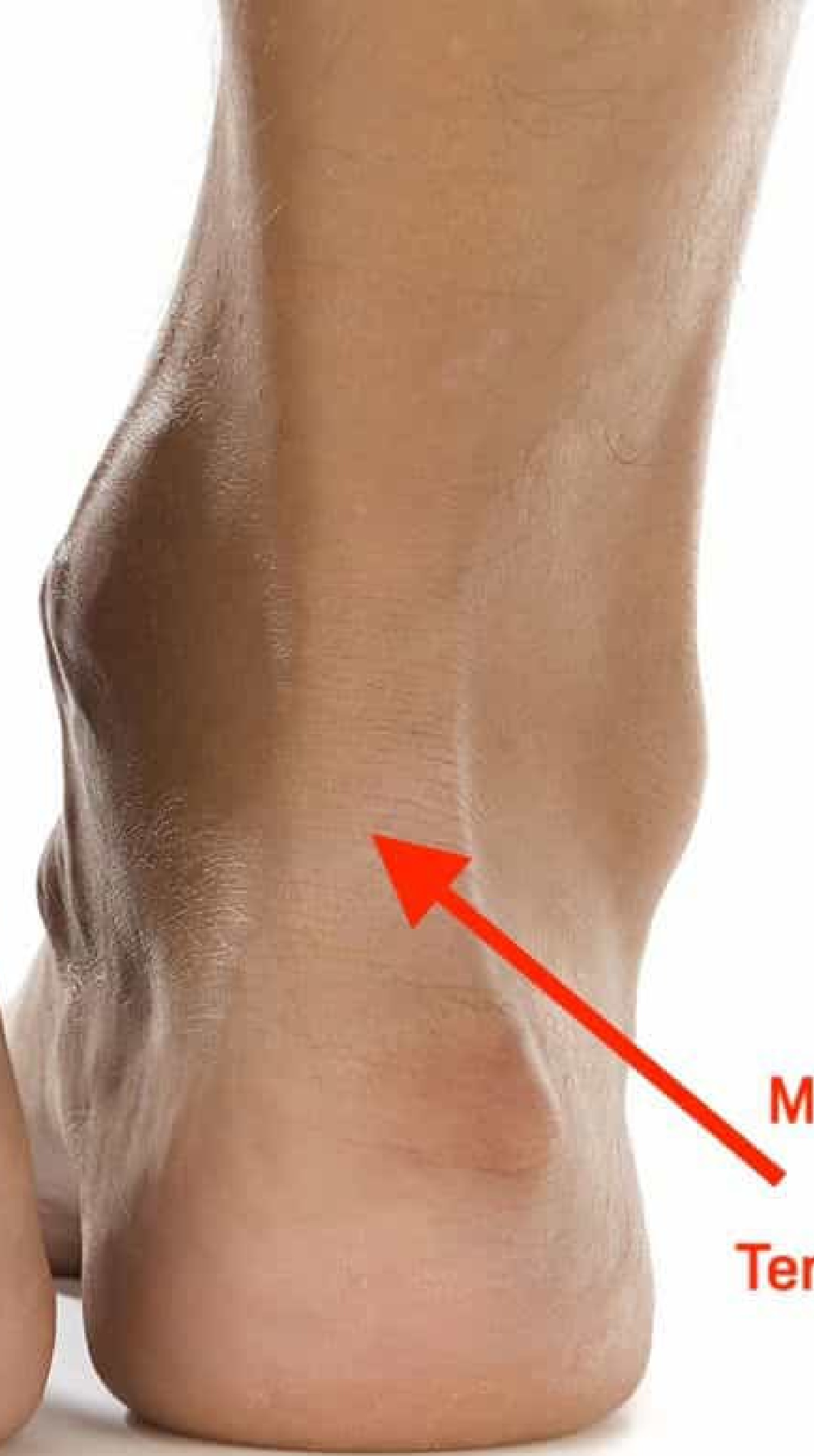Irregular fibre appearance



**Insertional
Achilles
Tendinopathy**

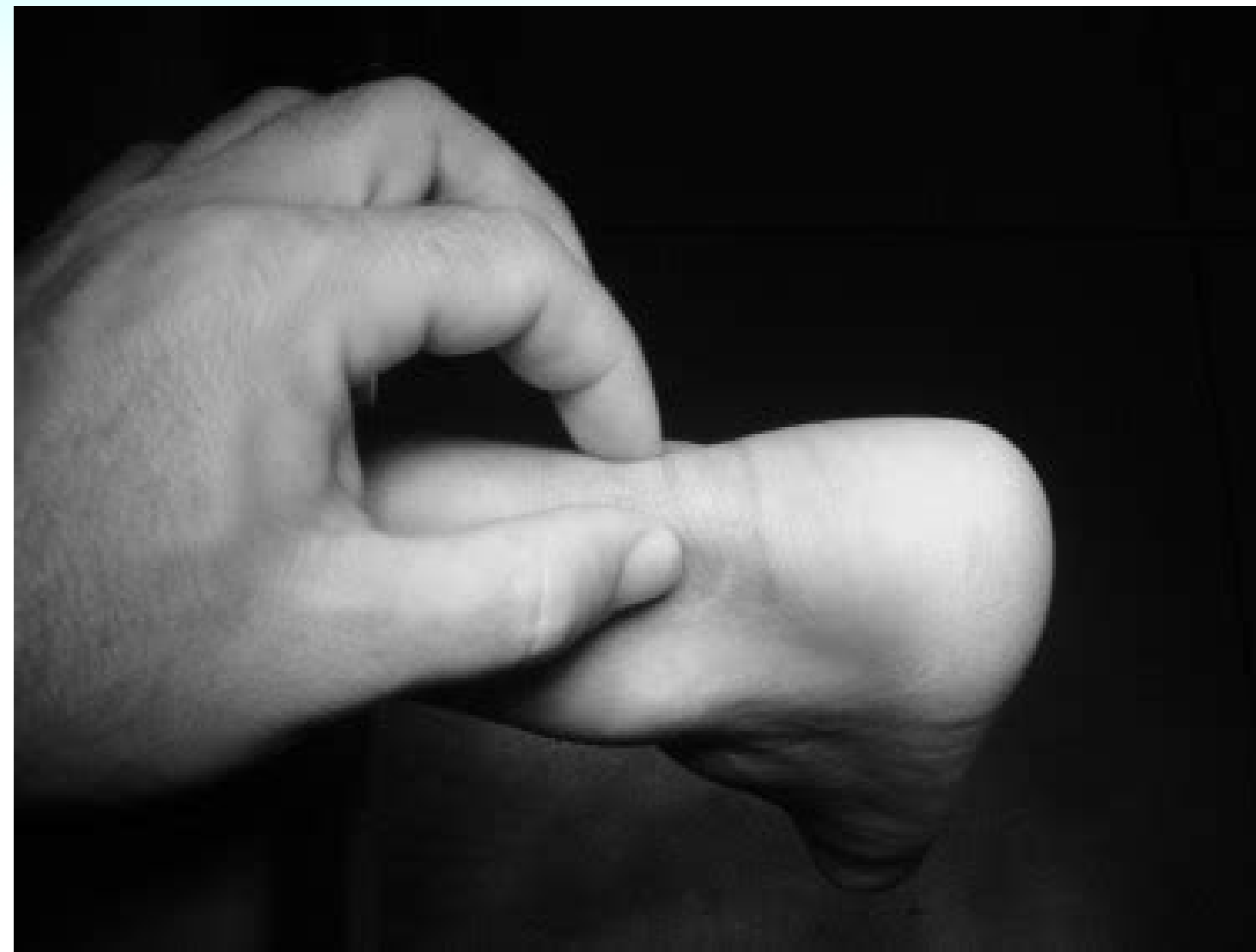

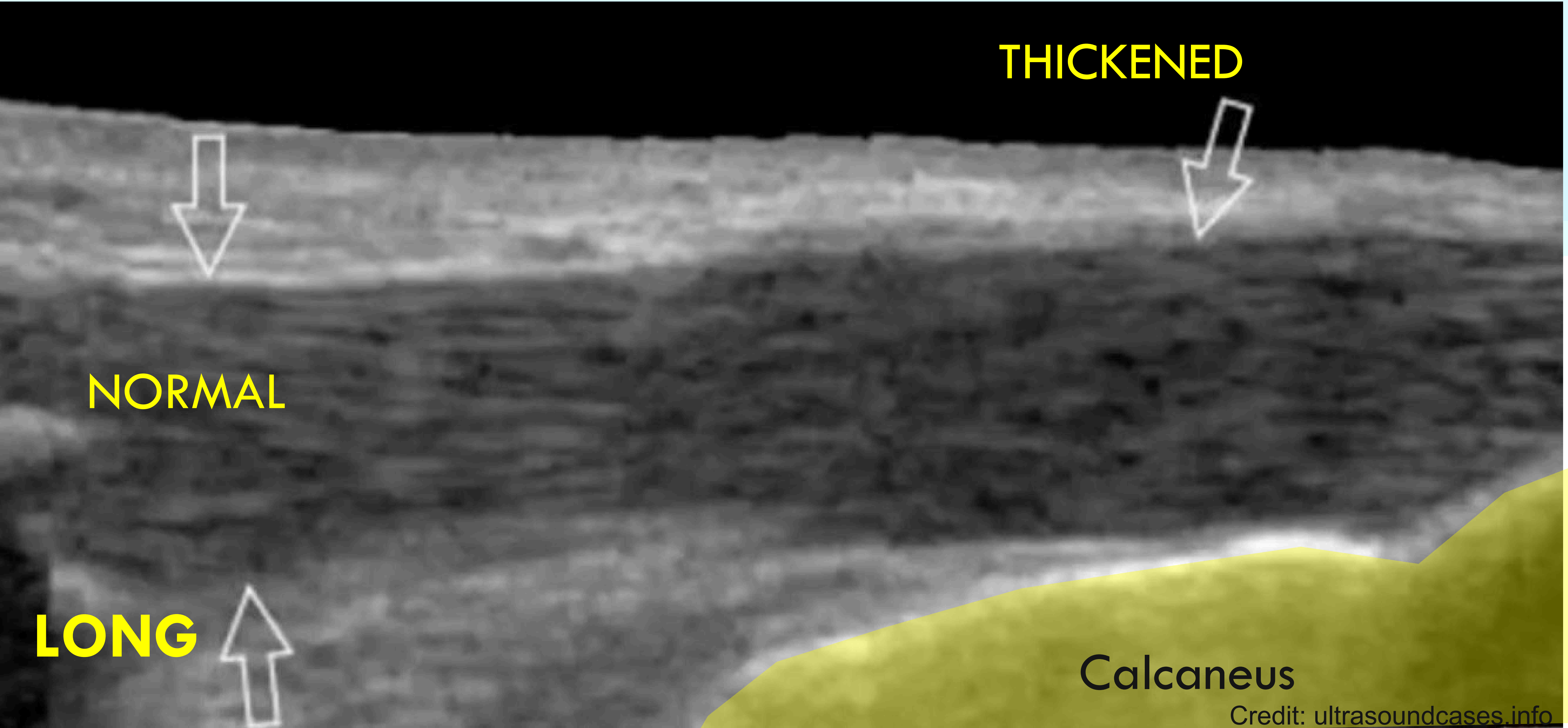
**Mid-portion
Achilles
Tendinopathy**



Case #2

22M, competing @ basketball tournament
Increasing Achilles pain
Tender midtendon





THICKENED

NORMAL

LONG

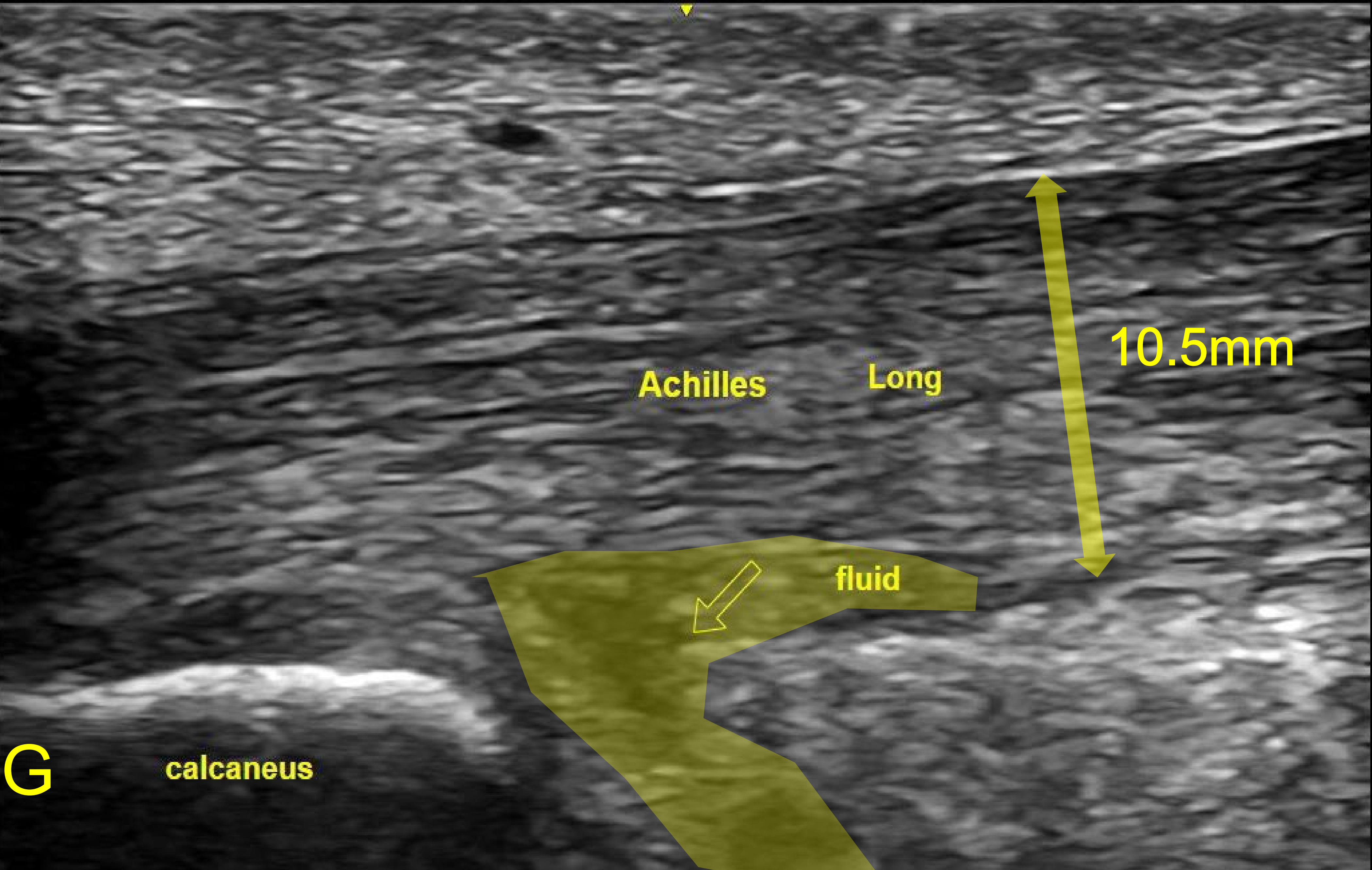
Calcaneus

Case #3

**48M, acute on chronic Achilles pain
8-9 years of variable pain
Tender at insertion**

GE
Venue

3.0
m



LONG

calcaneus

Achilles

Long

10.5mm

fluid



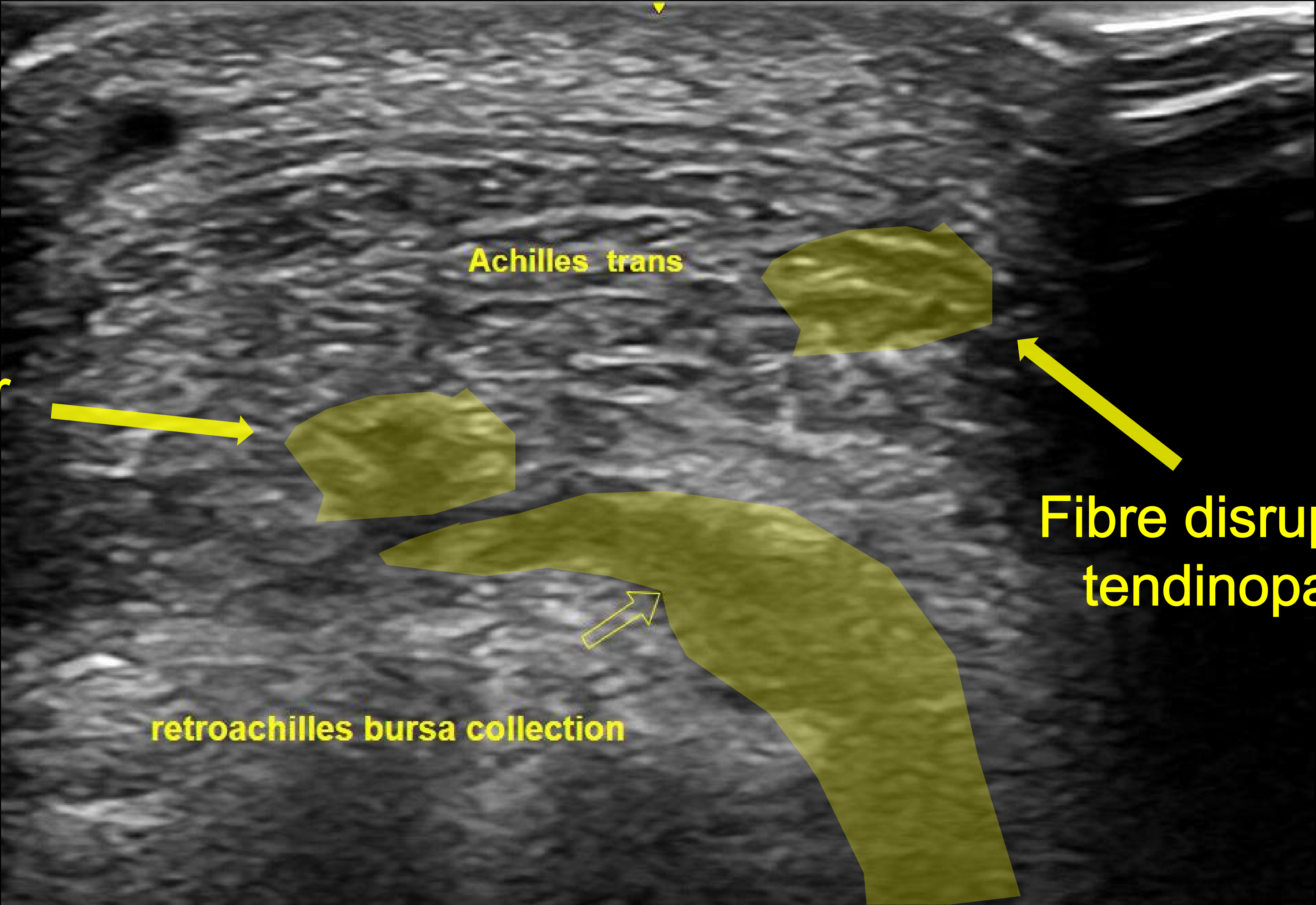
Morton, Tracy
10191971

Haida Gwaii Hospital
13/08/2021 14:39:57

POCUS None

GE
Venue

FPS 35
f9.0/18.0
D 2.0 cm



Partial tear

Achilles trans

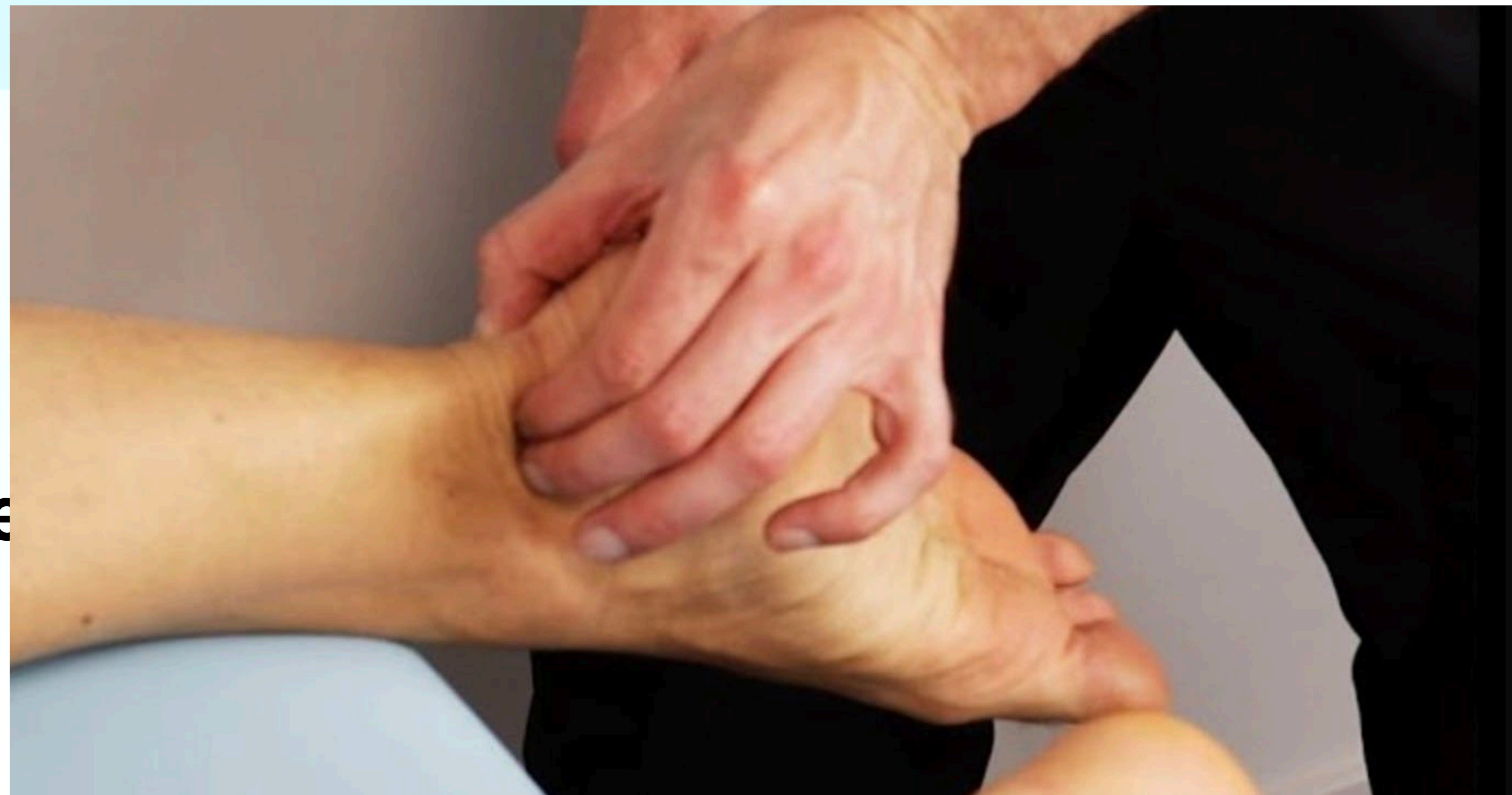**Fibre disruption
tendinopathy**

retroachilles bursa collection

TRANS

Case #4

**45F, presents on crutches, slip last night
Acute Achilles pain + swelling**



Rhe

xate

Right Tendon long

1 d1 1.03 cm



LONG

FPS 49
f5.5/11.0
P 0 dB
G(t) 0 dB
D 2.0 cm

Right Tendon long

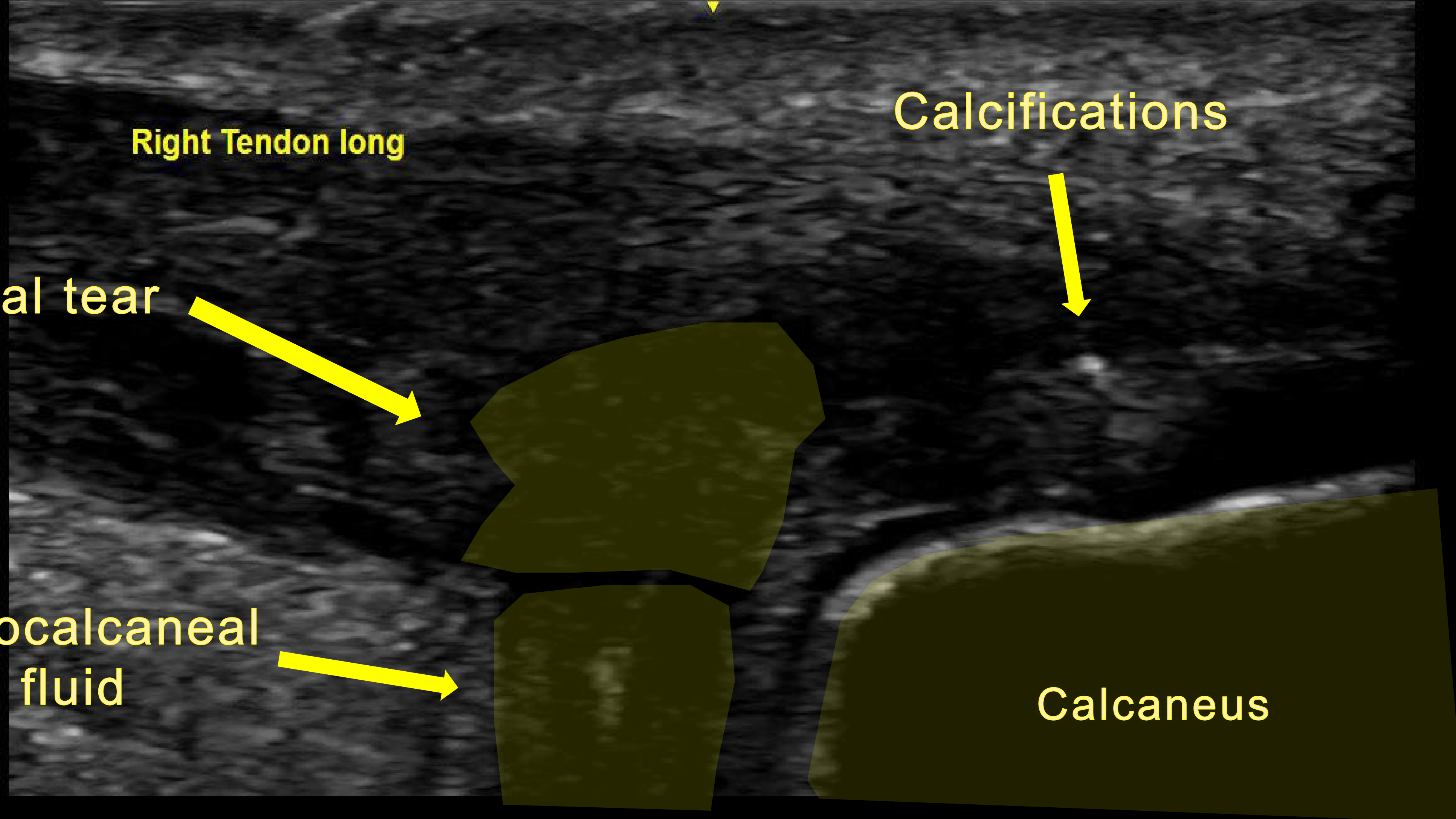
Calcifications

Partial tear

Retrocalcaneal
fluid


Calcaneus

LONG




0.5
1.0
1.5
2.0

TRANS

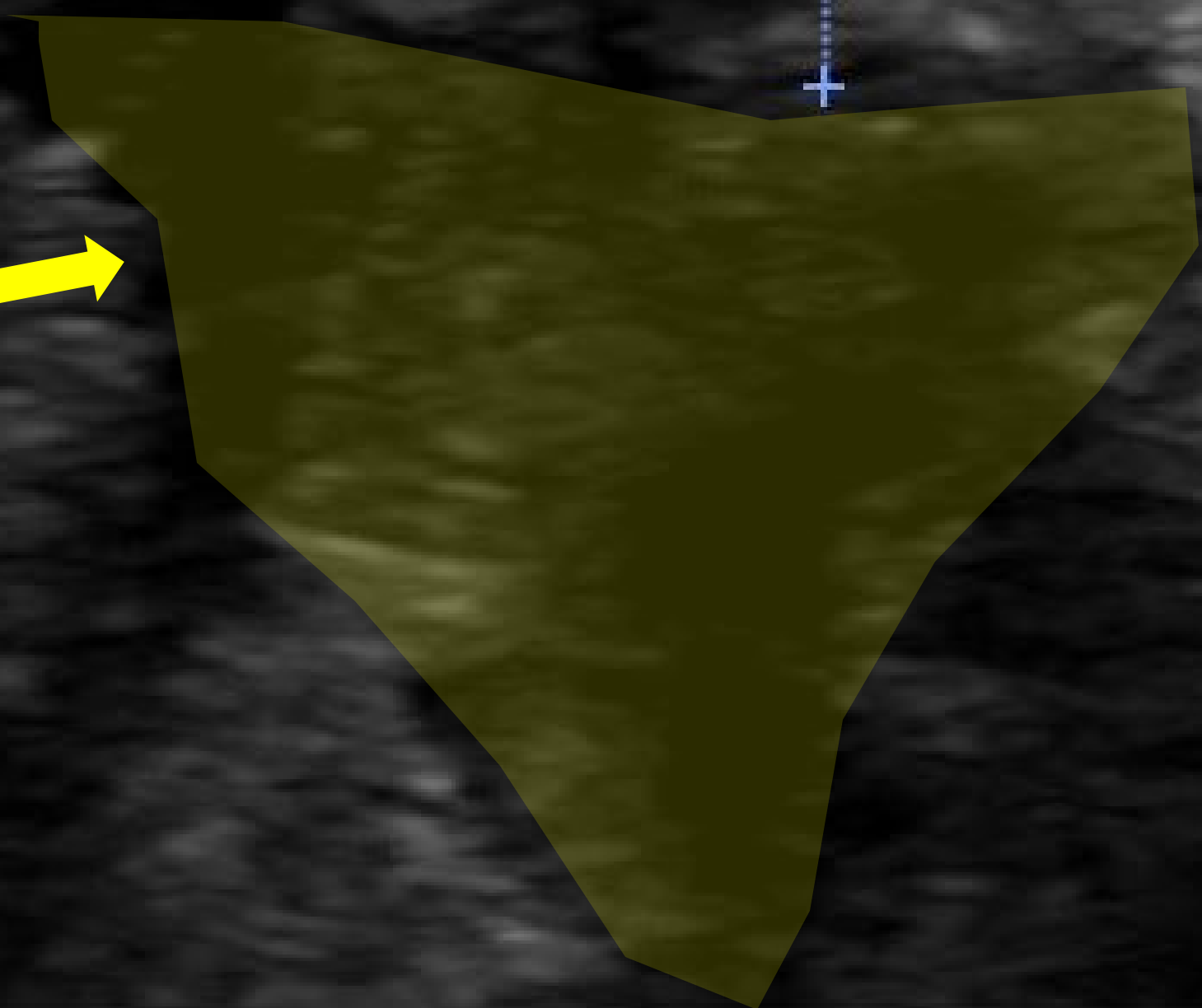


1	d1	1.29 cm
2	d1	1.96 cm

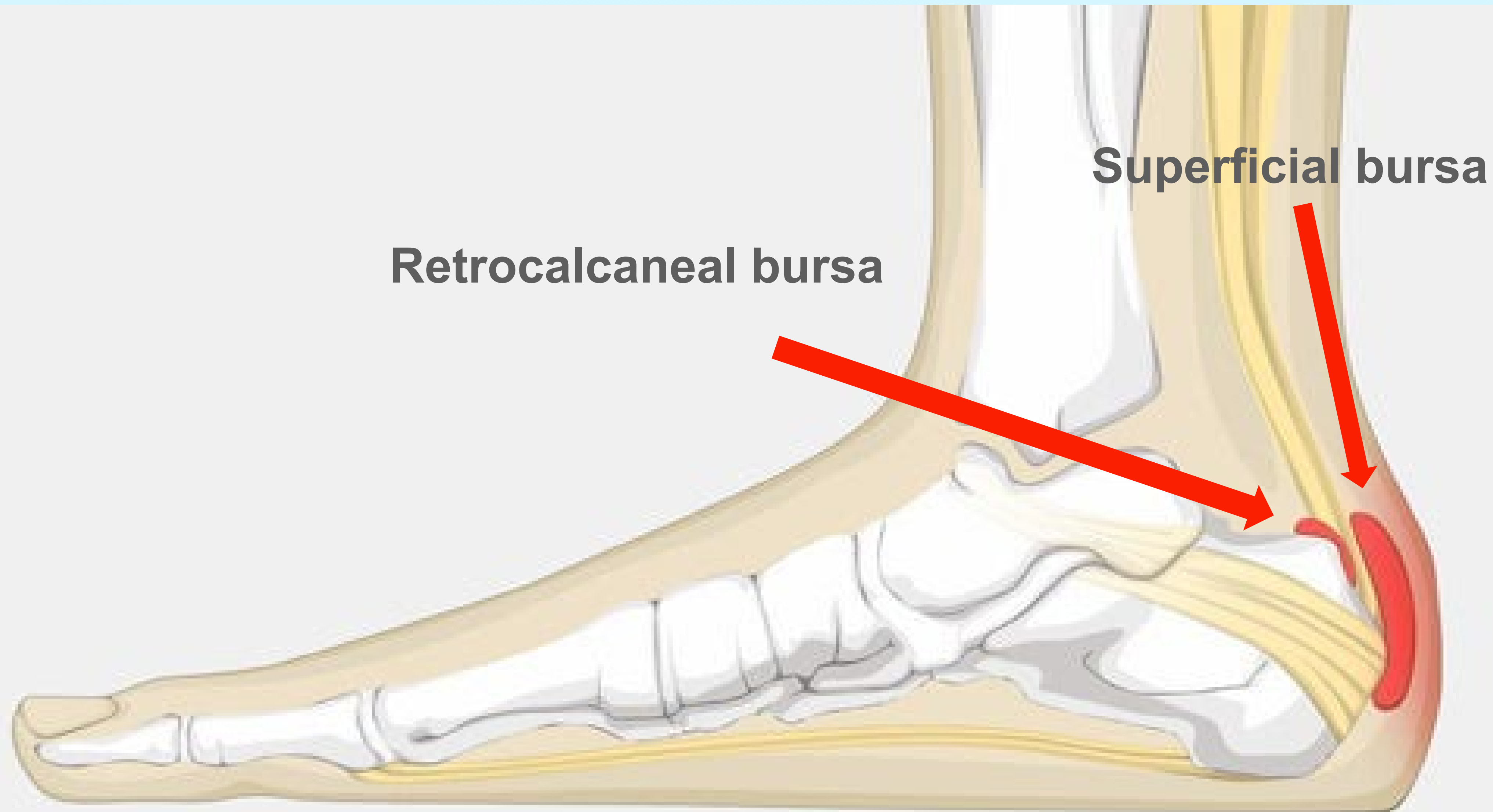
right achilles trans

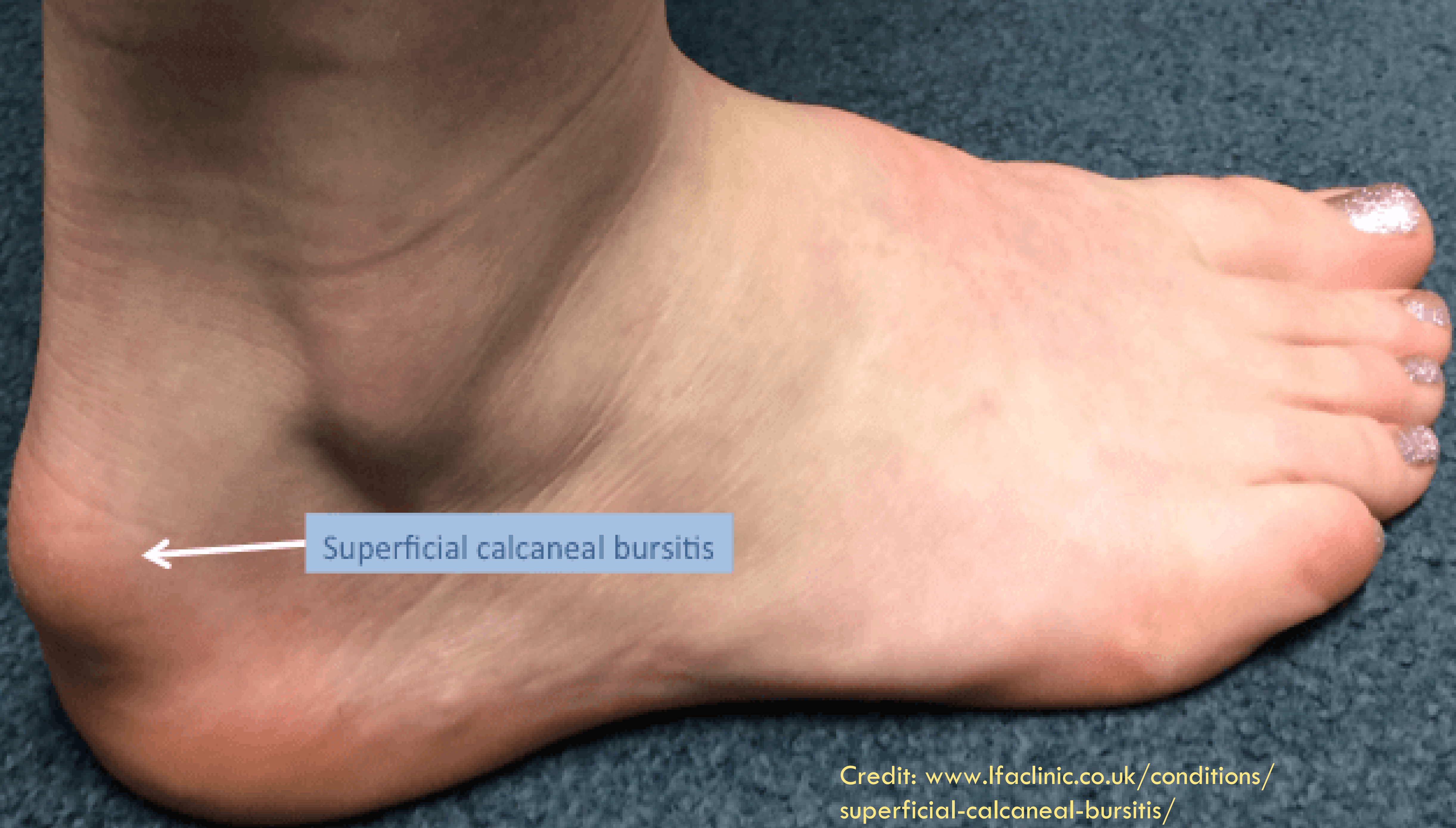

Retrocalcaneal fluid



BURSITIS





Superficial calcaneal bursitis

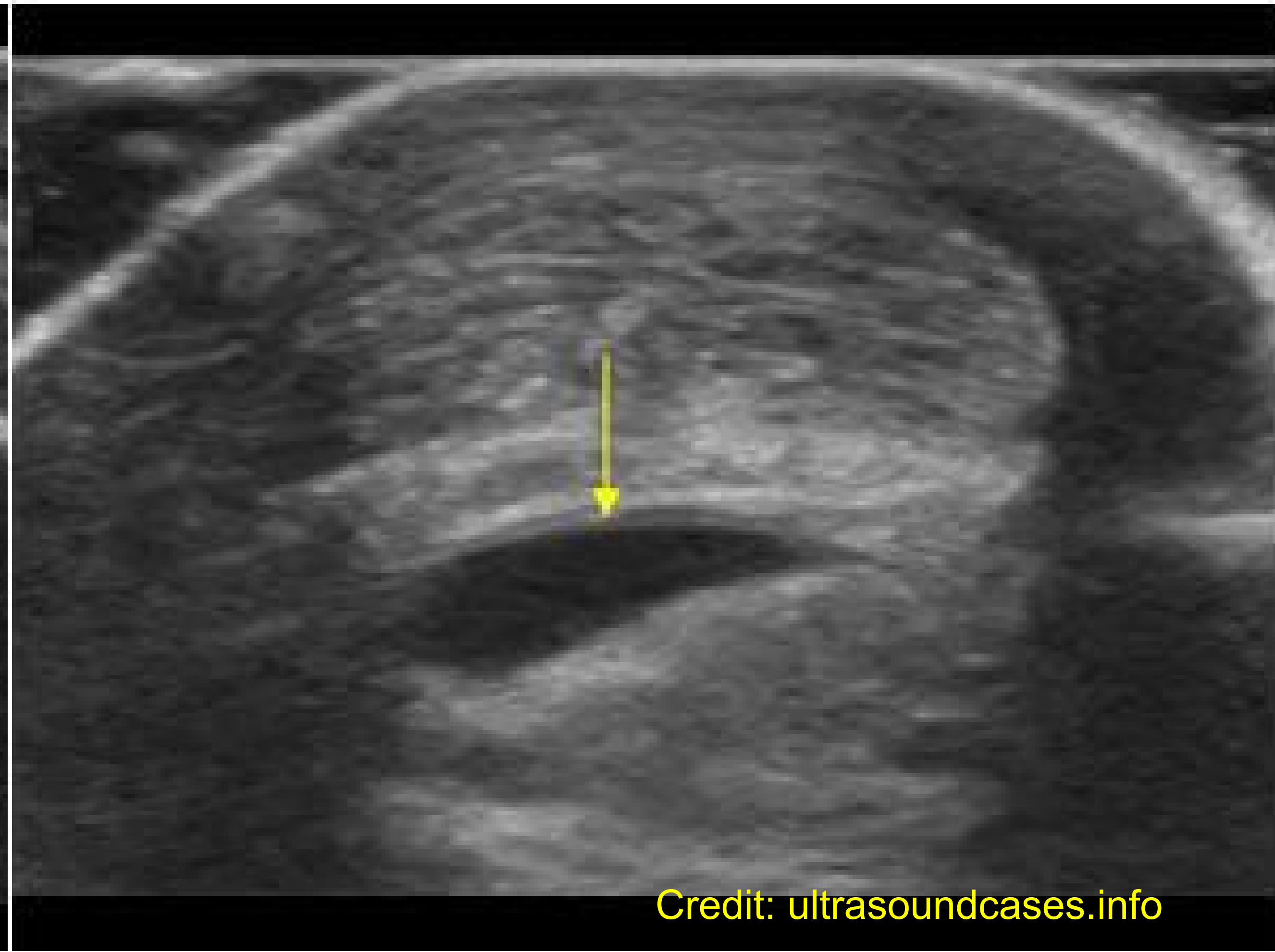
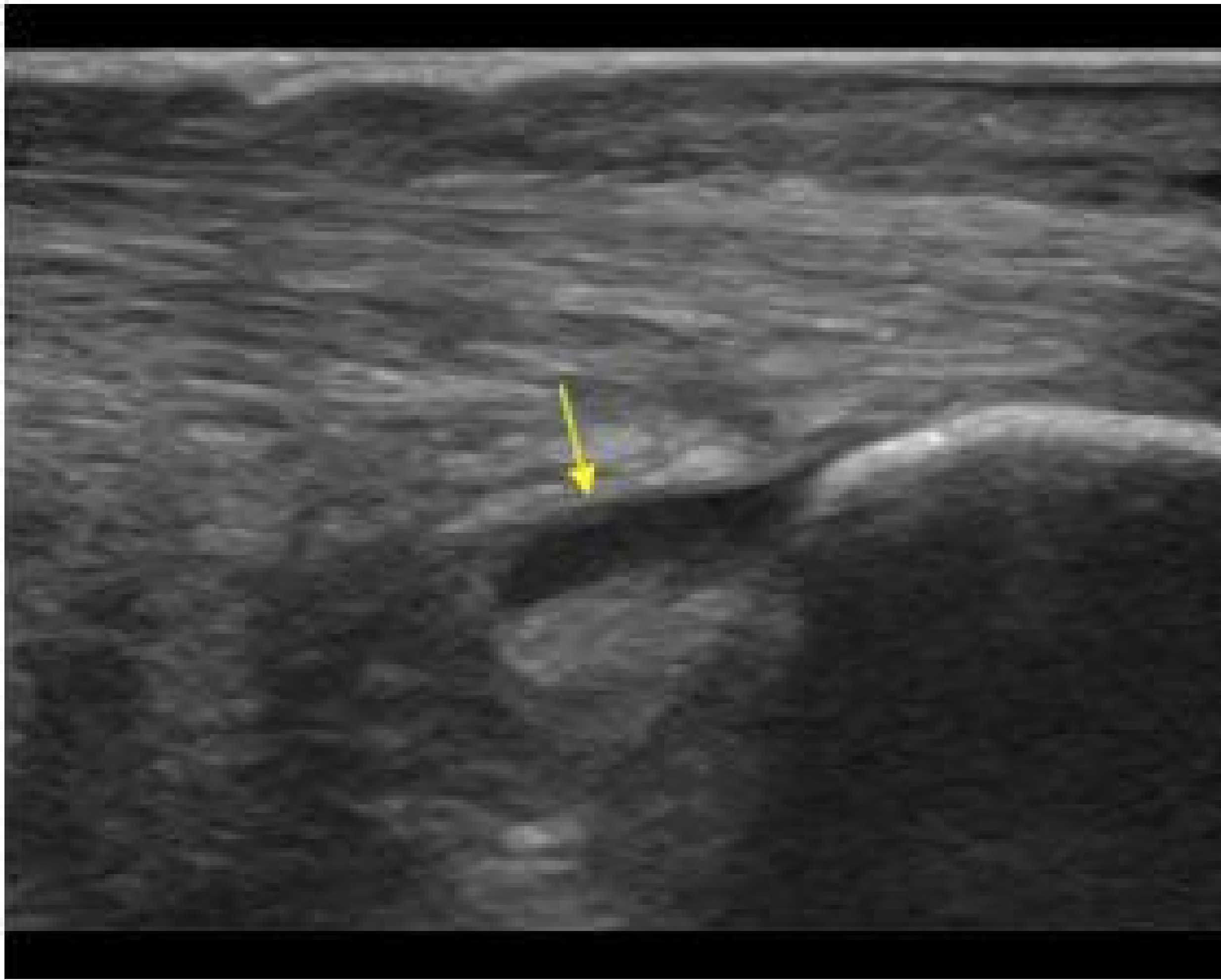
Credit: www.lfaclinic.co.uk/conditions/superficial-calcaneal-bursitis/

Retrocalcaneal bursitis

Associated tendinopathy

Superficial bursitis

Friction

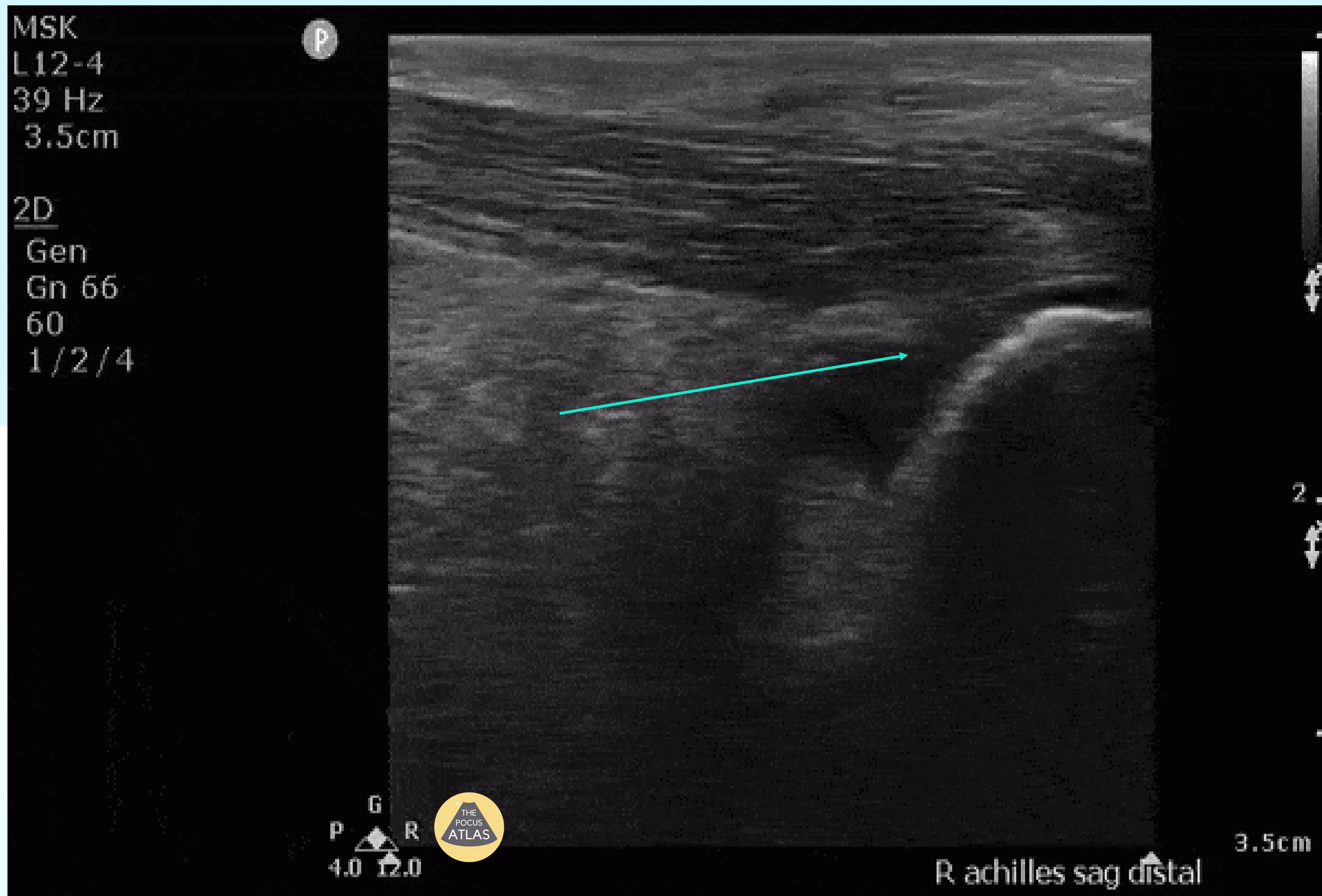


Credit: ultrasoundcases.info

LONG

SHORT

Retrocalcaneal bursitis



TREATMENT

Eccentric, heavy load rehabilitation

Injections

Topical nitroglycerine

Surgery

ECCENTRIC HEAVY LOAD

A

Heavy-Load Eccentric Calf Muscle Training For the Treatment of Chronic Achilles Tendinosis

Håkan Alfredson, MD, Tom Pietilä, RPT, Per Jonsson, RPT, and
Ronny Lorentzon,* MD, PhD

0363-5465/98/2626-0360\$02.00/0

THE AMERICAN JOURNAL OF SPORTS MEDICINE, Vol. 26, No. 3

© 1998 American Orthopaedic Society for Sports Medicine

Figure 1. From an upright body position and standing with all body weight on the forefoot and the ankle joint in plantar flexion lifted by the noninjured leg (A), the calf muscle was loaded eccentrically by having the patient lower the heel with the knee straight (B) and with the knee bent (C).

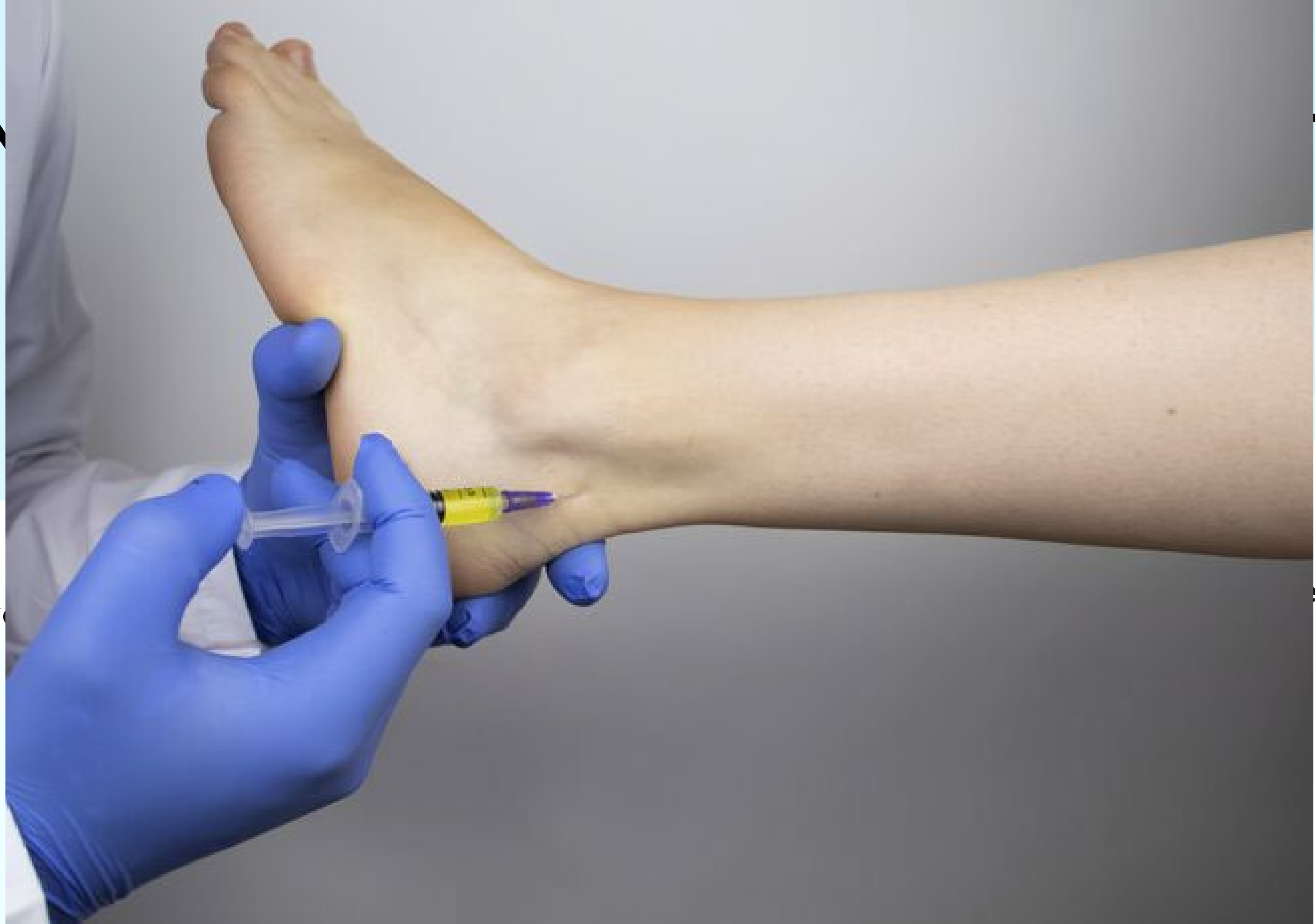IN

HY

What

Where

es at




BEST Achilles tendinopathy paper

Review

Achilles tendinopathy

Nicola Maffulli^{a,b}, Umile Giuseppe Longo^c, Anish Kadakia^d, Filippo




[Foot Ankle Surg.](#) 2020 Apr;26(3):240-249. doi: 10.1016/j.



References

- Statpearls: Achilles tendon rupture. <https://www.ncbi.nlm.nih.gov/books/NBK430844/>
- Orthobullets: Achilles tendon rupture. <https://www.orthobullets.com/foot-and-ankle/7021/achilles-tendon-rupture>
- Thompson test: Life in the Fast Lane. <https://litfl.com/simmonds-thompson-test/>
- Thompson test: Wikipedia. https://en.wikipedia.org/wiki/Thompson_test
- Retrocalcaneal bursitis. https://www.physio-pedia.com/Retrocalcaneal_Bursitis
- Achilles tendinopathy.
- The Achilles Tendon: Imaging Diagnoses and Image-Guided Interventions—AJR Expert Panel Narrative Review. *AJR* 2022; 219:355–368. doi.org/10.2214/AJR.22.27632
- Effect of High-Volume Injection, Platelet- Rich Plasma, and Sham Treatment in Chronic Midportion Achilles Tendinopathy. *J Sports Med*. 2017 Jul;45(9):2034-2043.
- Musculoskeletal ultrasound for sports injuries. *Eur J Phys Rehabil Med*. 2012 Dec;48(4):651-63; quiz 707
- Ultrasound Cases database: <https://www.ultrasoundcases.info/>
- The POCUS Atlas: <https://www.thepocusatlas.com/musculoskeletal>



Next UP

**Nov 17 2023: Ultrasound-guided MSK injections
Dr Oron Frenkel, St Paul's ED**


**Jan 26 2024: Shoulder MSK
Dr Oron Frenkel, St Paul's ED**

Dr Oron Frenkel



UBC CPD
Medicine

CONTINUING
PROFESSIONAL
DEVELOPMENT




**Rural Coordination
Centre of BC**



Questions?

UBC CPD
Medicine
CONTINUING
PROFESSIONAL
DEVELOPMENT




**Rural Coordination
Centre of BC**



Questions?



BEST Paper



**Rural POCUS
Rounds**