

Rural POCUS Rounds: Intro to MSK Ultrasound

The Journey Until Today

Dr. Frank Johnson, MD, CCFP (SEM), Dip.Sport Med
Aug 8, 2025



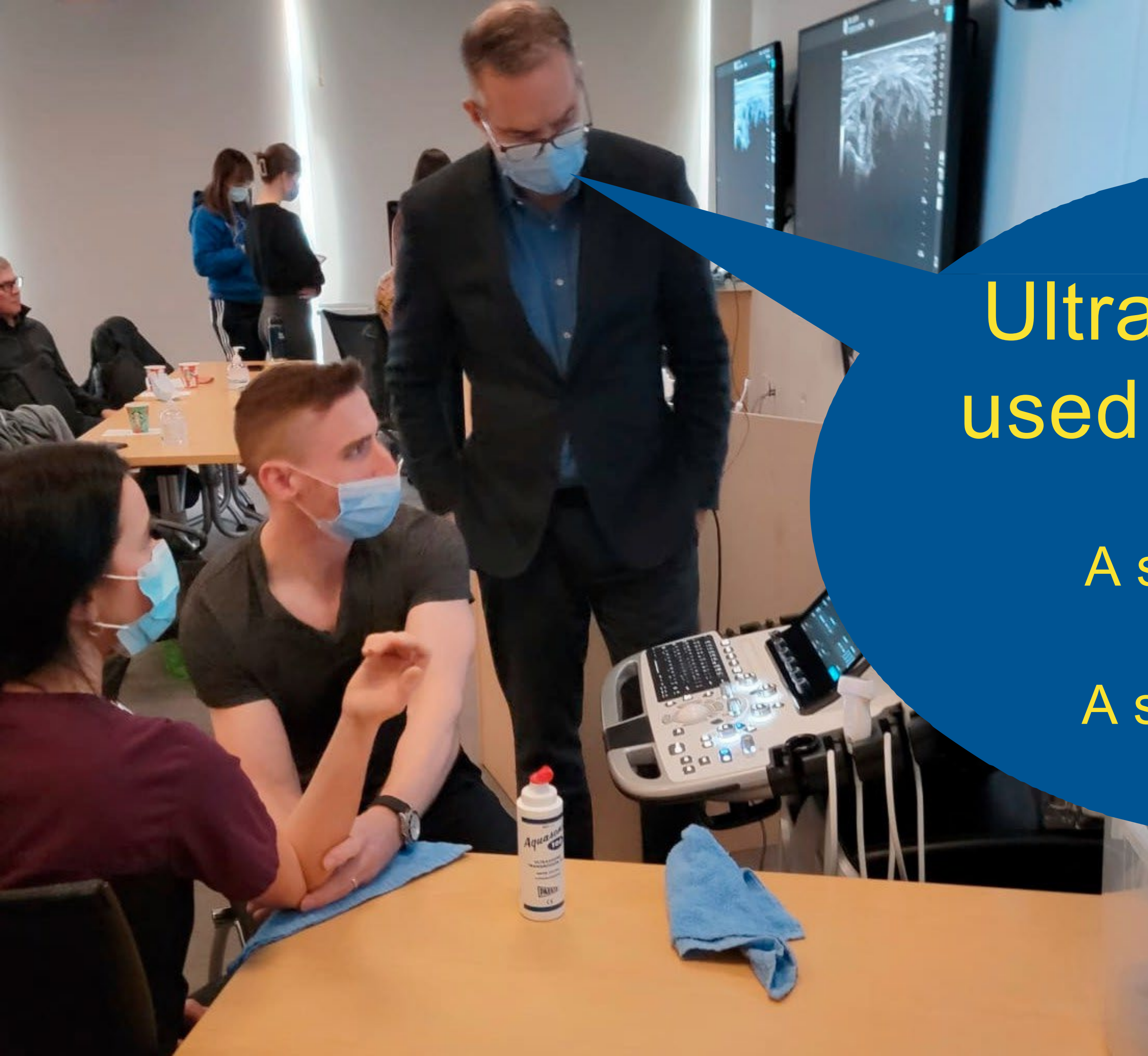THE UNIVERSITY OF BRITISH COLUMBIA

Continuing Professional Development

Faculty of Medicine

Faculty/Presenter Disclosure

- Faculty: Dr. Frank Johnson
- Relationships with financial sponsors:
 - Speakers Honoraria: Pendopharm (Monovisc, Cingal SportVis)
 - Consulting Fees: Clarius and Pendopharm to make educational videos
- Disclosure of financial support:
 - Received financial support from the AAOM, a large American Prolotherapy and PRP training organization
 - Sport Medicine Ultrasound (run by me) benefits from the sale of tickets to its live training events, a product that will not be discussed in this program




Ultrasound is best
used when there is:

A superficial target

A specific question

What is your superficial target?
What is your specific question?



What is your superficial target?
What is your specific question?

**GH JOINT
EFFUSION?
/ HEMARTHROSIS?**

What is your superficial target?
What is your specific question?


**GH JOINT
EFFUSION?
/ HEMARTHROSIS?**

Image GHJ1:
Transverse on posterior GHJ



What is your superficial target?
What is your specific question?

GH JOINT EFFUSION? / HEMARTHROSIS?	Image GHJ1: Transverse on posterior GHJ
QUESTIONS	Question GHJ1: Large black (effusion) or grey fluid (hemarthrosis) collection?



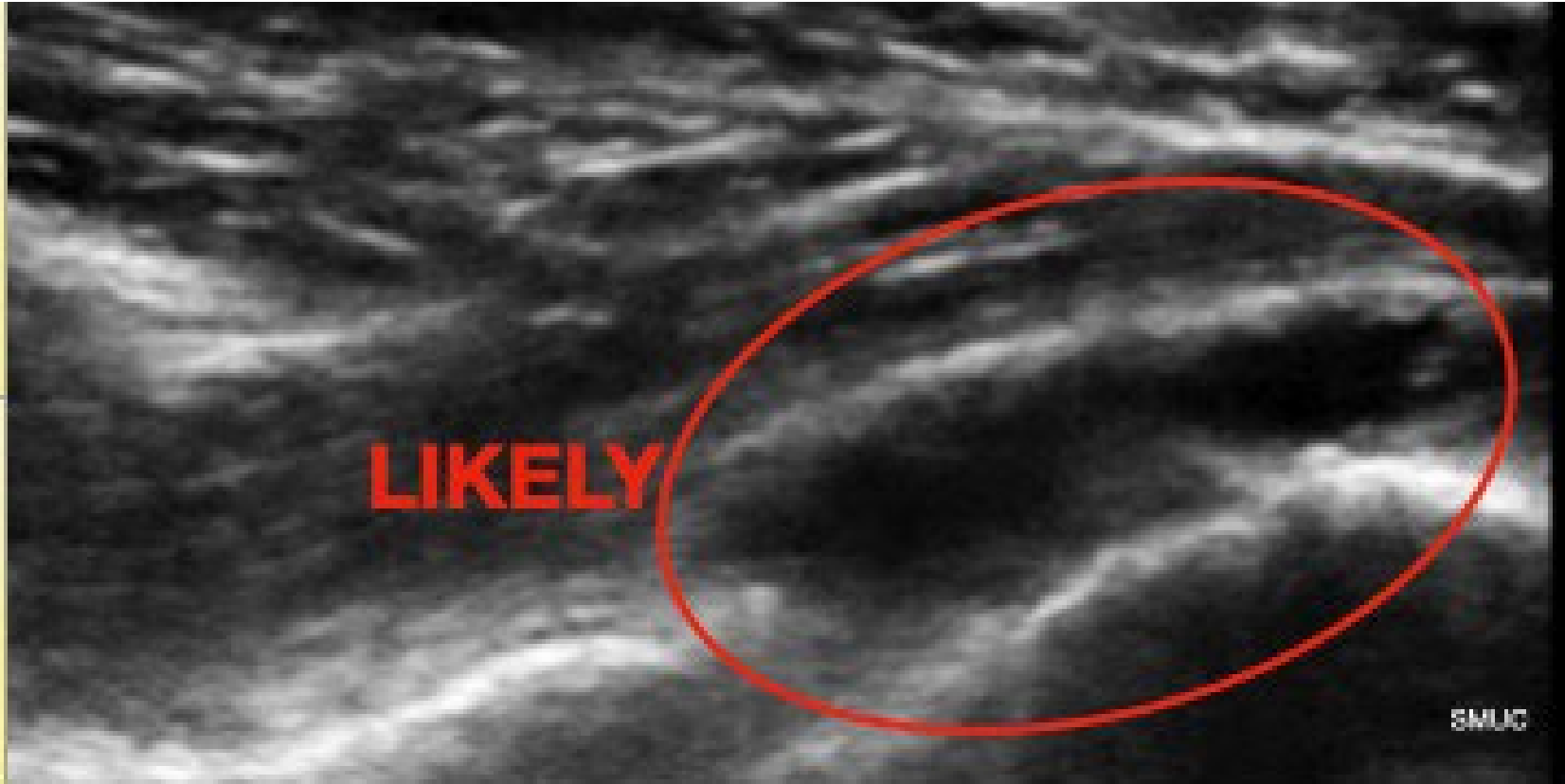What is your superficial target?
What is your specific question?


GH JOINT EFFUSION? / HEMARTHROSIS?	Image GHJ1: Transverse on posterior GHJ
QUESTIONS	Question GHJ1: Large black (effusion) or grey fluid (hemarthrosis) collection?
LIKELY	+ Yes large fluid collection: + Effusion/Hemarthrosis LIKELY



What is your superficial target?
What is your specific question?

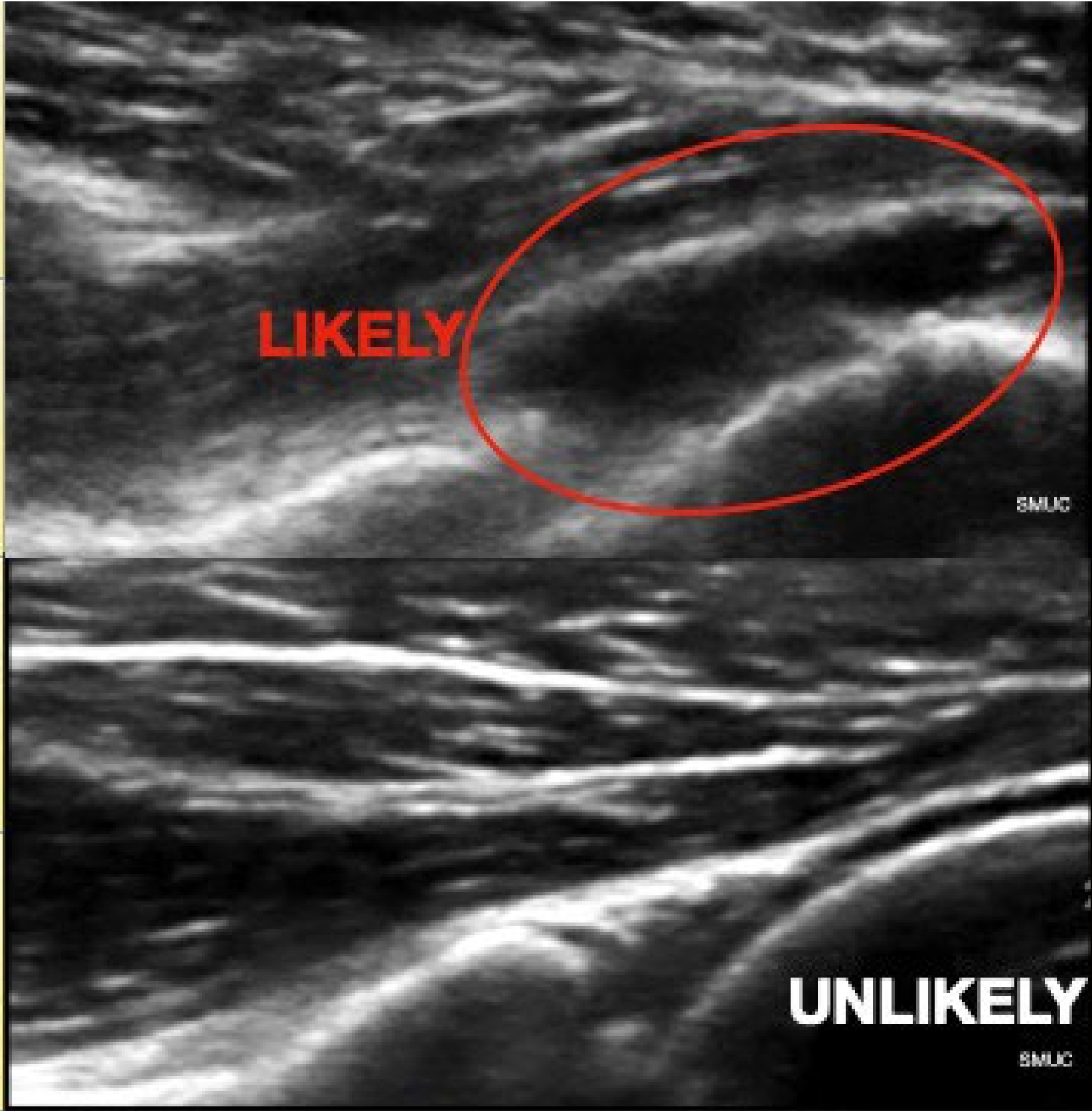GH JOINT EFFUSION? / HEMARTHROSIS?	Image GHJ1: Transverse on posterior GHJ
QUESTIONS	Question GHJ1: Large black (effusion) or grey fluid (hemarthrosis) collection?
LIKELY	+ Yes large fluid collection: + Effusion/Hemarthrosis LIKELY






What is your superficial target?
What is your specific question?

GH JOINT EFFUSION? / HEMARTHROSIS?	Image GHJ1: Transverse on posterior GHJ
QUESTIONS	Question GHJ1: Large black (effusion) or grey fluid (hemarthrosis) collection?
LIKELY	+ Yes large fluid collection: + Effusion/Hemarthrosis LIKELY
UNLIKELY	- No large fluid collection: - Effusion/Hemarthrosis UNLIKELY





I am not certifying you
as competent in using
this protocol to diagnose
injuries.



You have to scan each joint 100 times or more to know the “normal”



This is for
entertainment
purposes only and
not meant to treat or
cure any disease.

Break

- Is the bone angled?
- Is the bone discontinuous?

Osteophyte

- Is there a bony prominence near an articulation?

uneven cortex/articulation

- Is there a large defect in the bone?
- Is there an abnormal articulation?

Enthesis

- Is there an irregular bony surface where the tendon or ligament attaches?

Hypoechoic/anechoic

Occupying a space

- Is it pushing soft tissue away?
- I.e. stretching a joint capsule or pushing away a fat pad?

2 Questions

1. Is the fluid Free or Contained?
2. Is the fluid Simple or Complex?

Thickness

- Is the tissue thickened or thinned?

Irregular

- Is there an irregular shape of the tendon/ligament?

Same

- Is the tissue the same as the other side?

Signal of doppler

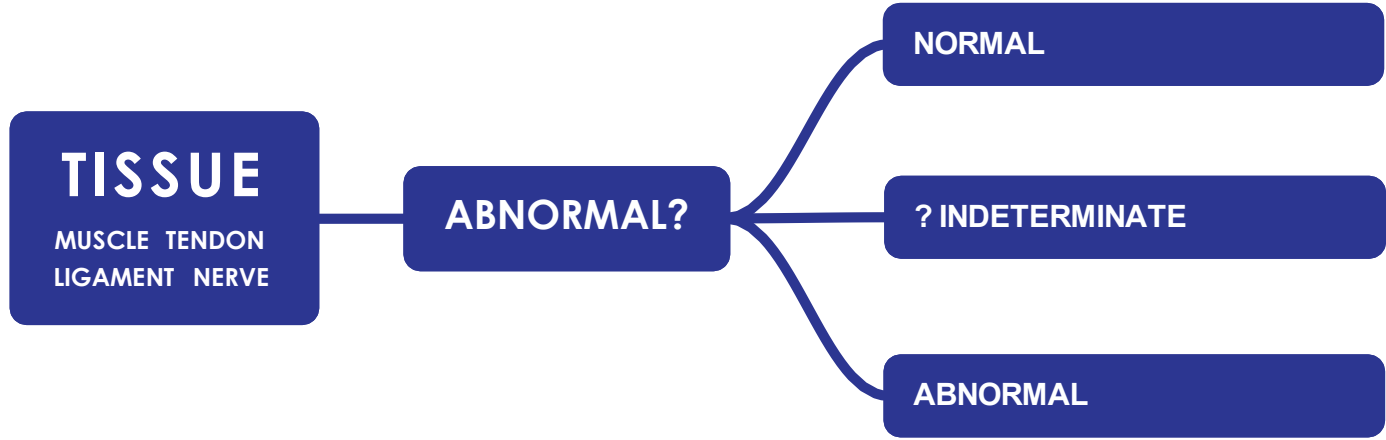
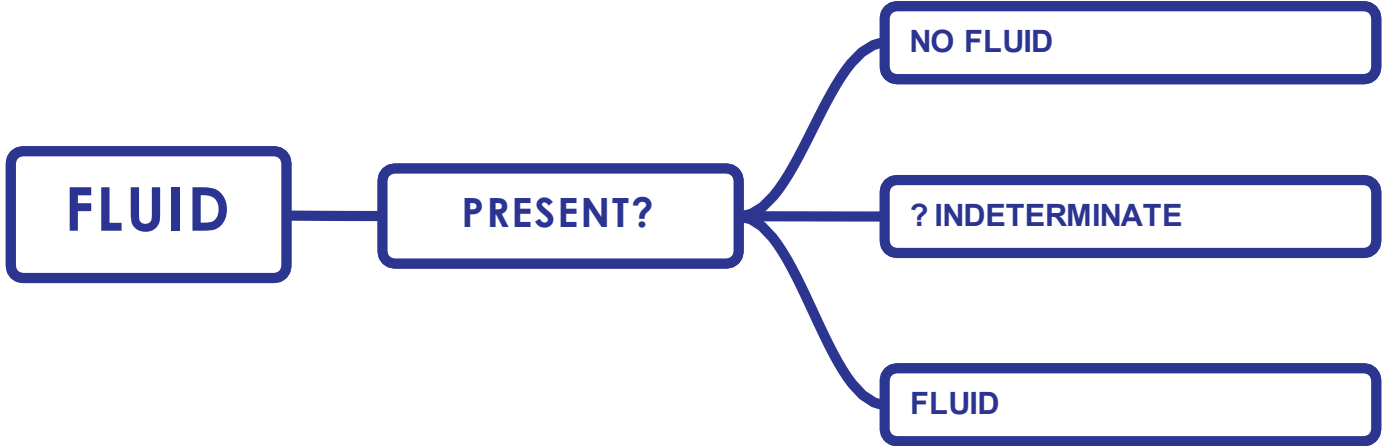
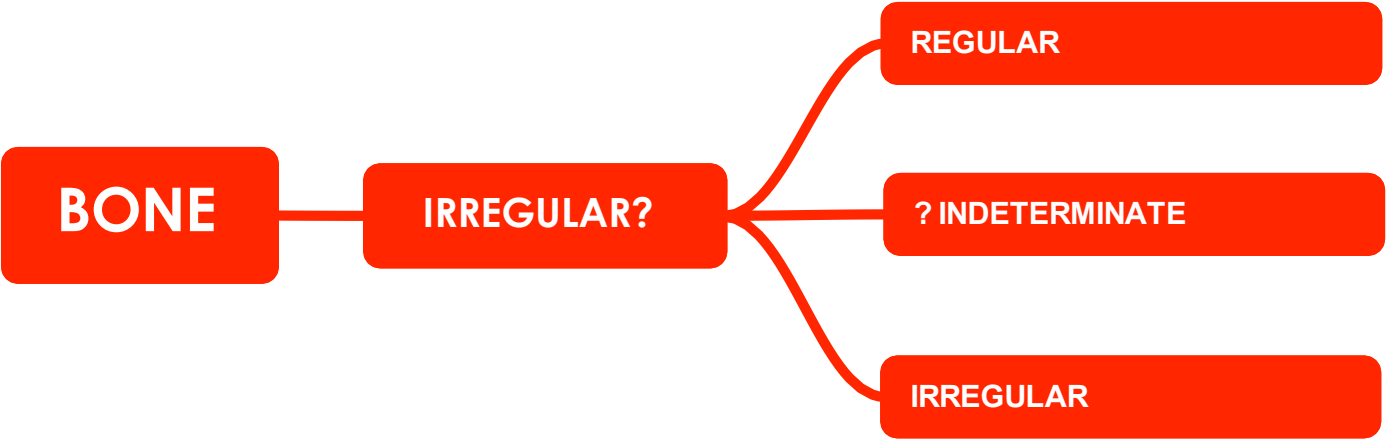
- Is the doppler signal high?

Unusual fibers

- Are the fibers unusual or discontinuous?

Echogenicity

- Is the tissue hyperechoic, hypoechoic or anechoic?



CBD

Calcium

- Linear or pinpoint
- Oval or round
- Dimensions in mm

Bony irregularity

- Small area
- Large area
- Dimensions in mm

Doppler

- Low, medium, or high

THC

Thickness

- Compared to contralateral side
- Dimensions in mm

Heterogeneity

- Homogenous
- Heterogenous

Colour

- Hypo vs Hyperechoic
- Is there anisotropy?

LSD

Location

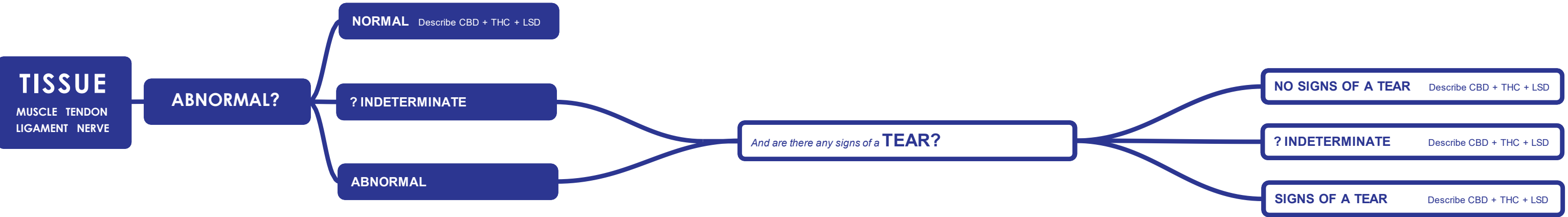
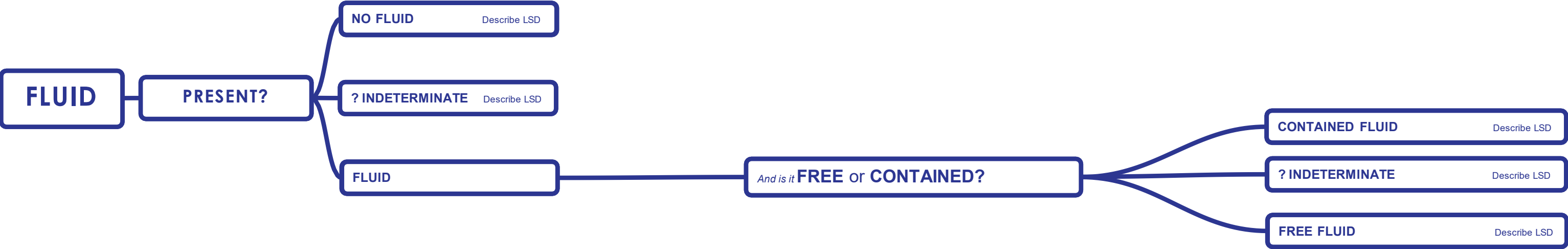
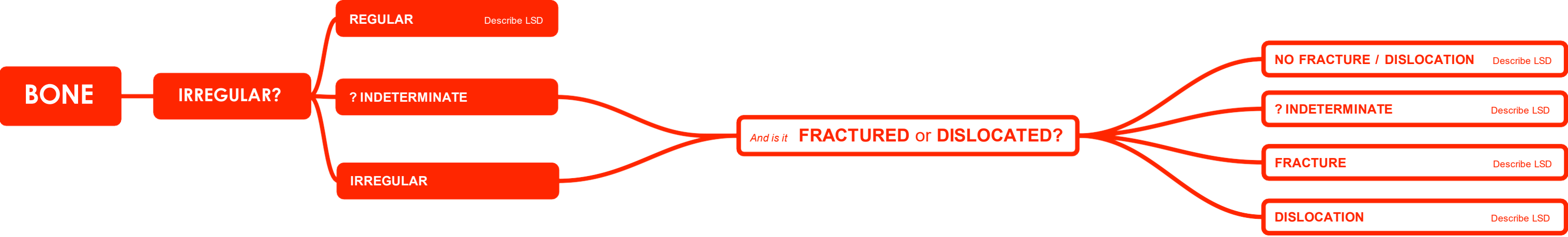
- Superficial or Deep
- Anterior or Posterior
- Medial or Lateral

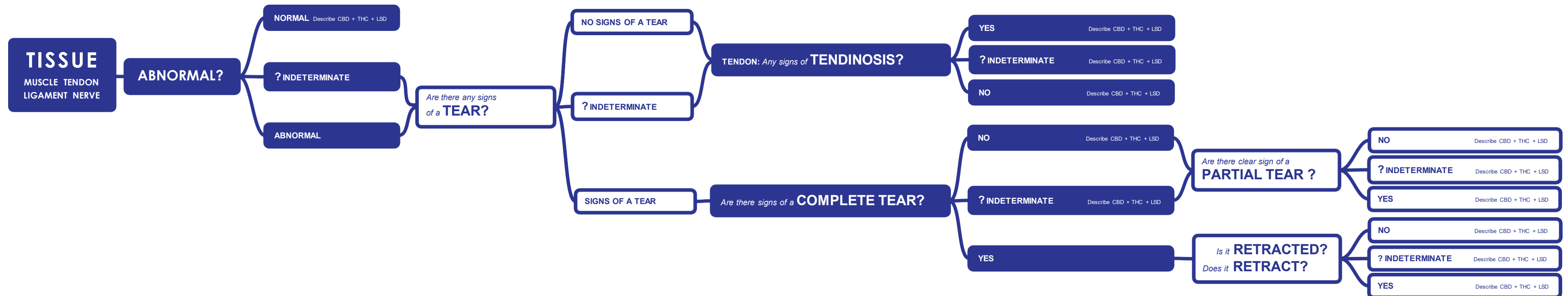
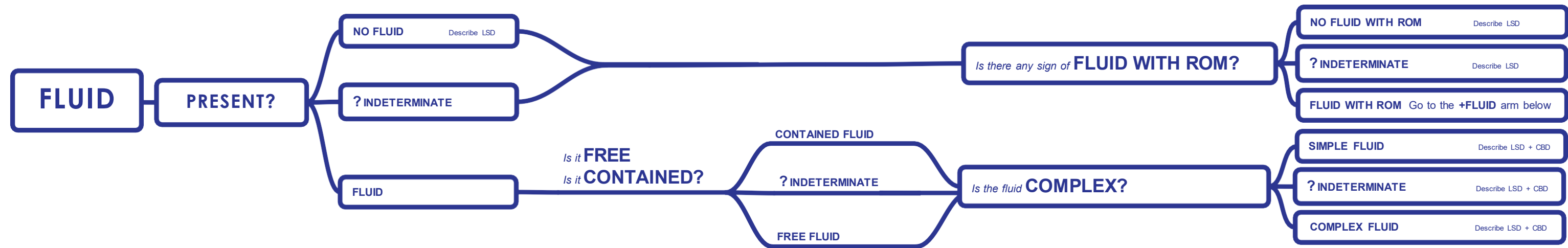
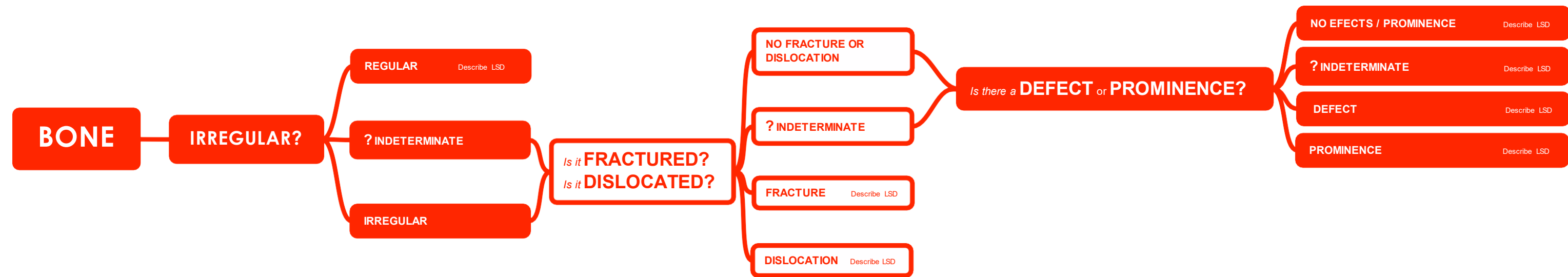
Shape

- Linear
- Curved
- Irregular

Dimensions

- in mm



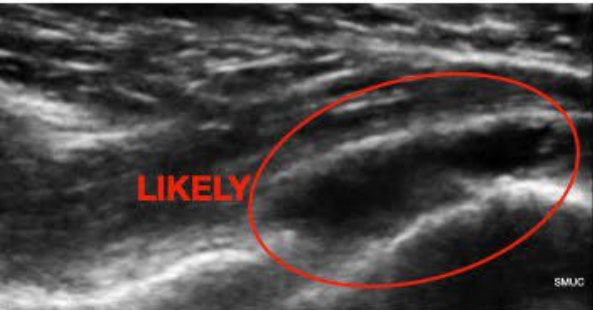
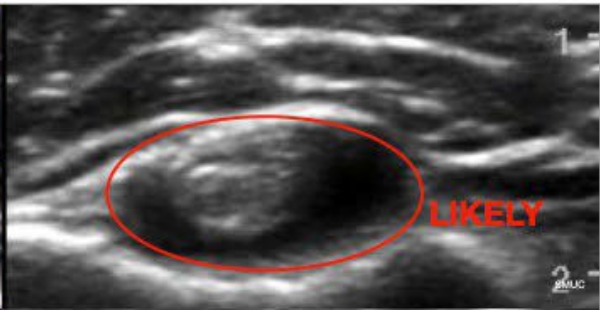
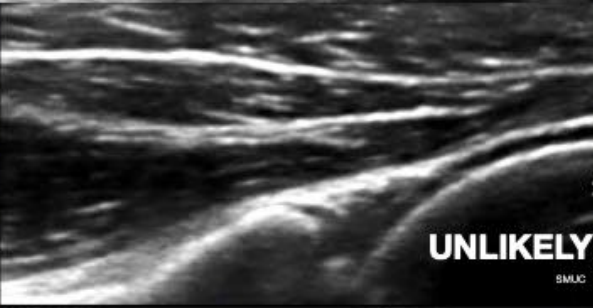
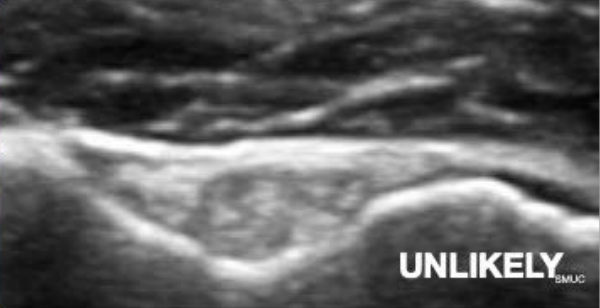
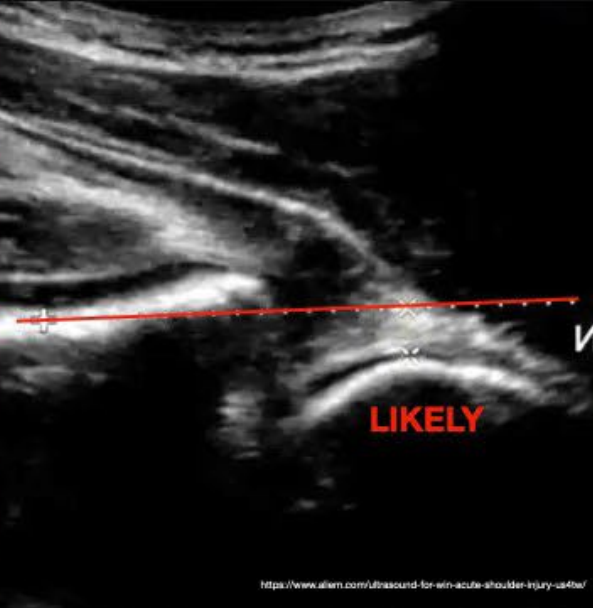




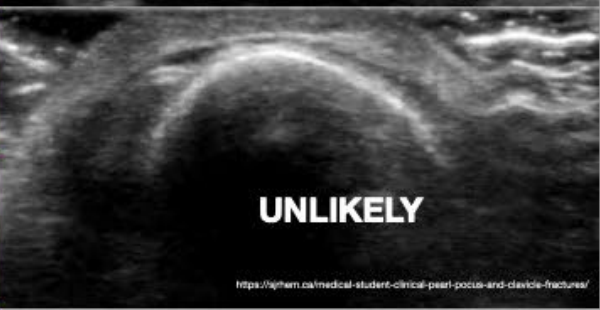




What is your superficial target?
What is your specific question?

SIDELINE ULTRASOUND: SHOULDER



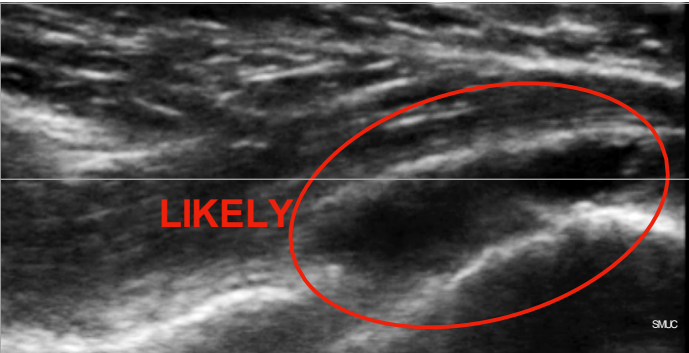
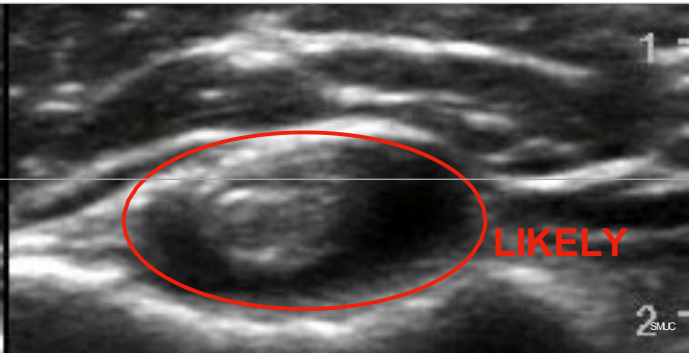
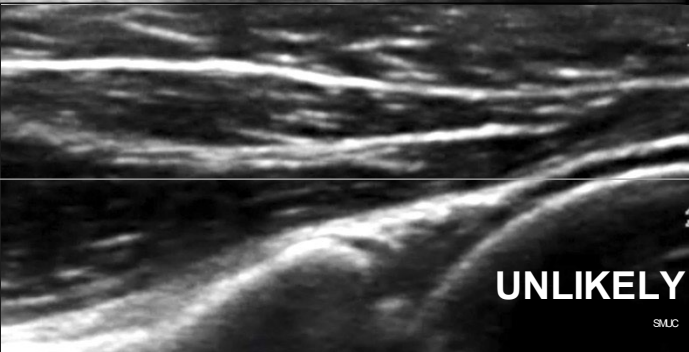
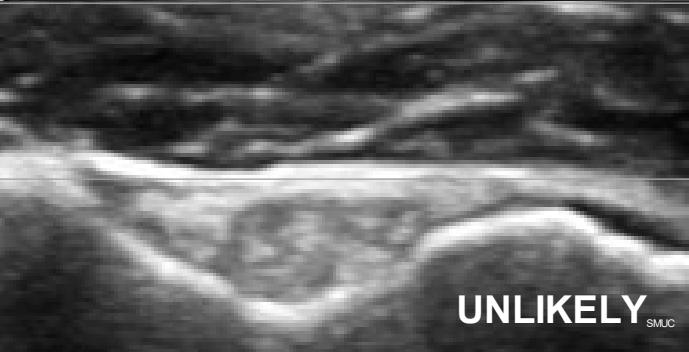
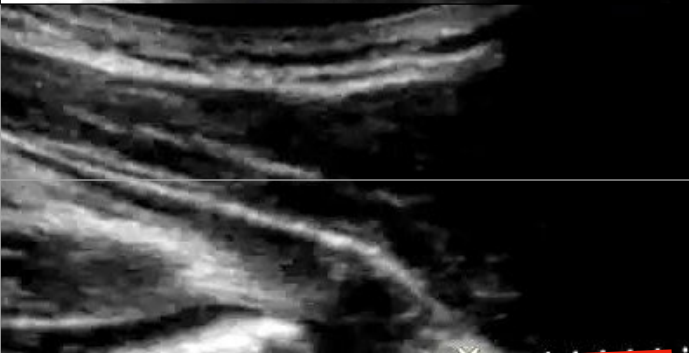
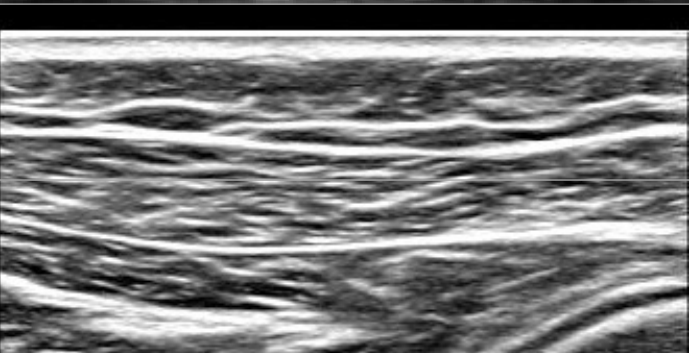
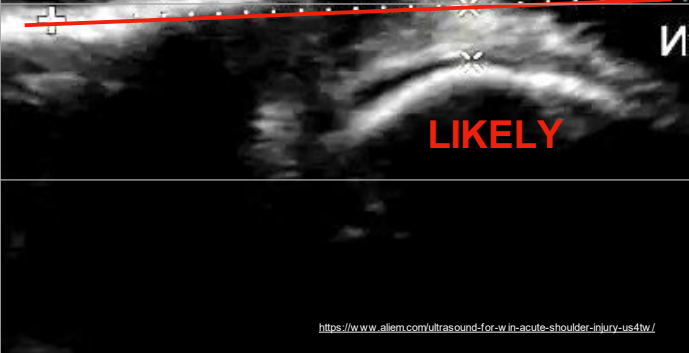
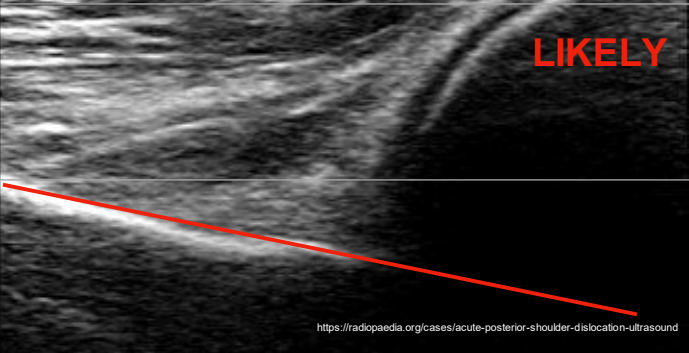
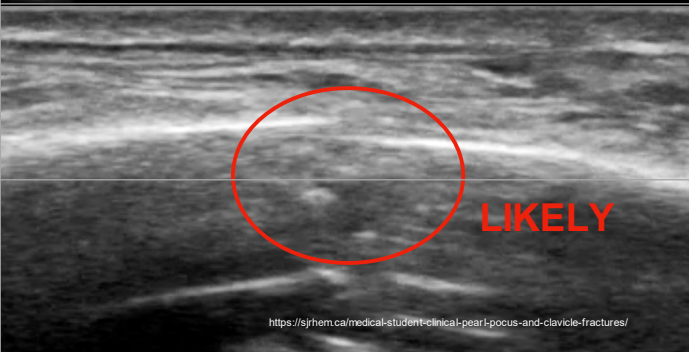
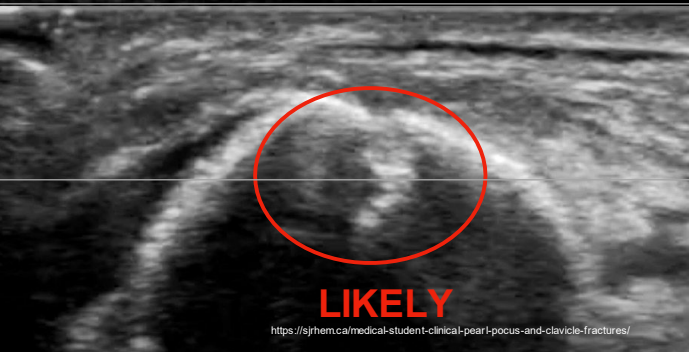
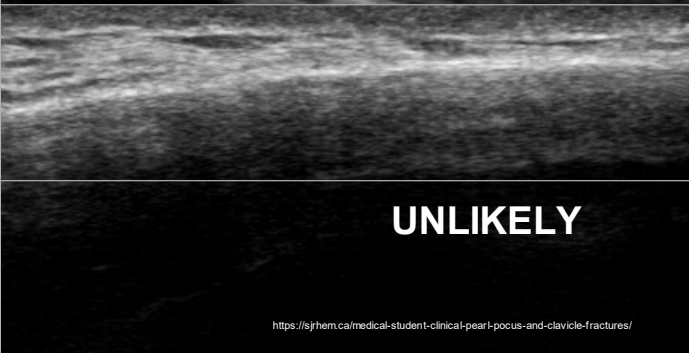

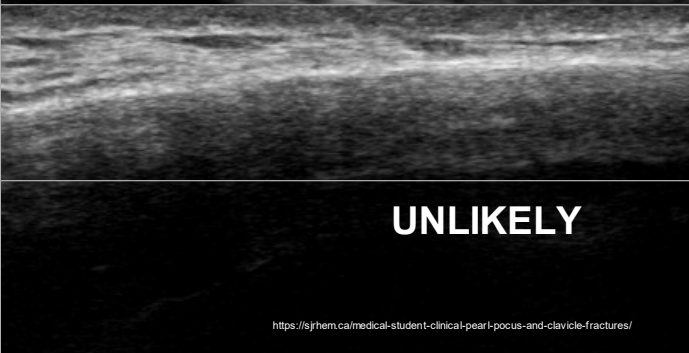



GH JOINT EFFUSION? / HEMARTHROSIS?	Image GHJ1: Transverse on posterior GHJ		Image GHJ2: Transverse over LHB distal to groove	
QUESTIONS	Question GHJ1: Large black (effusion) or grey fluid (hemarthrosis) collection?		Question GHJ2: Large black (effusion) or grey fluid (hemarthrosis) collection?	
LIKELY	+ Yes large fluid collection: + Effusion/Hemarthrosis LIKELY		+ Yes large fluid collection: + Effusion/Hemarthrosis LIKELY	
UNLIKELY	- No large fluid collection: - Effusion/Hemarthrosis UNLIKELY		- No large fluid collection: - Effusion/Hemarthrosis UNLIKELY	
GH JOINT DISLOCATION?	Image DISLOC1: Transverse on posterior GHJ		Image DISLOC2: Transverse on posterior GHJ	
QUESTIONS	Question DISLOC1: Humerus very far on screen?		Question DISLOC2: Humerus very near on screen?	
LIKELY	+ Yes: + Anterior dislocation LIKELY		+ Yes: + Posterior dislocation LIKELY	
UNLIKELY	- No - Anterior dislocation UNLIKELY		- No - Posterior dislocation UNLIKELY	
CLAVICLE FRACTURE?	Image CLAV1: Longitudinal on clavicle (must scan from SCJ to ACJ)		Image CLAV2: Transverse on clavicle (must scan from SCJ to ACJ)	
QUESTIONS	Question CLAV1: Bony cortex interrupted?		Question CLAV2: Bony cortex interrupted?	
LIKELY	+ Yes: + Fracture is LIKELY		+ Yes: + Fracture is LIKELY	
UNLIKELY	- No: - Fracture is UNLIKELY		- No: - Fracture is UNLIKELY	

SIDELINE ULTRASOUND
CHART NOTE

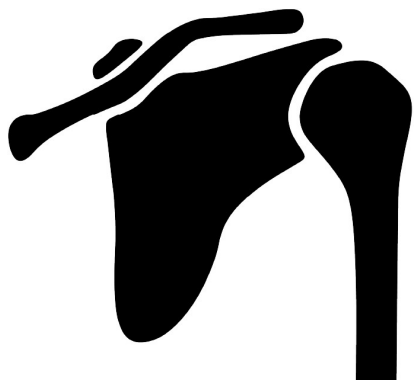

SITE OF
PAIN

NAME: _____
DATE & TIME: _____
FINDINGS: _____
ACTION: _____

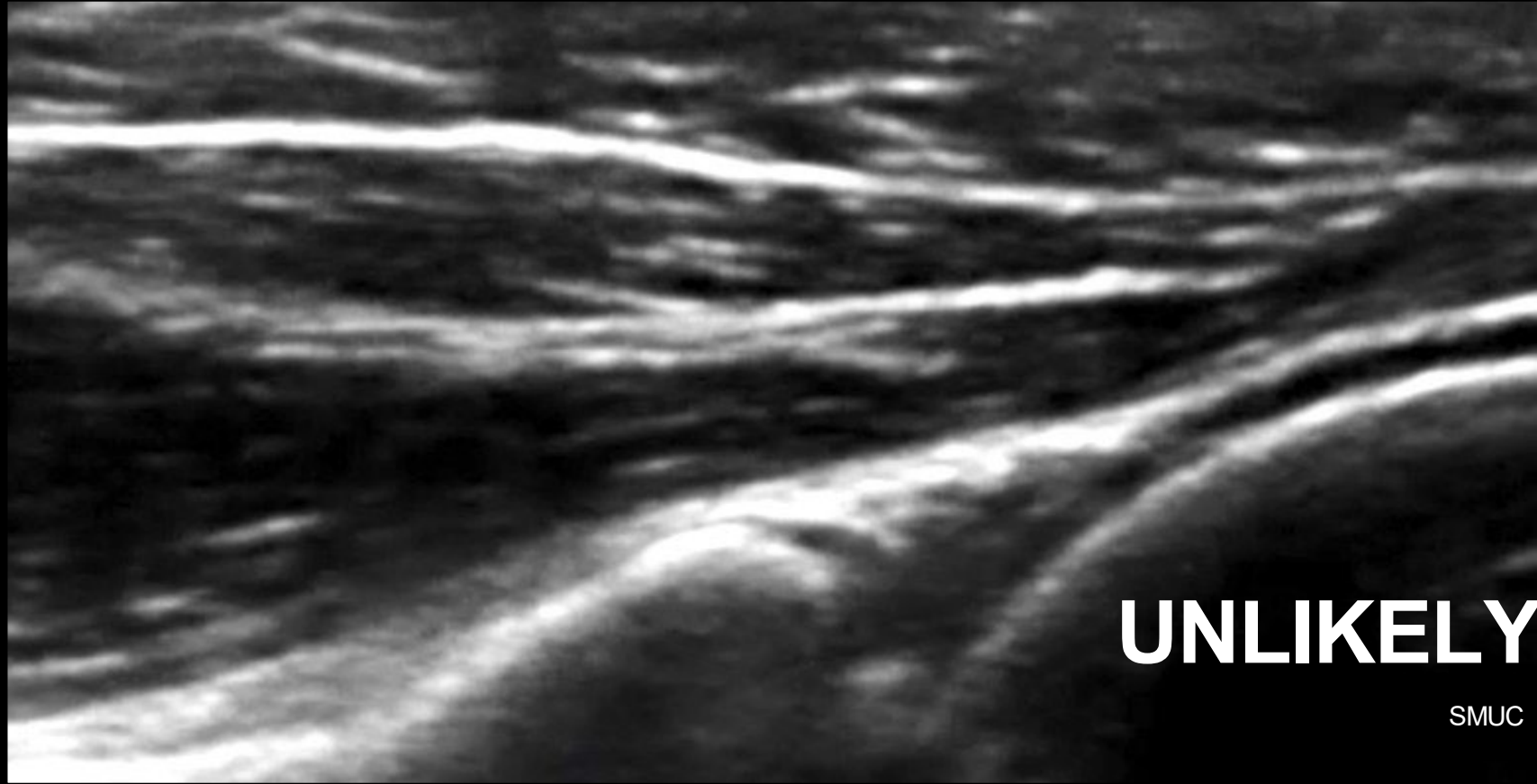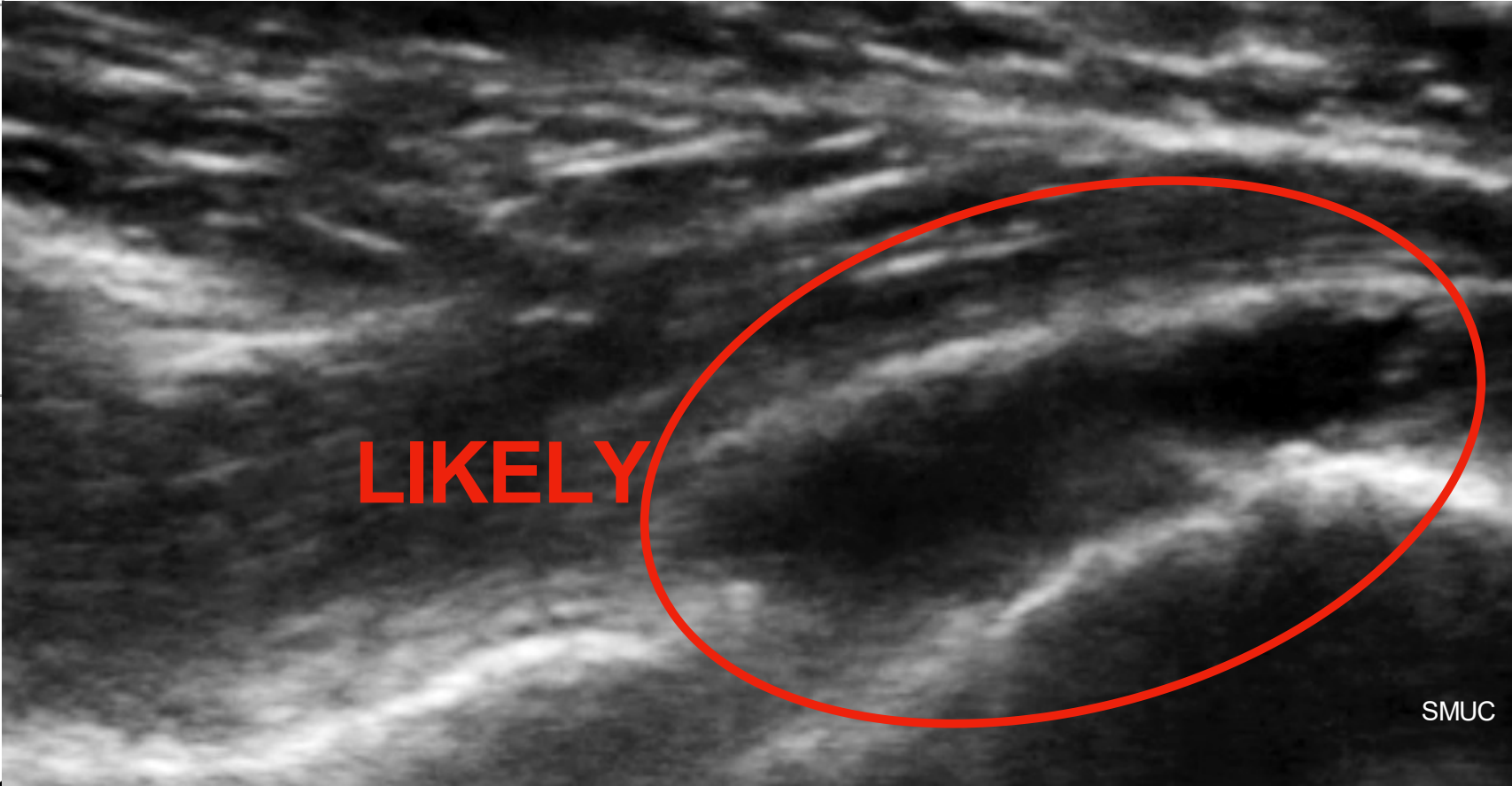
GH JOINT EFFUSION? / HEMARTHROSIS?	Image GHJ1: Transverse on posterior GHJ		Image GHJ2: Transverse over LHB distal to groove	
QUESTIONS	Question GHJ1: Large black (effusion) or grey fluid (hemarthrosis) collection?		Question GHJ2: Large black (effusion) or grey fluid (hemarthrosis) collection?	
LIKELY	+ Yes large fluid collection: + Effusion/Hemarthrosis LIKELY		+ Yes large fluid collection: + Effusion/Hemarthrosis LIKELY	
UNLIKELY	- No large fluid collection: - Effusion/Hemarthrosis UNLIKELY		- No large fluid collection: - Effusion/Hemarthrosis UNLIKELY	
GH JOINT DISLOCATION?	Image DISLOC1: Transverse on posterior GHJ		Image DISLOC2: Transverse on posterior GHJ	
QUESTIONS	Question DISLOC1: Humerus very far on screen?		Question DISLOC2: Humerus very near on screen?	
LIKELY	+ Yes: + Anterior dislocation LIKELY		+ Yes: + Posterior dislocation LIKELY	
UNLIKELY	- No - Anterior dislocation UNLIKELY		- No - Posterior dislocation UNLIKELY	
CLAVICLE FRACTURE?	Image CLAV1: Longitudinal on clavicle (must scan from SCJ to ACJ)		Image CLAV2: Transverse on clavicle (must scan from SCJ to ACJ)	
QUESTIONS	Question CLAV1: Bony cortex interrupted?		Question CLAV2: Bony cortex interrupted?	
LIKELY	+ Yes: + Fracture is LIKELY		+ Yes: + Fracture is LIKELY	
UNLIKELY	- No: - Fracture is UNLIKELY		- No: - Fracture is UNLIKELY	

SIDELINE ULTRASOUND CHART NOTE



SITE
PA

GH JOINT EFFUSION? / HEMARTHROSIS?	Image GHJ1: Transverse on posterior GHJ
QUESTIONS	Question GHJ1: Large black (effusion) or grey fluid (hemarthrosis) collection?
LIKELY	+ Yes large fluid collection: + Effusion/Hemarthrosis LIKELY
UNLIKELY	- No large fluid collection: - Effusion/Hemarthrosis UNLIKELY





SITE OF
PAIN

NAME: _____
DATE & TIME: _____
FINDINGS: _____
ACTION: _____

Image GHJ2:

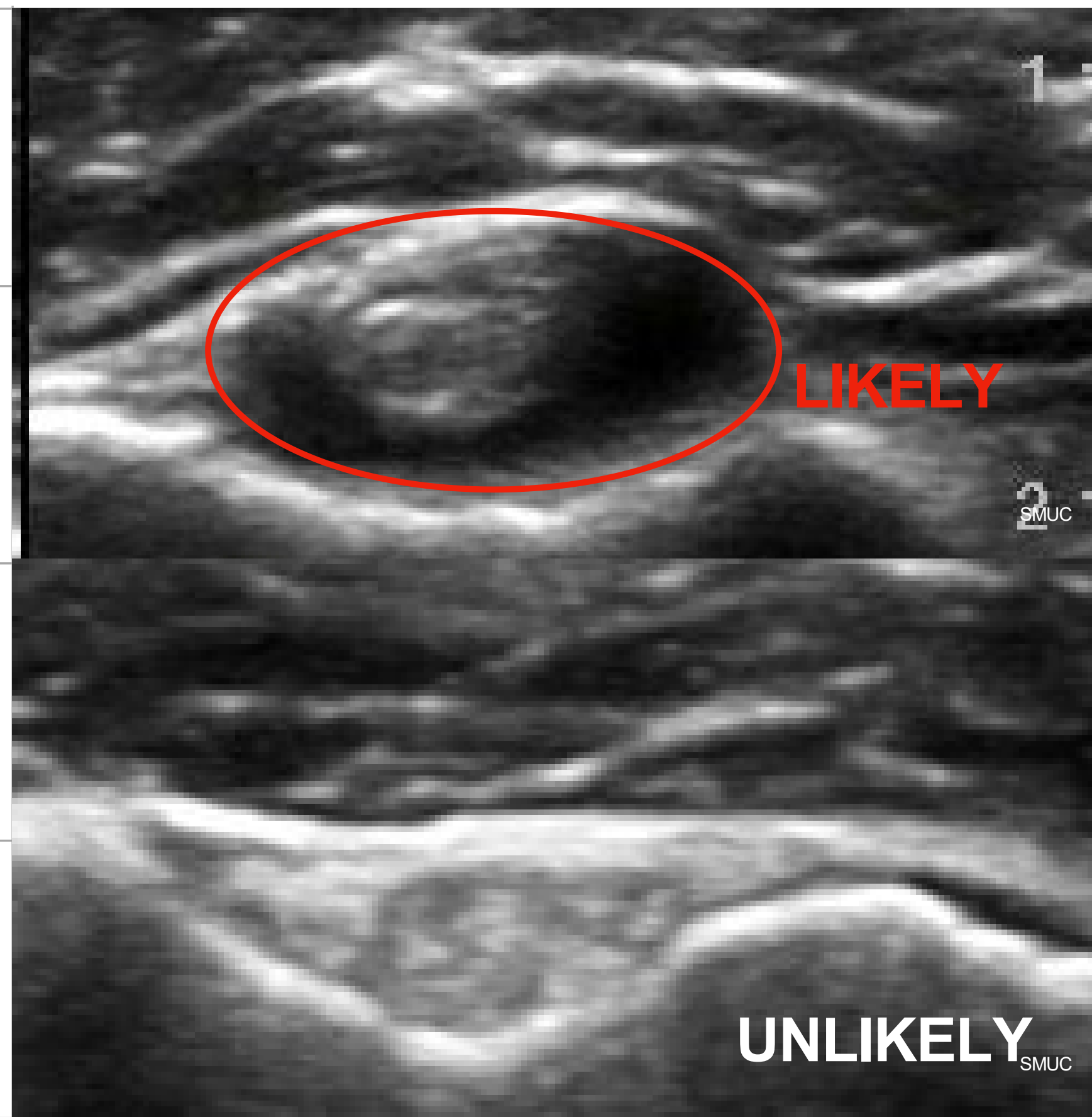
Transverse over LHB distal to groove

Question GHJ2:

Large black (effusion) or grey fluid (hemarthrosis) collection?

- + Yes large fluid collection:
- + Effusion/Hemarthrosis **LIKELY**

- No large fluid collection:
- Effusion/Hemarthrosis **UNLIKELY**



GH JOINT DISLOCATION?	Image DISLOC1: Transverse on posterior GHJ
QUESTIONS	Question DISLOC1: Humerus very far on screen?
LIKELY	+ Yes: + Anterior dislocation LIKELY
UNLIKELY	- No - Anterior dislocation UNLIKELY

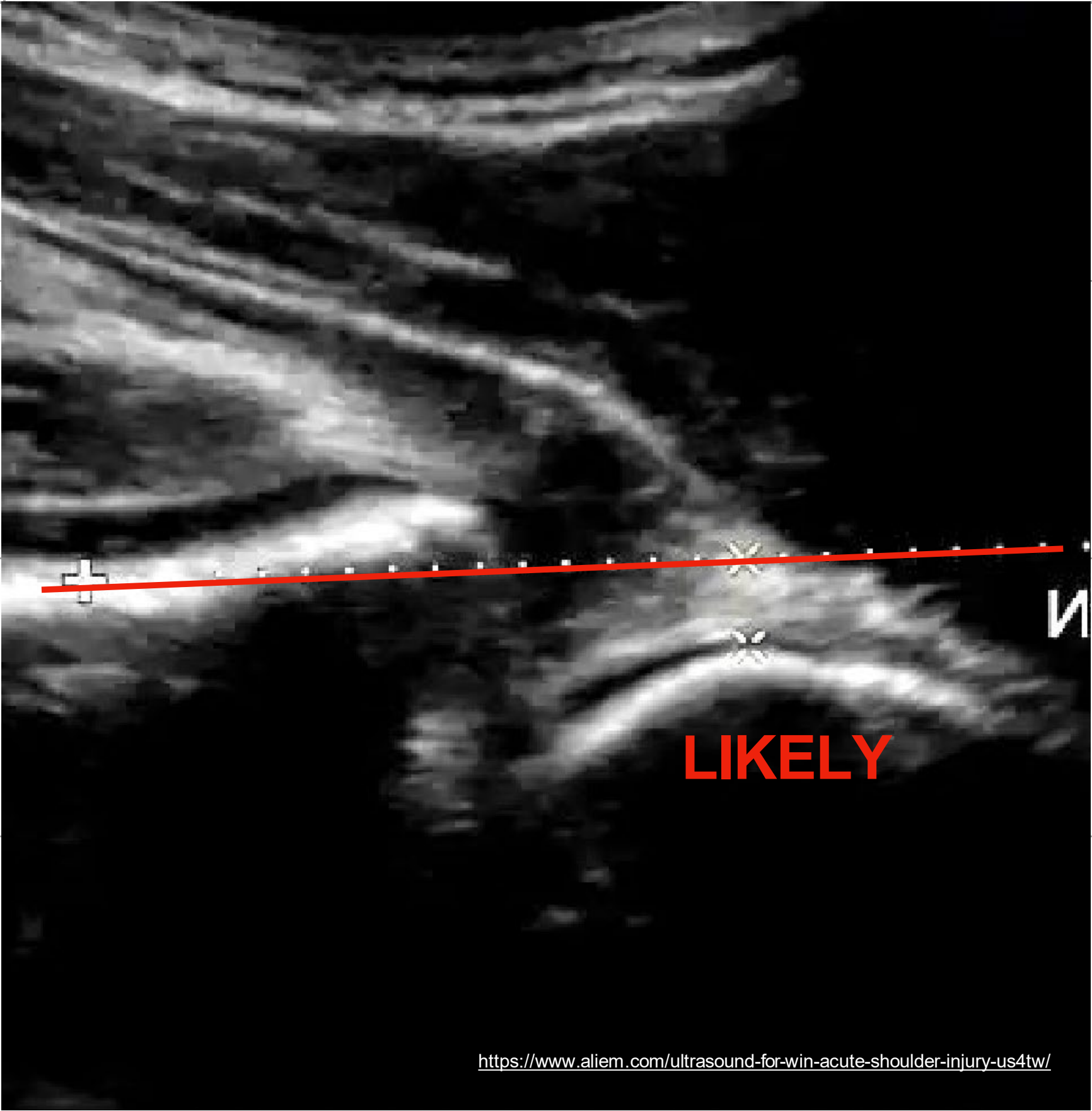


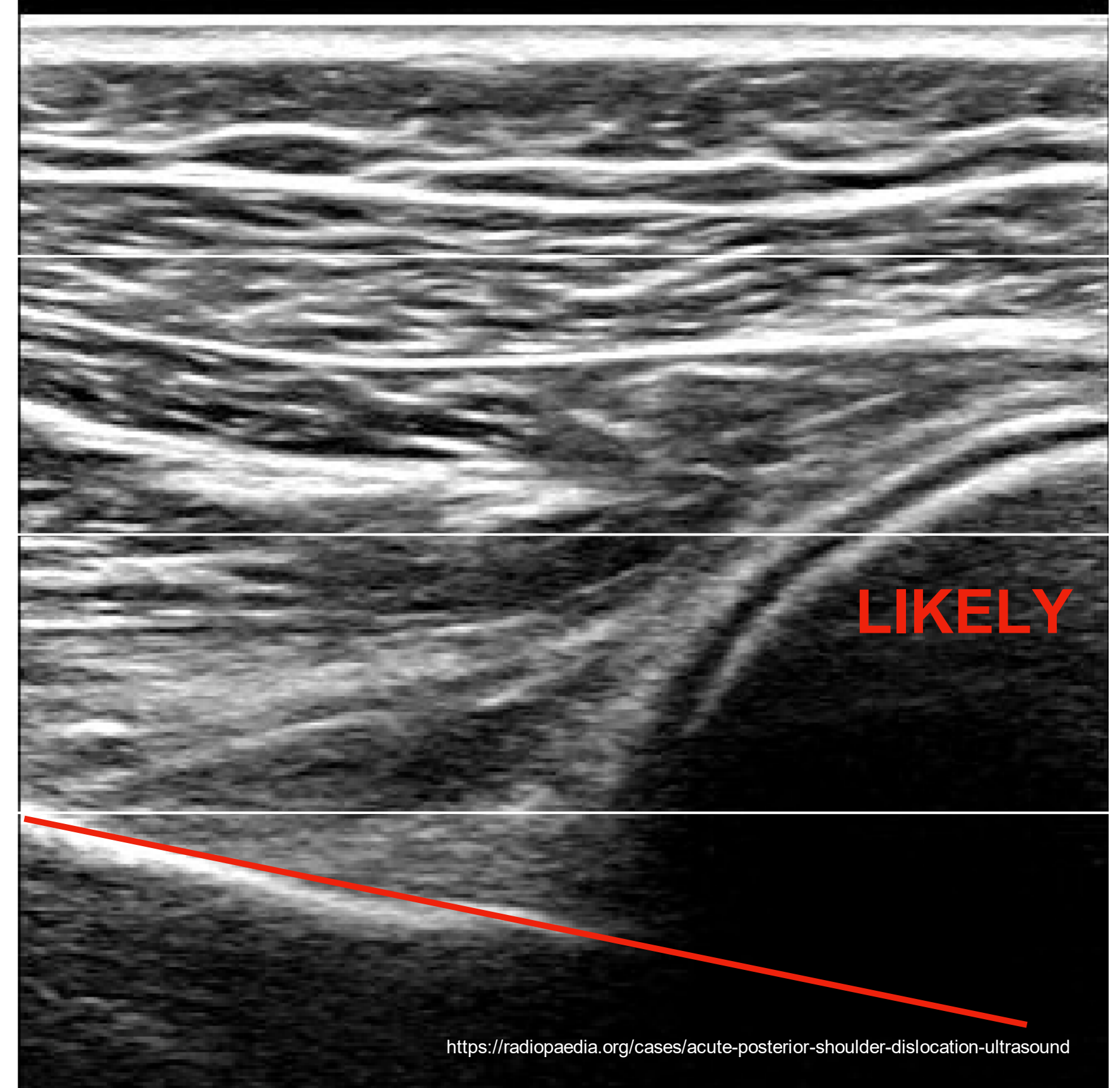
Image DISLOC2:

Transverse on posterior GHJ

Question DISLOC2:

Humerus very near on screen?

- + Yes:
- + Posterior dislocation **LIKELY**
- No
- Posterior dislocation **UNLIKELY**



CLAVICLE FRACTURE?	Image CLAV1: Longitudinal on clavicle (must scan from SCJ to ACJ)
QUESTIONS	Question CLAV1: Bony cortex interrupted?
LIKELY	+ Yes: + Fracture is LIKELY
UNLIKELY	- No: - Fracture is UNLIKELY

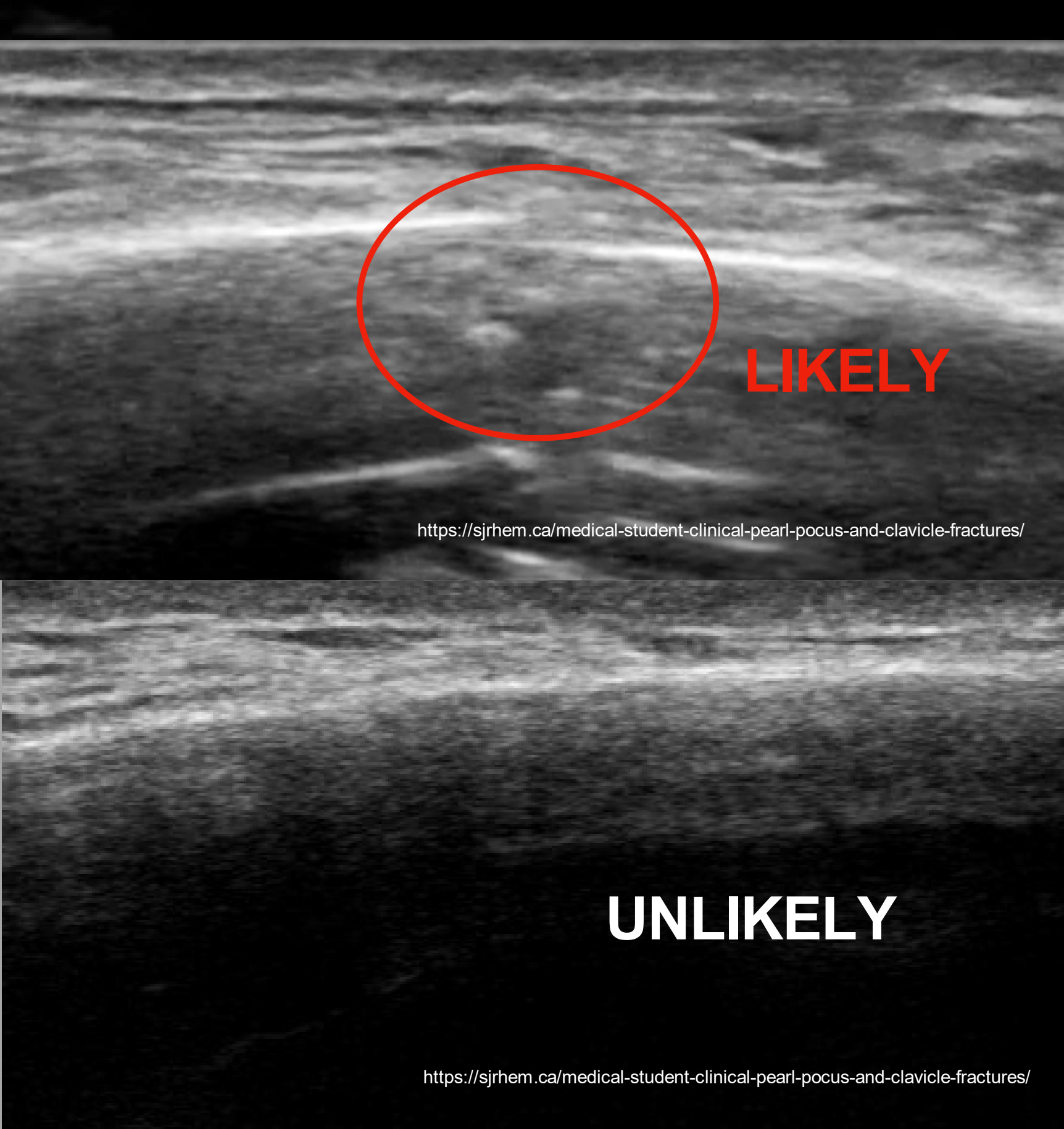


Image CLAV2:

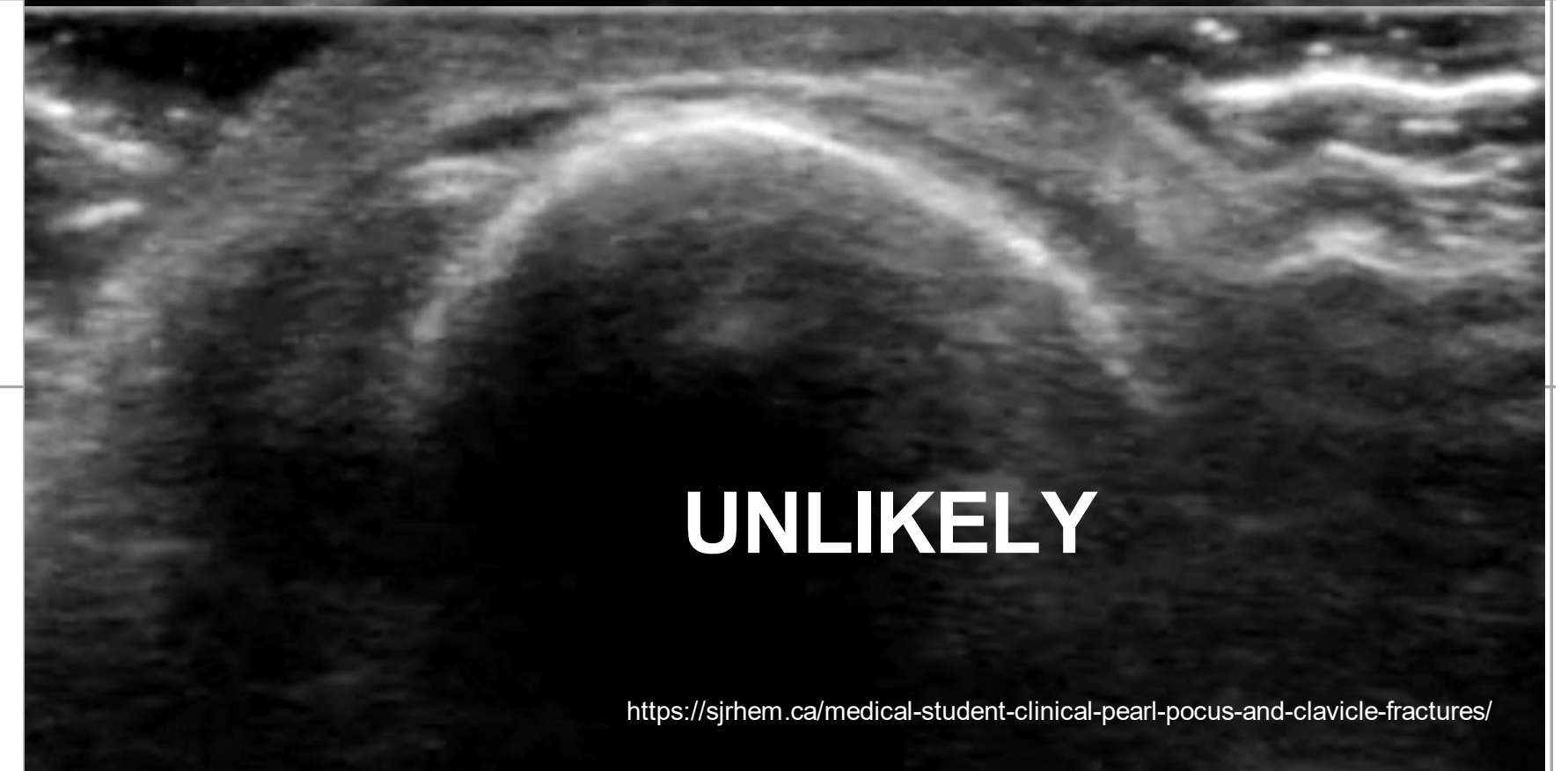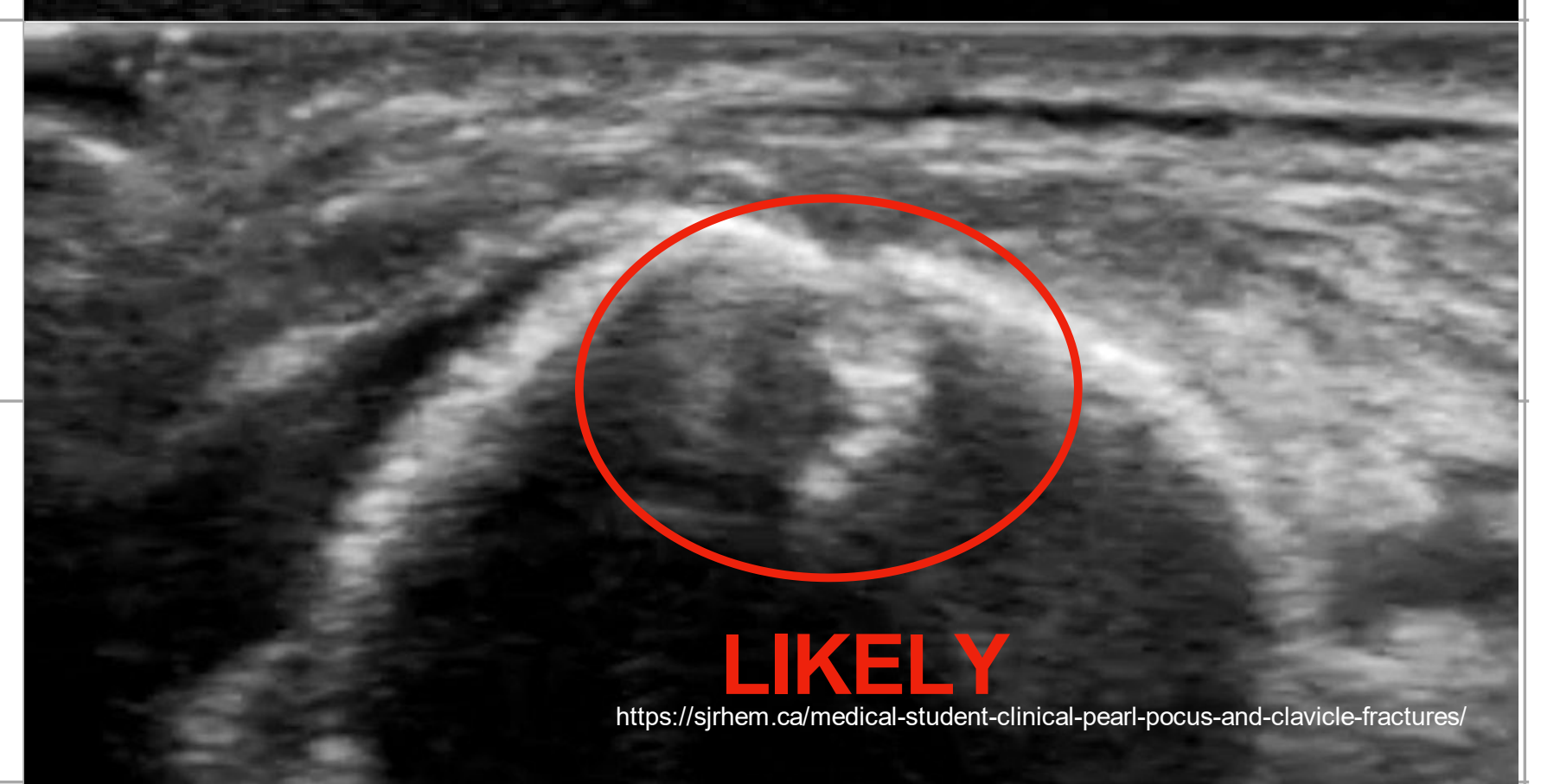
Transverse on clavicle
(must scan from SCJ to ACJ)

Question CLAV2:

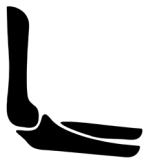Bony cortex interrupted?

- + Yes:
- + Fracture is **LIKELY**

- No:
- Fracture is **UNLIKELY**

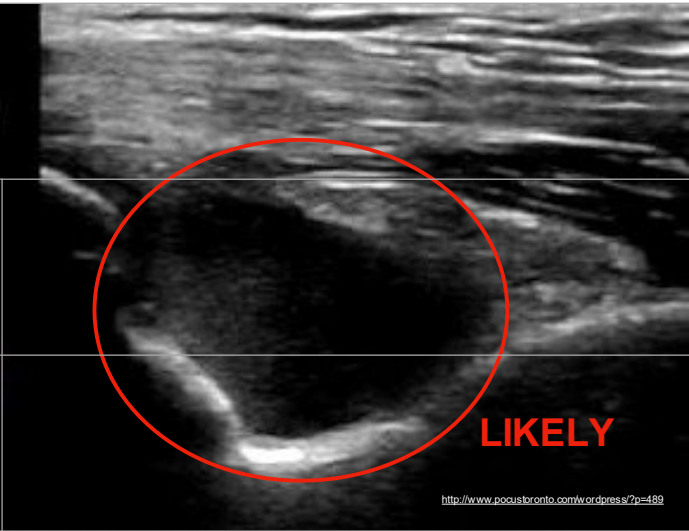
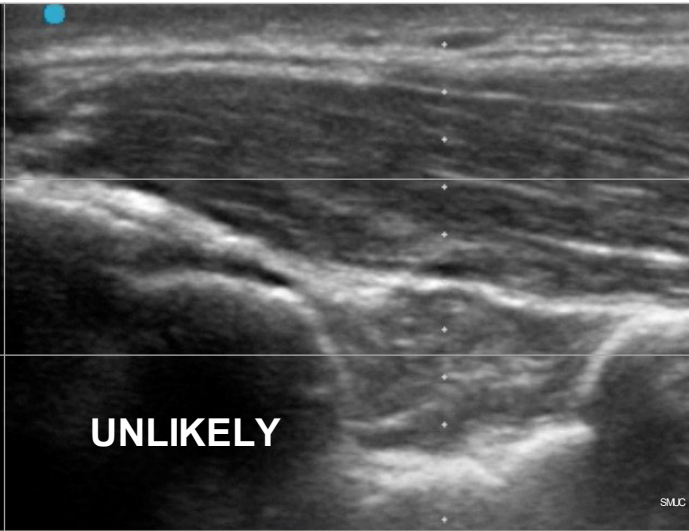
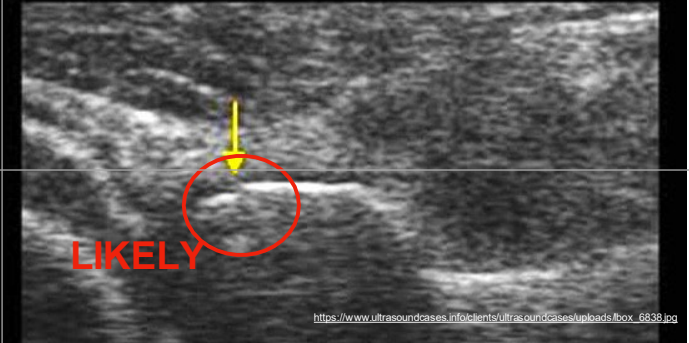
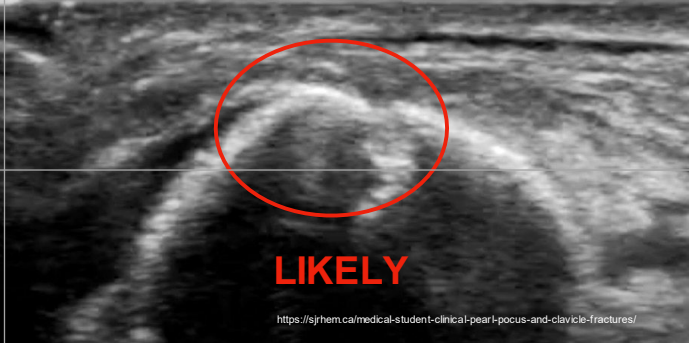


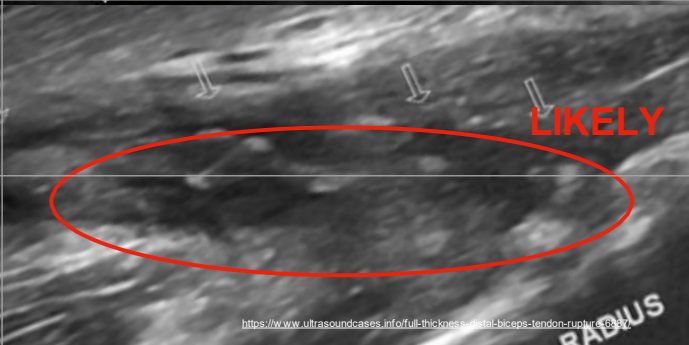
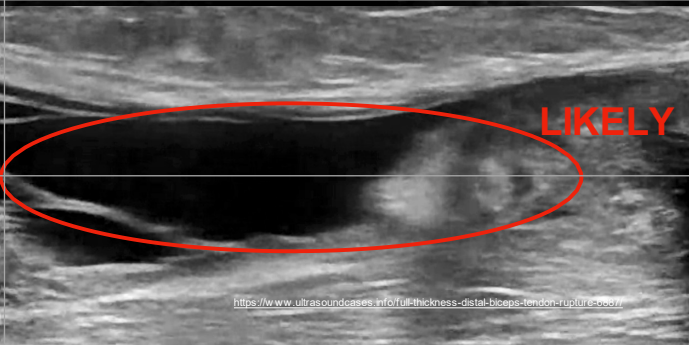



SIDELINE ULTRASOUND
CHART NOTE




SITE OF
PAIN

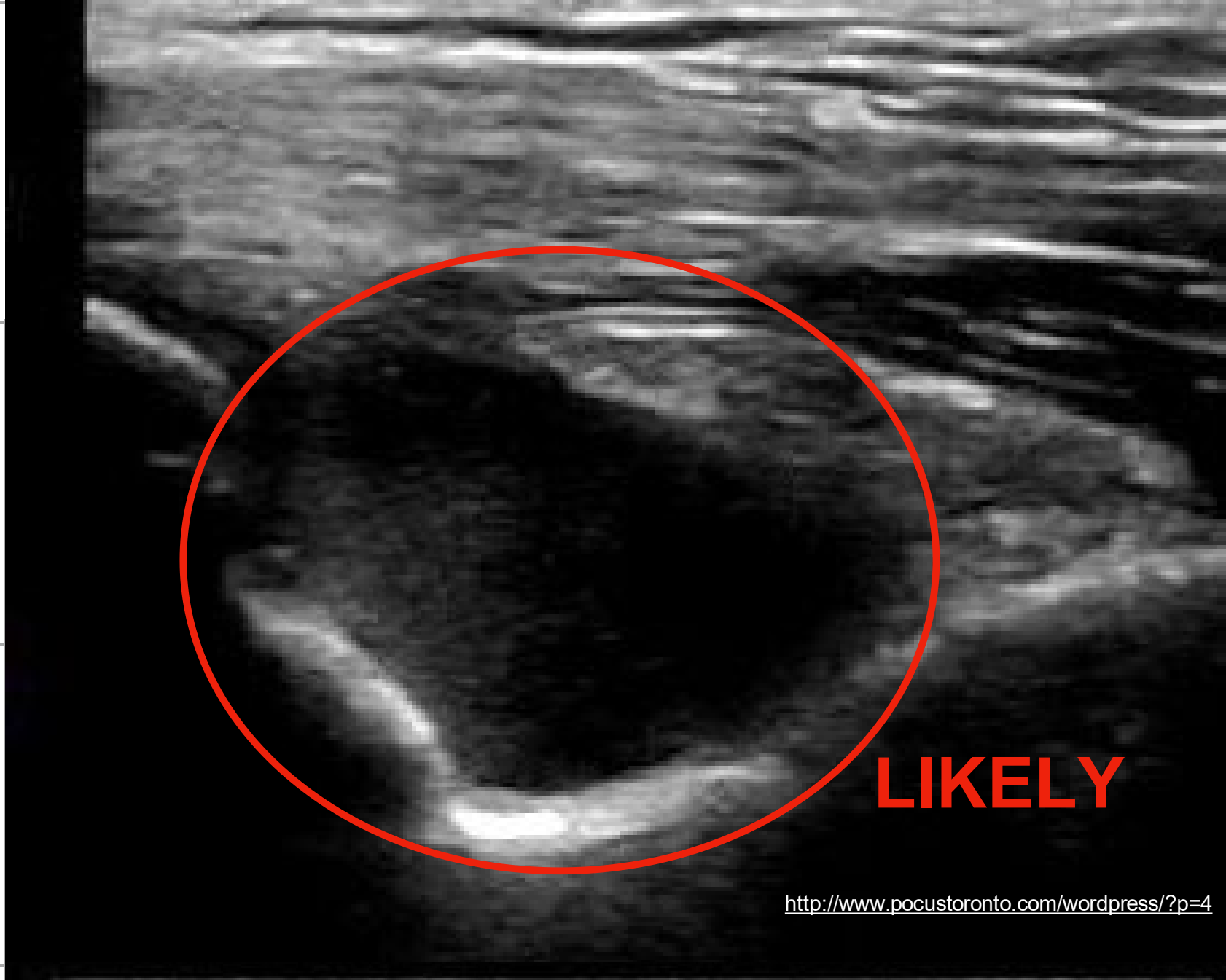
NAME: _____
DATE & TIME: _____
FINDINGS: _____
ACTION: _____


ELBOW JOINT EFFUSION? / HEMARTHROSIS?	Image ELBOW1: Longitudinal on posterior humerus at elbow		Question ELBOW1: Large black (effusion) or grey fluid (hemarthrosis) collection?	
	LIKELY + Yes large fluid collection: + Effusion/Hemarthrosis LIKELY		UNLIKELY - No large fluid collection: - Effusion/Hemarthrosis UNLIKELY	
RADIAL HEAD FRACTURE?	Image RADIUS1: Longitudinal on lateral radius/ radial head at elbow joint		Image RADIUS2: Trasnverse on lateral radius/ radial head at elbow joint	
QUESTIONS	Question RADIUS1: Bony cortex interrupted?		Question RADIUS2: Bony cortex interrupted?	
LIKELY	+ Yes: + Fracture is LIKELY		+ Yes: + Fracture is LIKELY	
UNLIKELY	- No - Fracture is UNLIKELY		- No - Fracture is UNLIKELY	
BICEPS RUPTURE? <i>ADVANCED ONLY!</i>	Image BICEPS1: Longitudinal on biceps at pronator window		Image BICEPS2: Longitudinal on anterior humerus at elbow	
QUESTIONS	Question BICEPS1: Biceps stump seen on radius?		Question BICEPS2: Large black (seroma) or grey fluid (hematoma) collection?	
LIKELY	+ Yes: + Rupture is LIKELY		+ Yes: + Rupture is LIKELY	
UNLIKELY	- No: - Rupture is UNLIKELY		- No: - Rupture is UNLIKELY	

SIDELINE ULTRASOUND CHART NOTE



SIT
P

ELBOW JOINT EFFUSION? / HEMARTHROSIS?	Image ELBOW1: Longitudinal on posterior humerus at elbow	
	LIKELY + Yes large fluid collection: + Effusion/Hemarthrosis LIKELY	

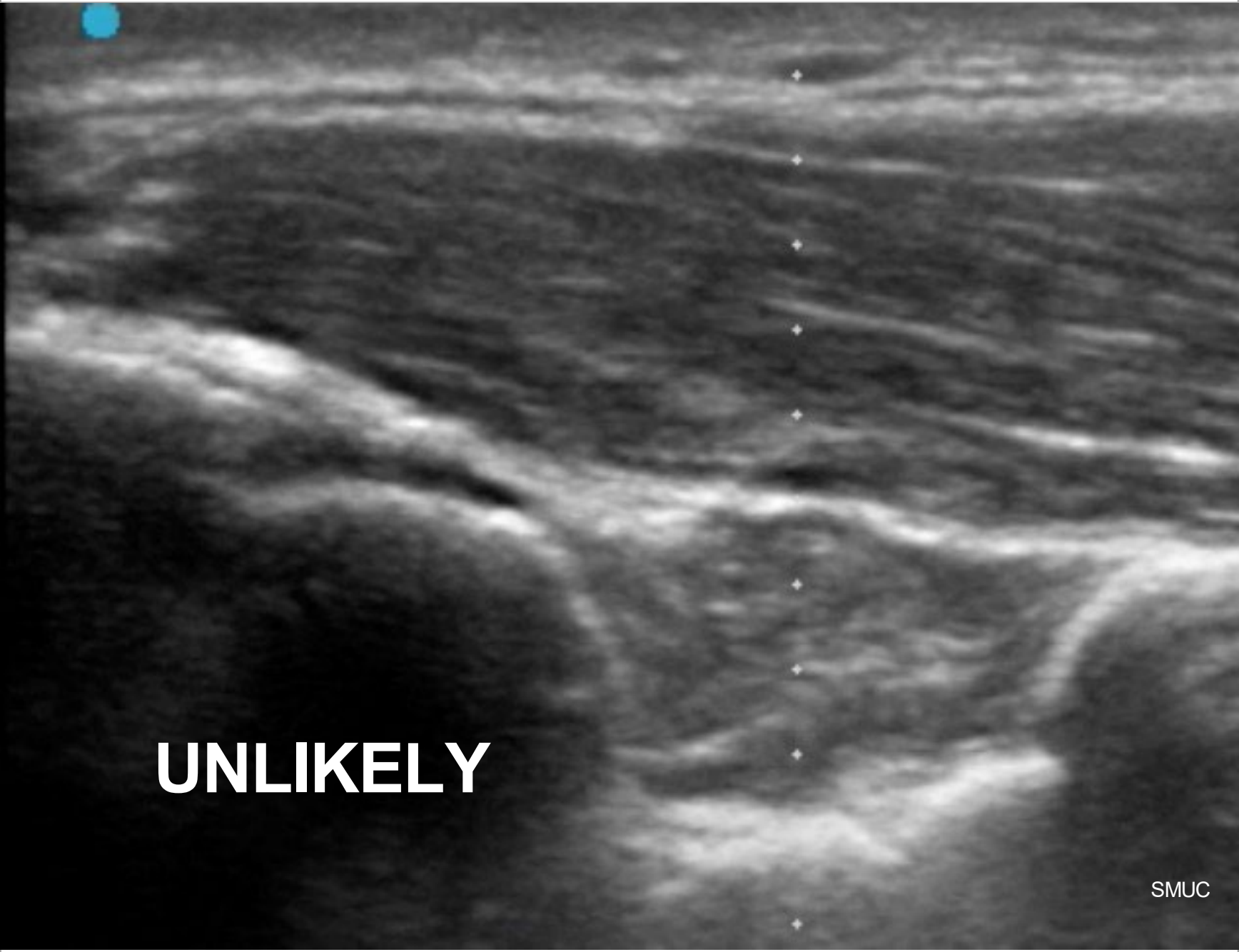


SITE OF
PAIN

NAME: _____
DATE & TIME: _____
FINDINGS: _____
ACTION: _____

Question ELBOW1:
Large black (effusion) or grey fluid (hemarthrosis) collection?

- UNLIKELY**
- No large fluid collection:
 - Effusion/Hemarthrosis UNLIKELY



RADIAL HEAD FRACTURE?	Image RADIUS1: Longitudinal on lateral radius/ radial head at elbow joint
QUESTIONS	Question RADIUS1: Bony cortex interrupted?
LIKELY	+ Yes: + Fracture is LIKELY
UNLIKELY	- No - Fracture is UNLIKELY

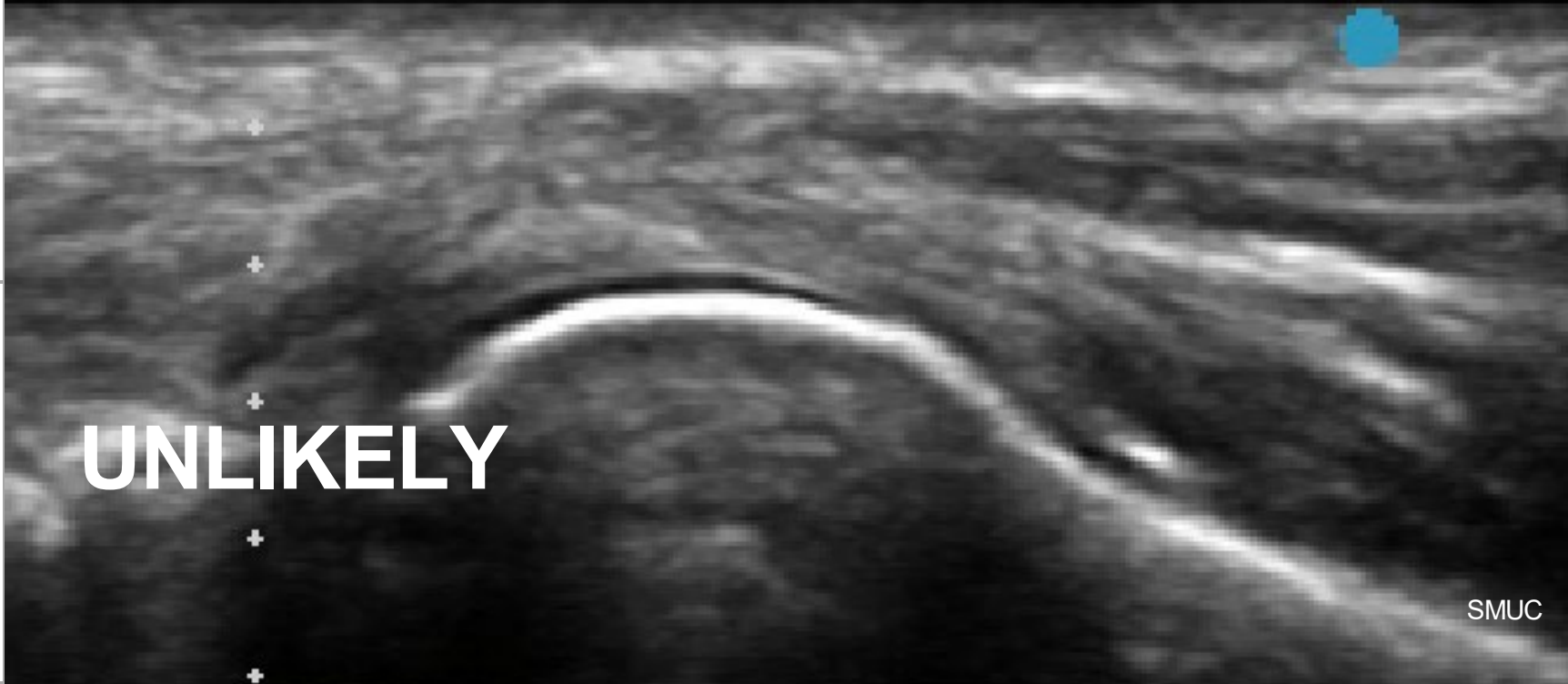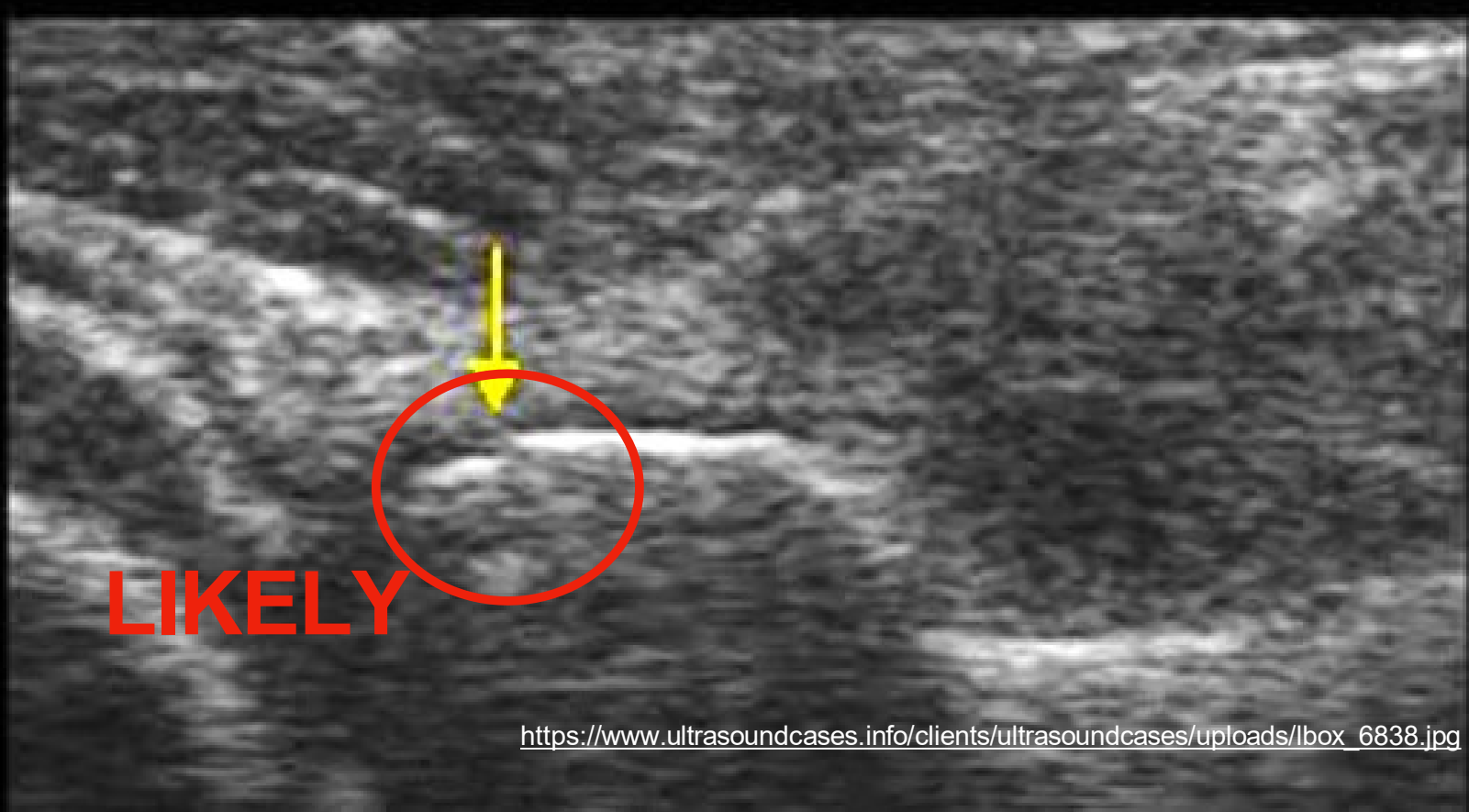


Image RADIUS2:

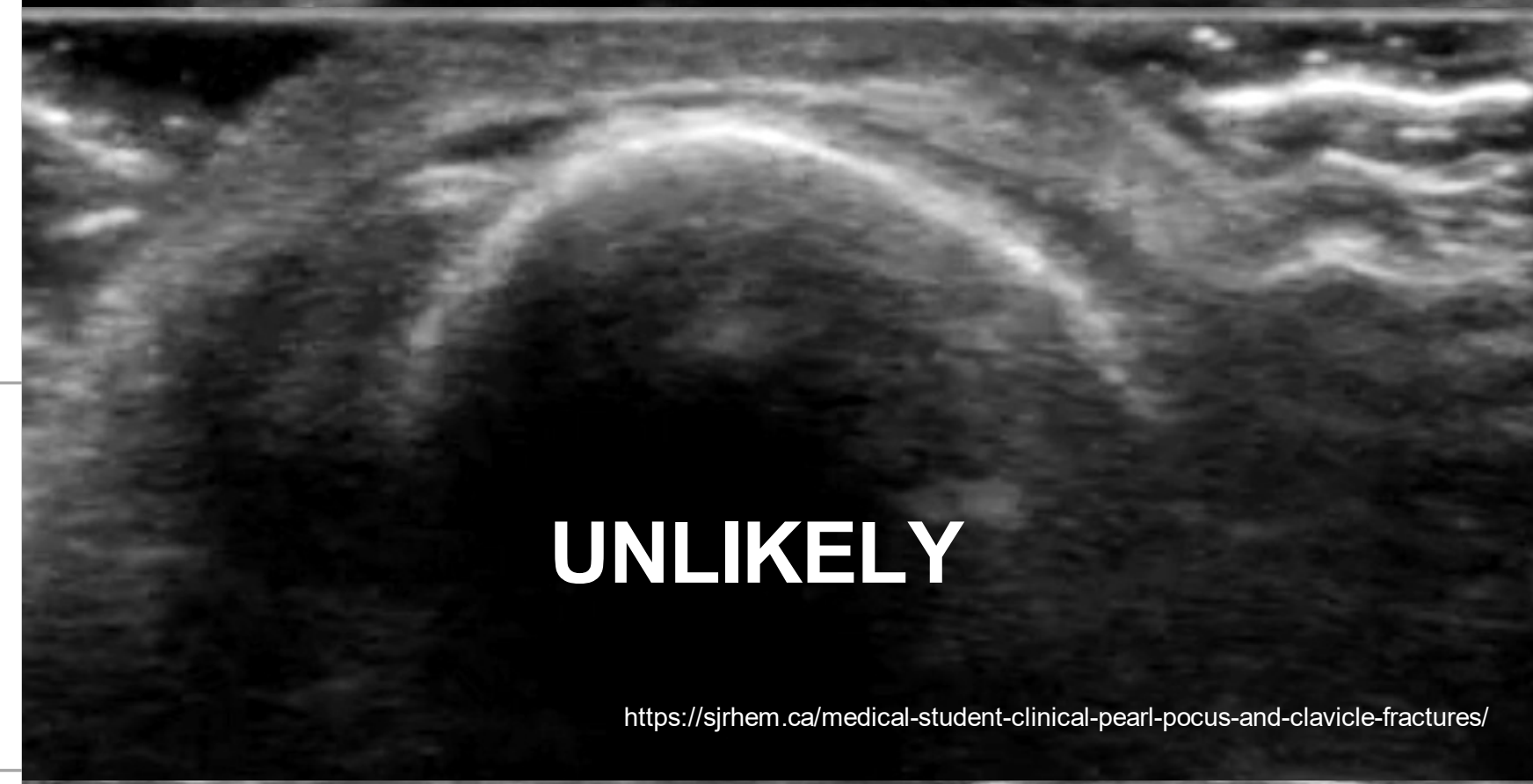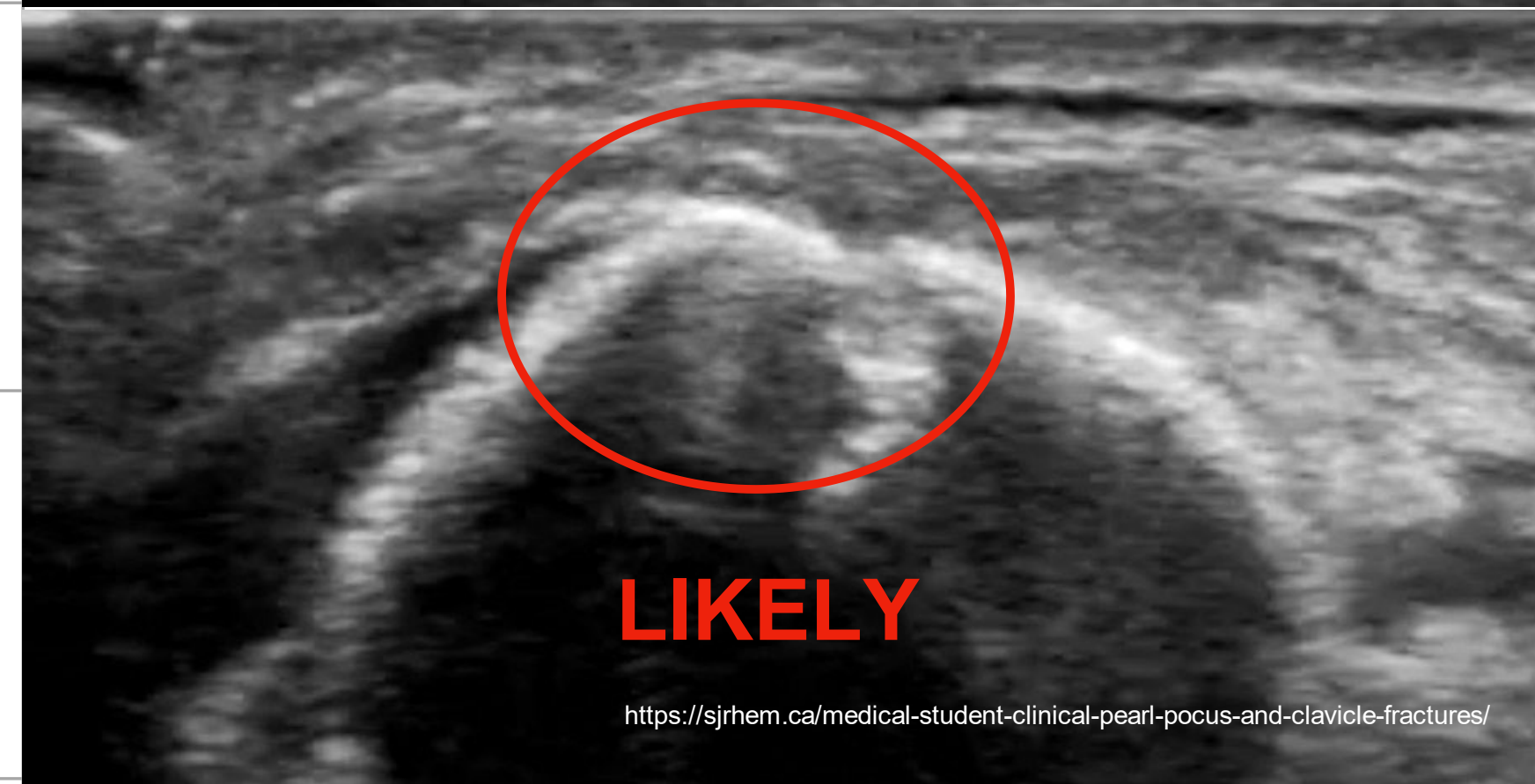
Trasnverse on lateral radius/
radial head at elbow joint

Question RADIUS2:

Bony cortex interrupted?

- + Yes:
- + Fracture is LIKELY

- No
- Fracture is UNLIKELY



BICEPS RUPTURE? <i><u>ADVANCED ONLY!</u></i>	Image BICEPS1: Longitudinal on biceps at pronator window
QUESTIONS	Question BICEPS1: Biceps stump seen on radius?
LIKELY	+ Yes: + Rupture is LIKELY
UNLIKELY	- No: - Rupture is UNLIKELY

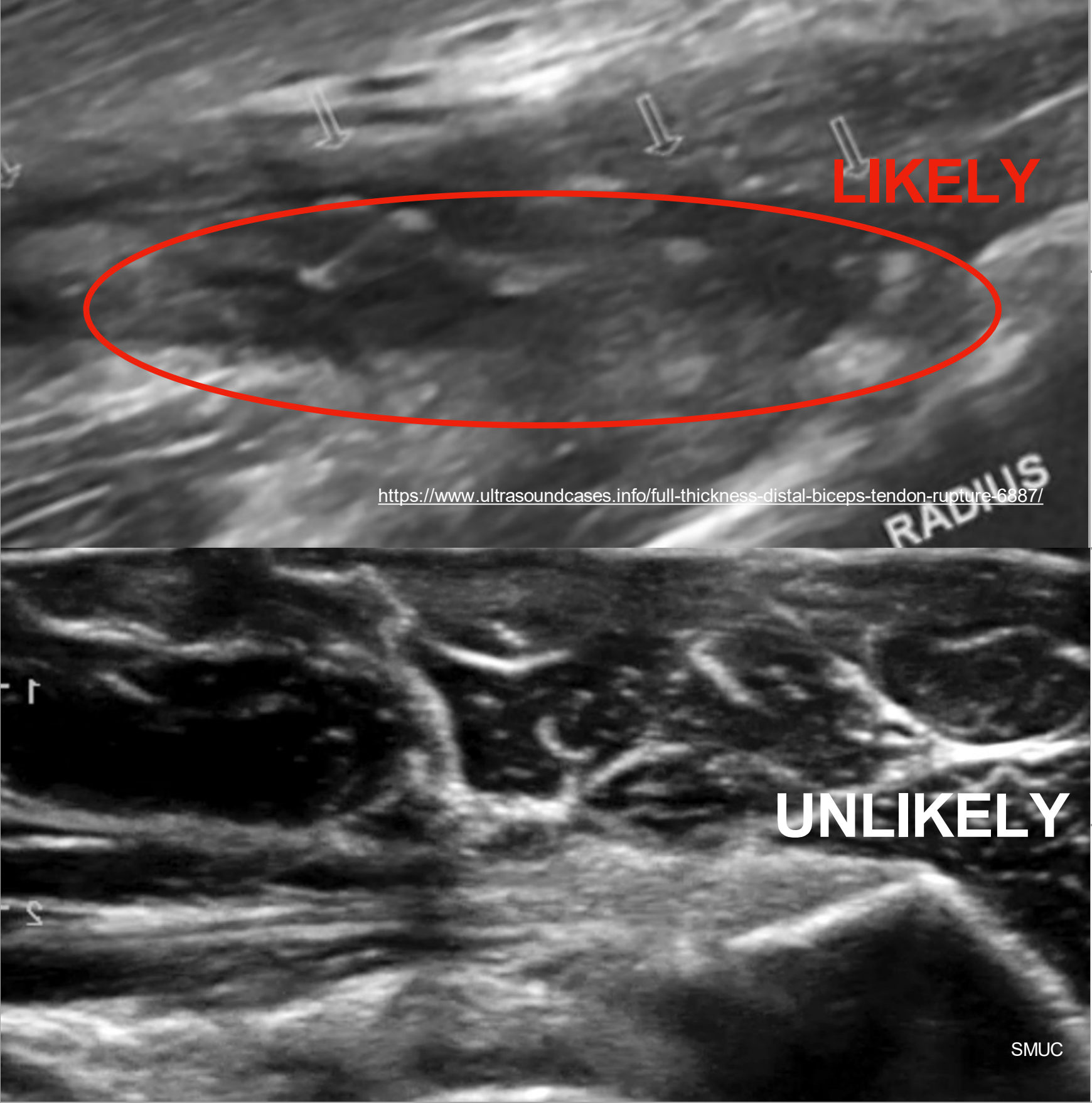


Image BICEPS2:

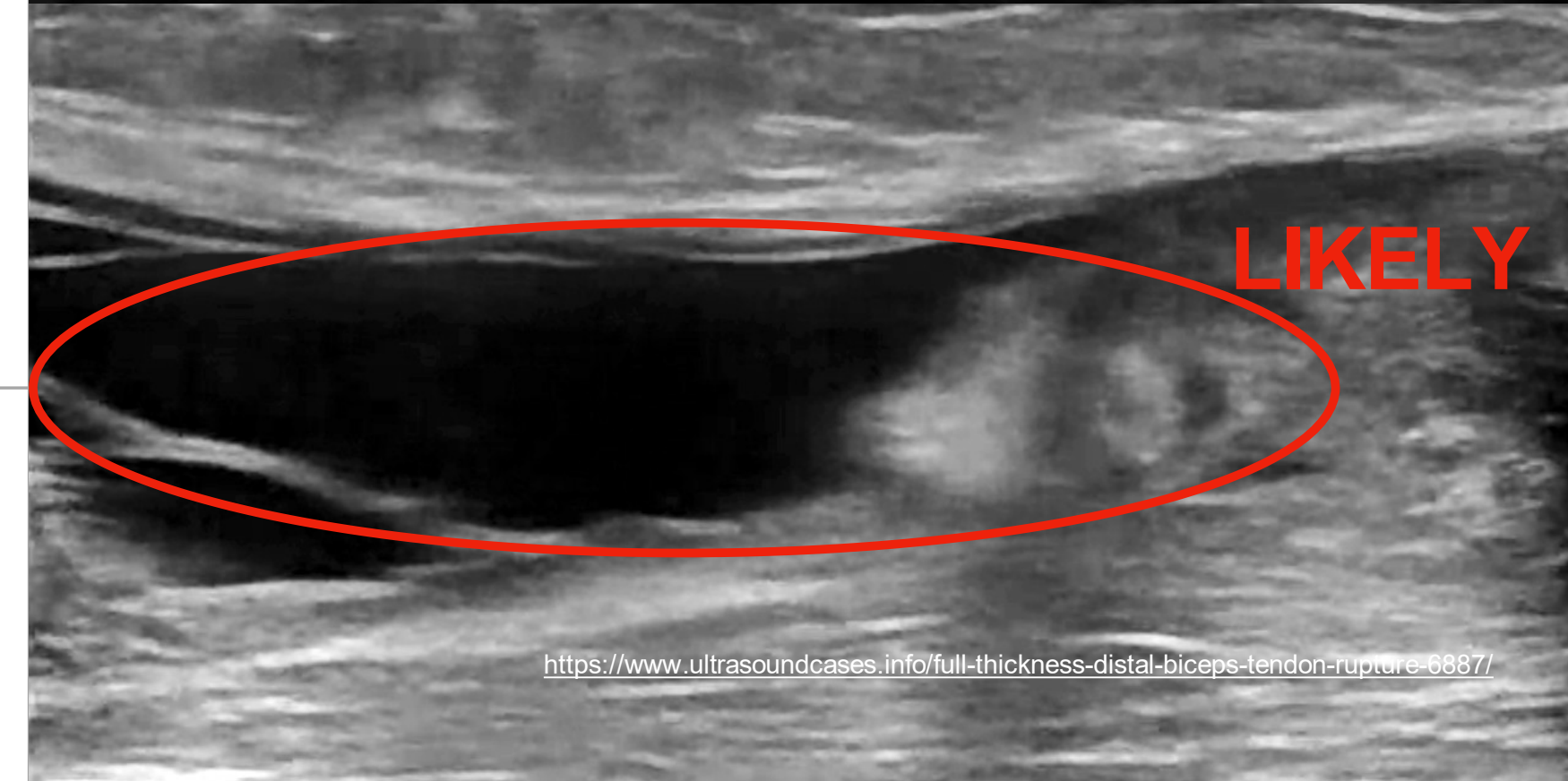
Longitudinal on anterior humerus
at elbow

Question BICEPS2:

Large black (seroma) or grey
fluid (hematoma) collection?

- + Yes:
- + Rupture is **LIKELY**

- No:
- Rupture is **UNLIKELY**

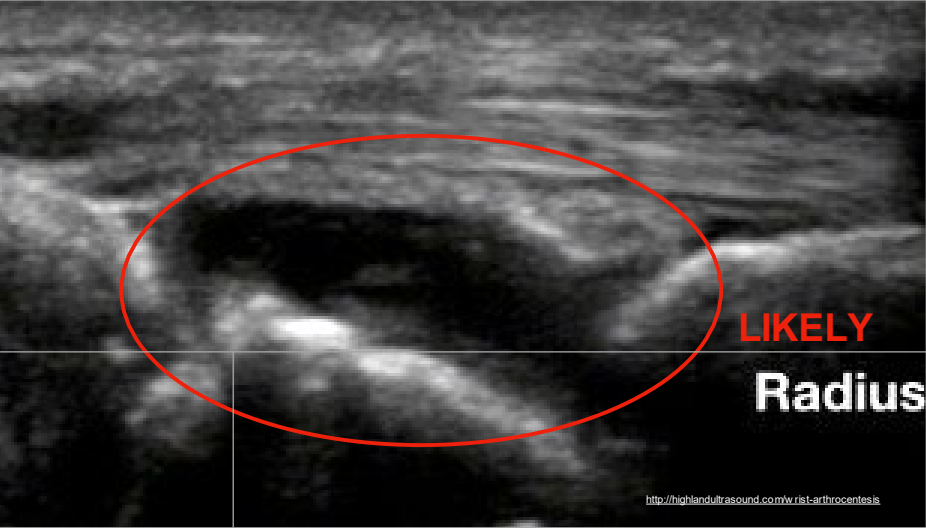


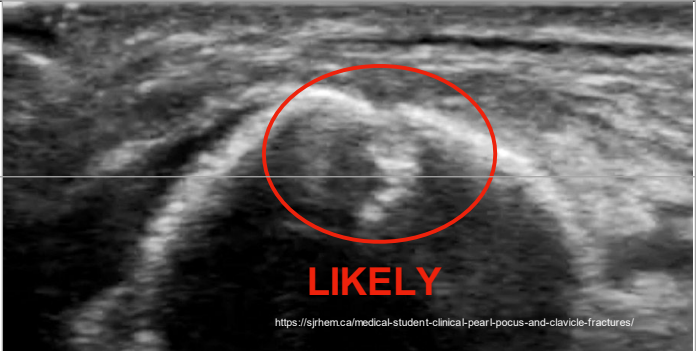
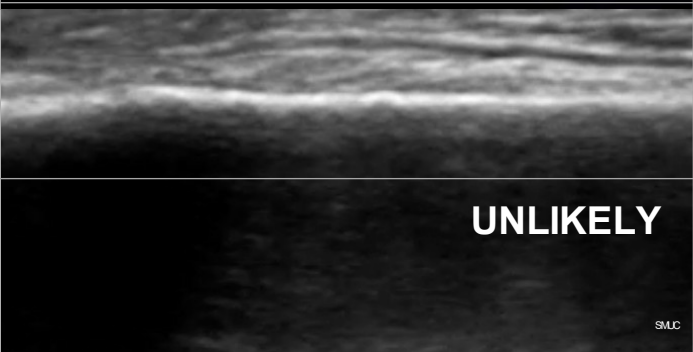



SIDELINE ULTRASOUND
CHART NOTE

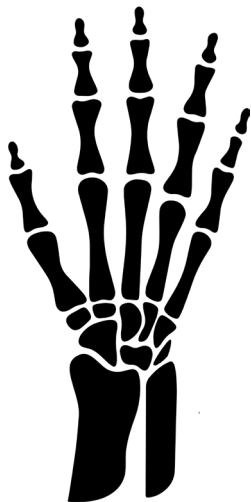

SITE OF
PAIN


NAME: _____
DATE & TIME: _____
FINDINGS: _____
ACTION: _____

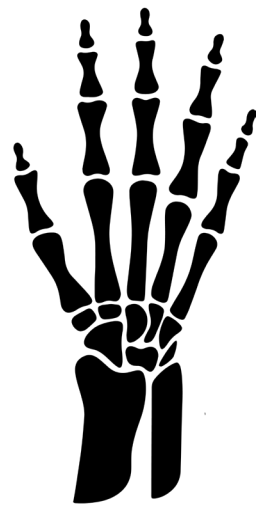WRIST JOINT EFFUSION? / HEMARTHROSIS?	Image WRIST1: Longitudinal on dorsal radius at scaphoid		Question WRIST1: Large black (effusion) or grey fluid (hemarthrosis) collection?	
	LIKELY + Yes large fluid collection: + Effusion/ Hemarthrosis LIKELY		UNLIKELY - No large fluid collection: - Effusion/ Hemarthrosis UNLIKELY	
DISTAL RADIUS FRACTURE?	Image RADIUS1: Longitudinal on dorsal radius over area of TTP / swelling		Image RADIUS2: Transverse on dorsal radius over area of TTP / swelling	
QUESTIONS	Question RADIUS1: Bony cortex interrupted?		Question RADIUS2: Bony cortex interrupted?	
LIKELY	+ Yes? + Fracture is LIKELY		+ Yes? + Fracture is LIKELY	
UNLIKELY	- No - Fracture is UNLIKELY		- No - Fracture is UNLIKELY	

SIDELINE ULTRASOUND CHART NOTE



SITE
PA

WRIST JOINT EFFUSION? / HEMARTHROSIS?	Image WRIST1: Longitudinal on dorsal radius at scaphoid	
	LIKELY + Yes large fluid collection:	 <p>LIKELY Radius</p>
	+ Effusion/ Hemarthrosis LIKELY	



SITE OF
PAIN

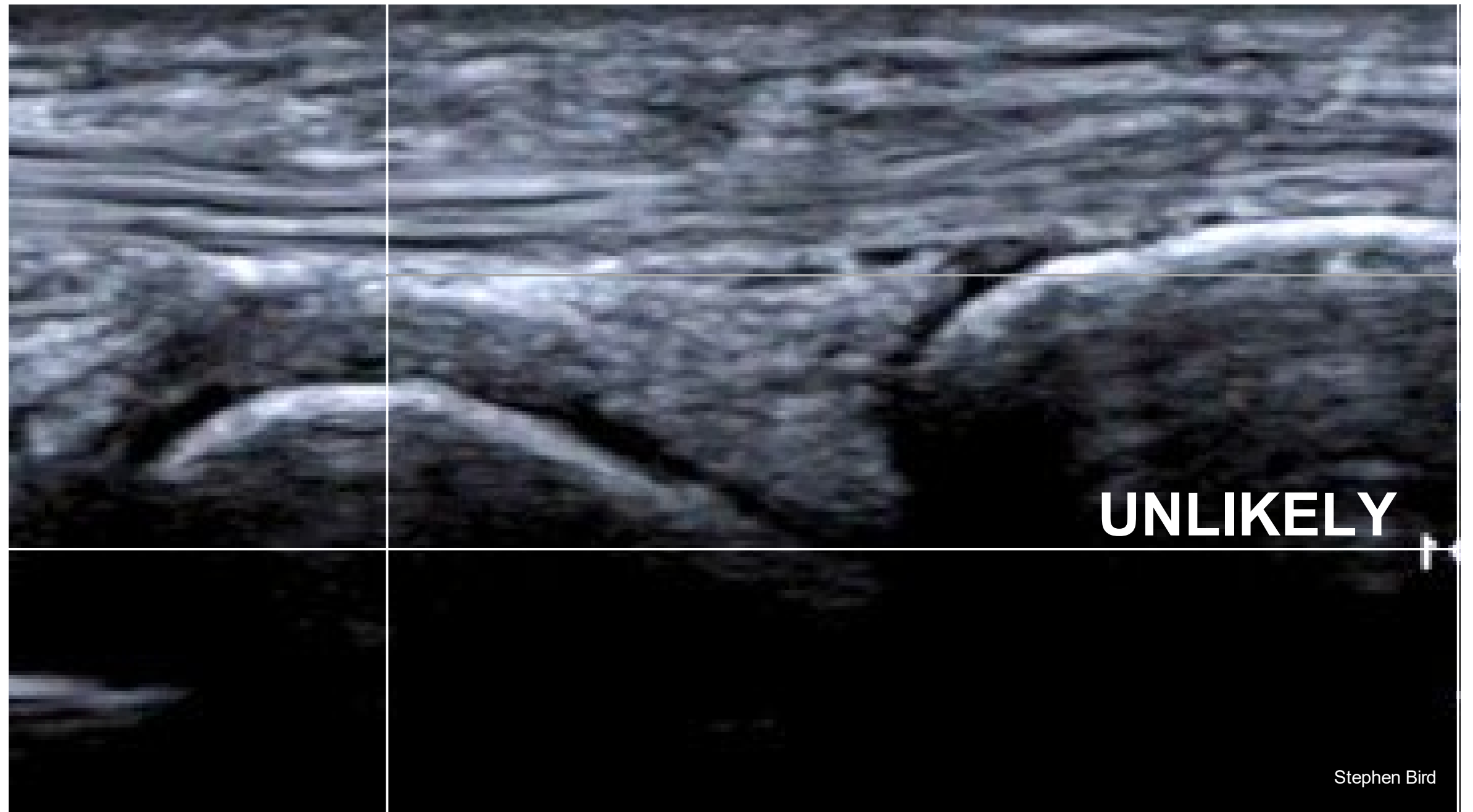
NAME: _____
DATE & TIME: _____
FINDINGS: _____
ACTION: _____

Question WRIST1:

Large black (effusion) or grey fluid (hemarthrosis) collection?

UNLIKELY

- No large fluid collection:
- Effusion/
Hemarthrosis
UNLIKELY




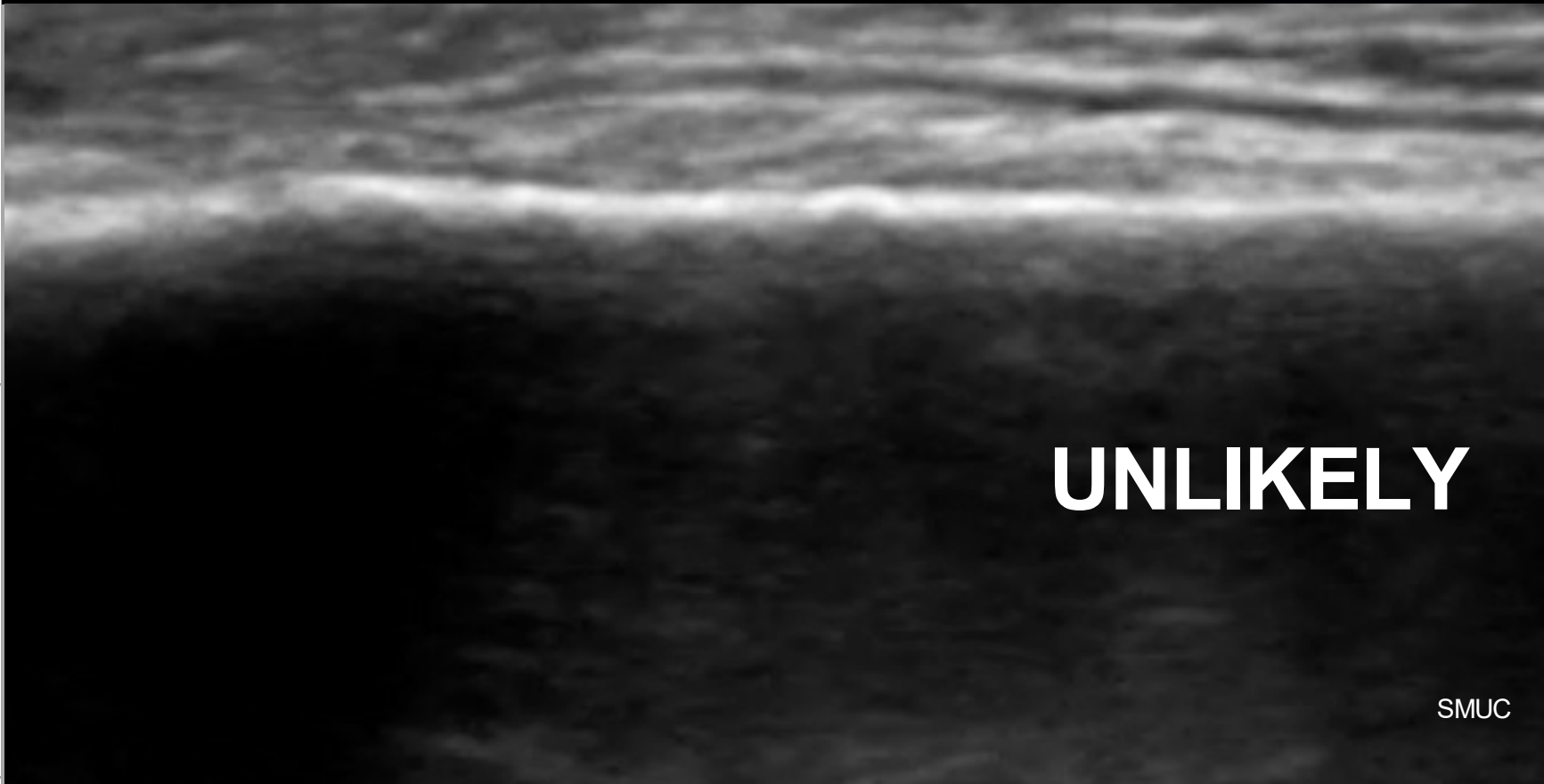
DISTAL RADIUS FRACTURE?	Image RADIUS1: Longitudinal on dorsal radius over area of TTP / swelling	 <p>LIKELY</p> <p>SMUC</p>
QUESTIONS	Question RADIUS1: Bony cortex interrupted?	
LIKELY	+ Yes? + Fracture is LIKELY	 <p>UNLIKELY</p> <p>SMUC</p>
UNLIKELY	- No - Fracture is UNLIKELY	

Image RADIUS2:

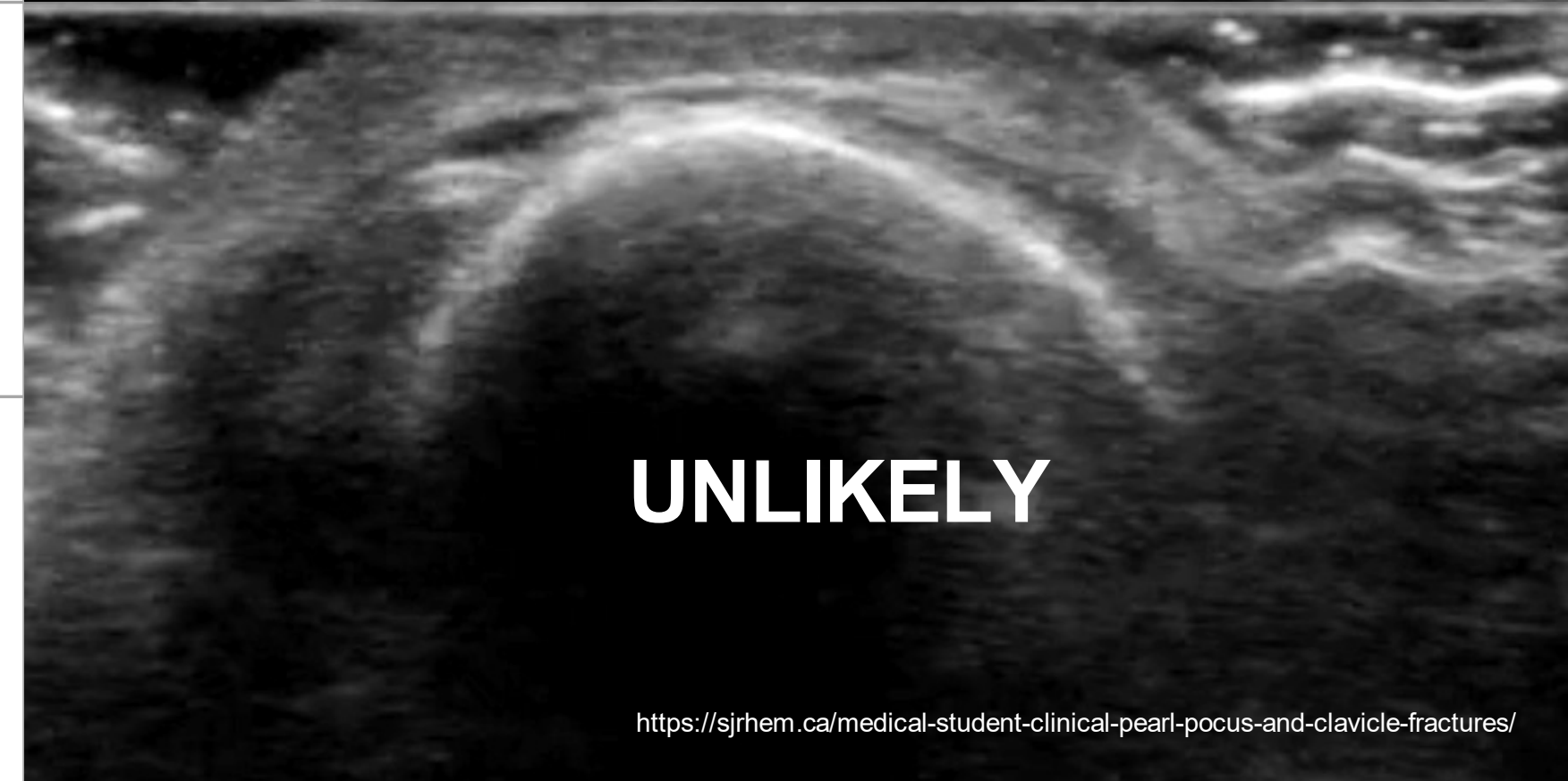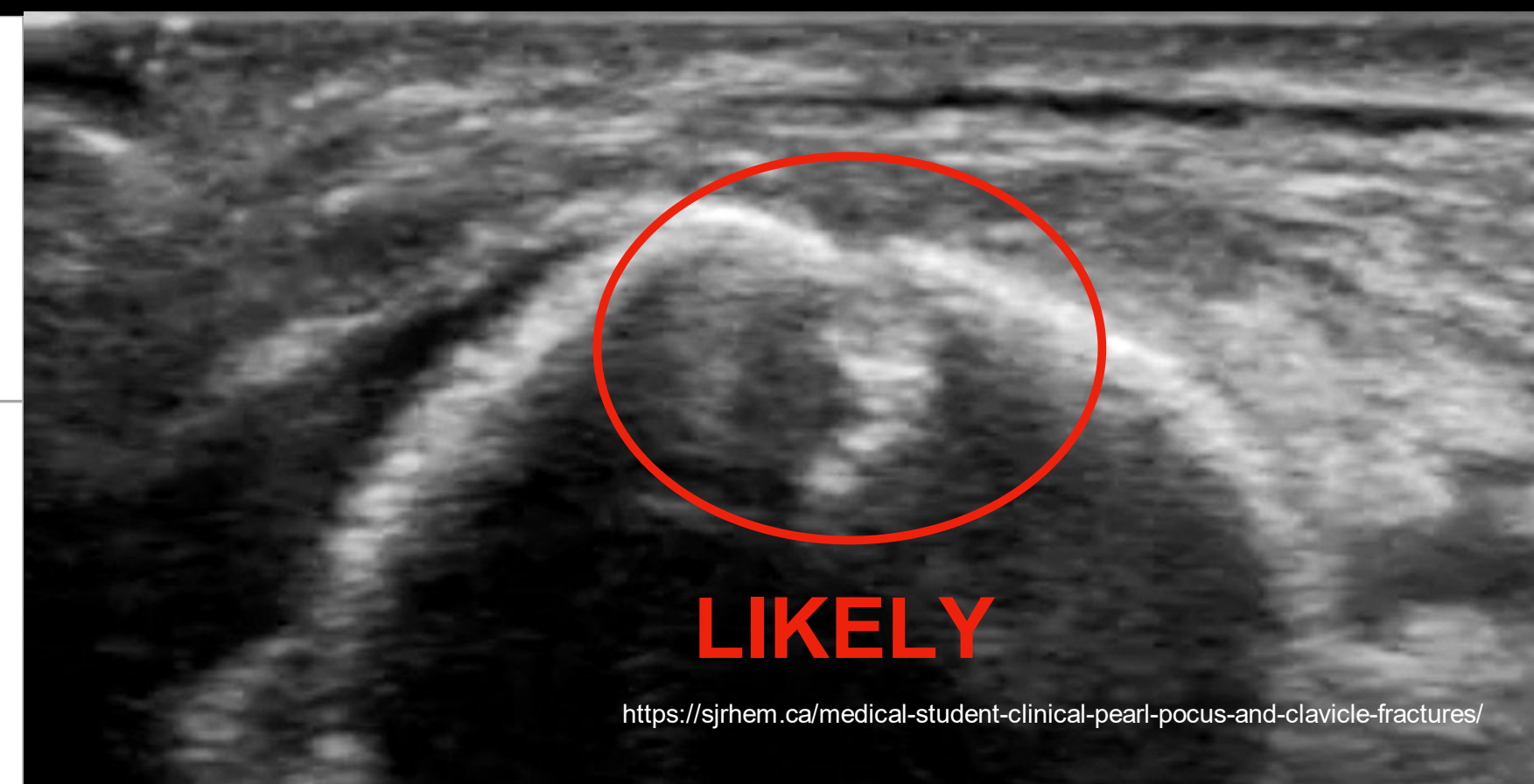
Transverse on dorsal radius over
area of TTP / swelling

Question RADIUS2:

Bony cortex interrupted?

- + Yes?
- + Fracture is **LIKELY**

- No
- Fracture is **UNLIKELY**

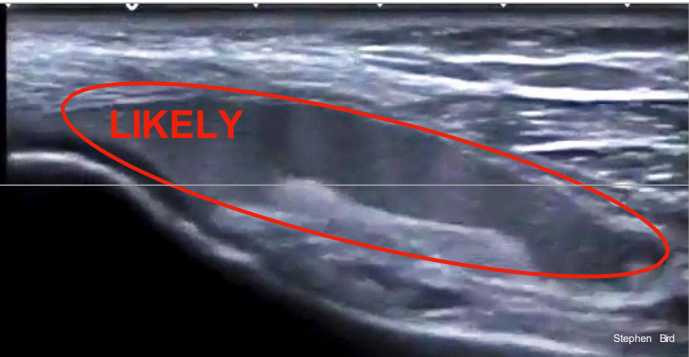
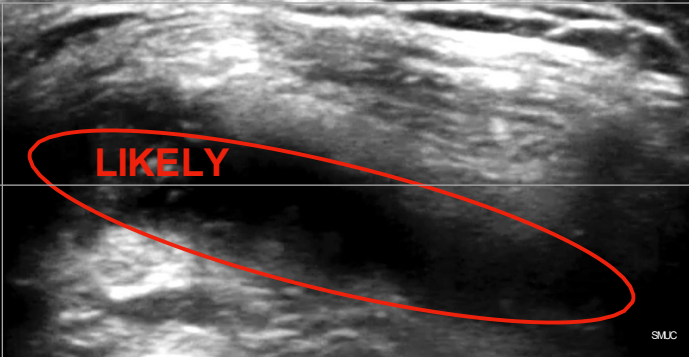
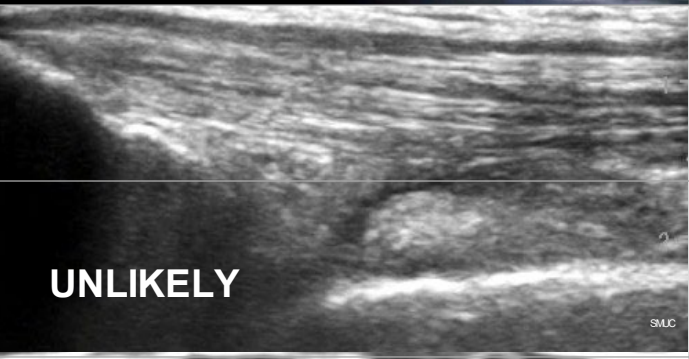
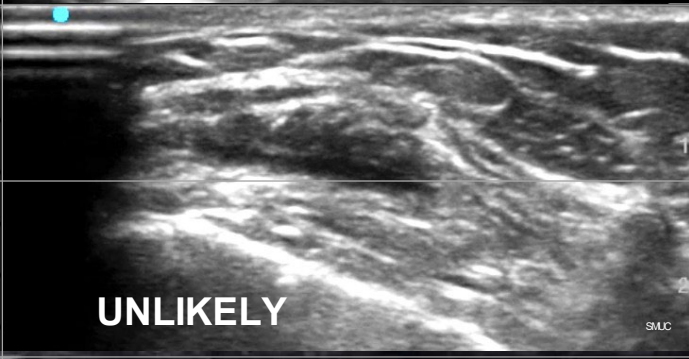
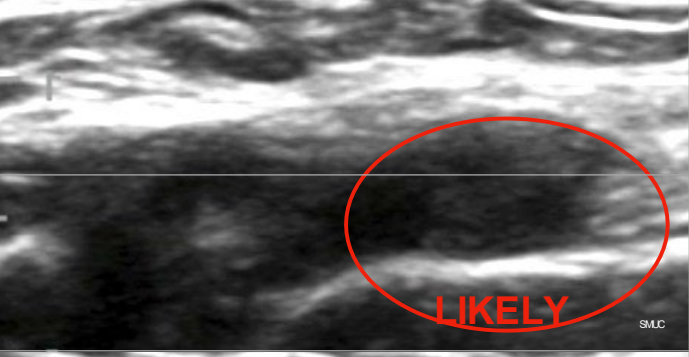
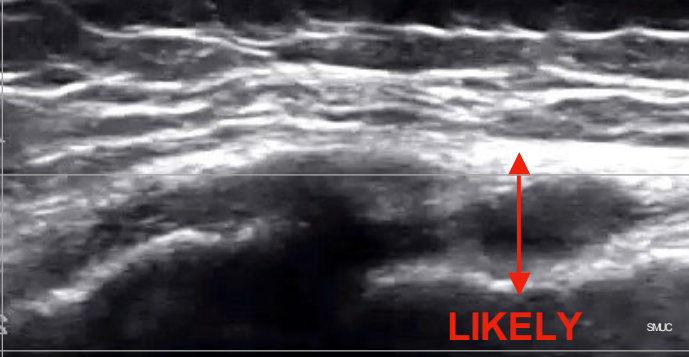
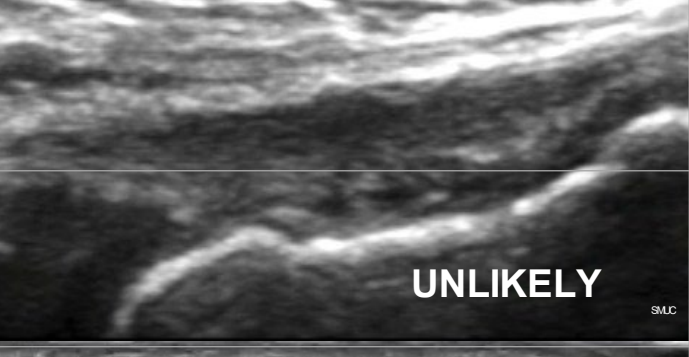

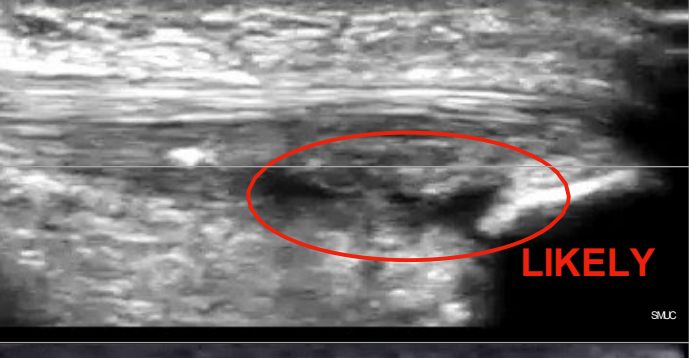
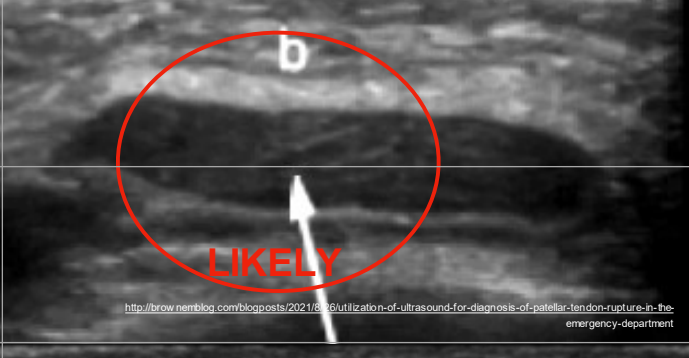

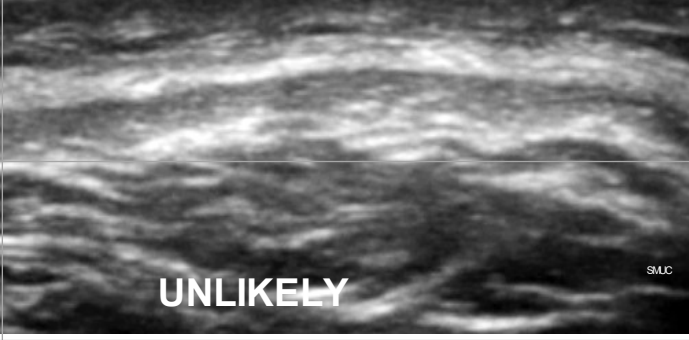




SIDELINE ULTRASOUND
CHART NOTE



SITE OF
PAIN

NAME: _____
DATE & TIME: _____
FINDINGS: _____
ACTION: _____

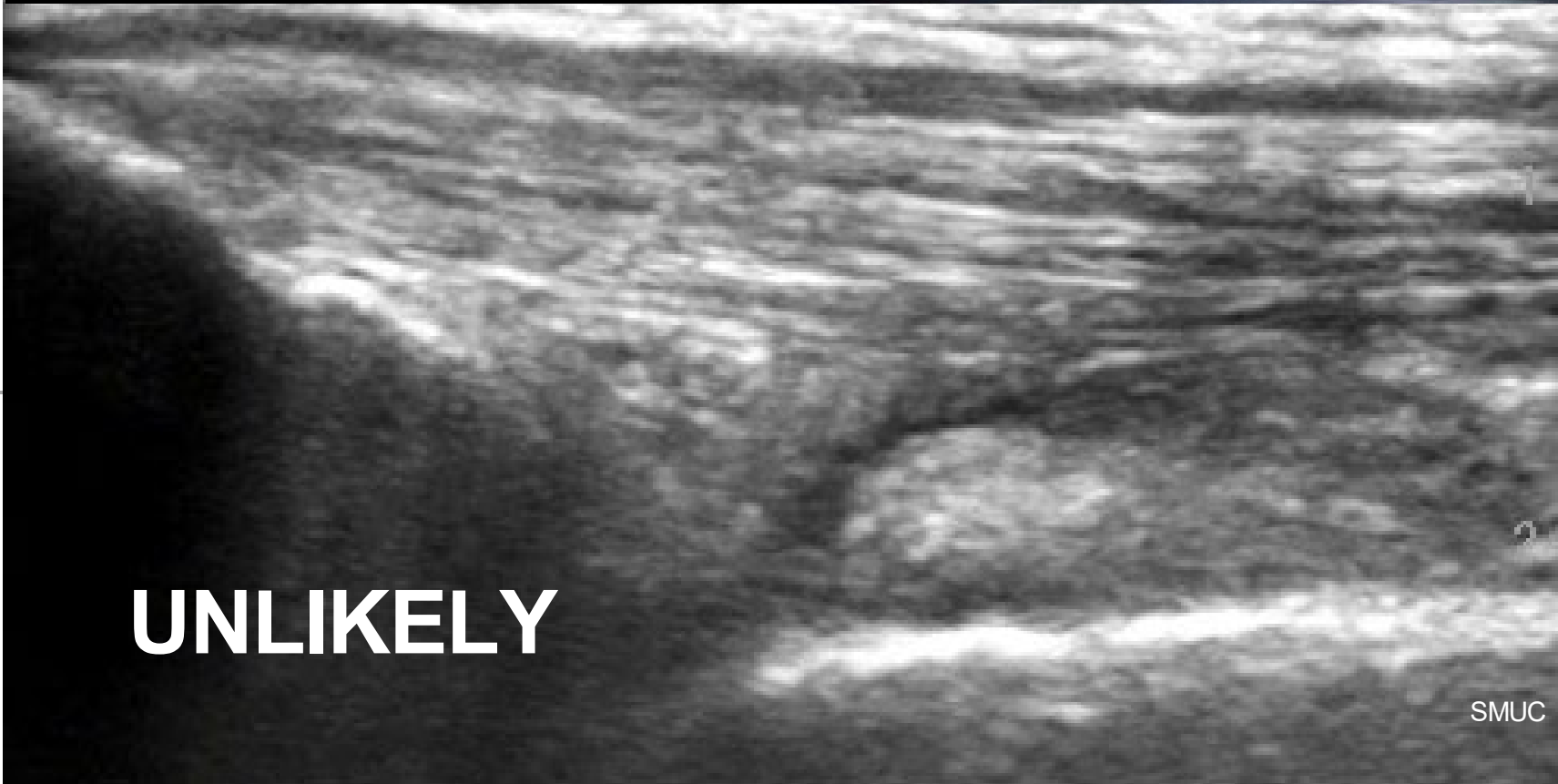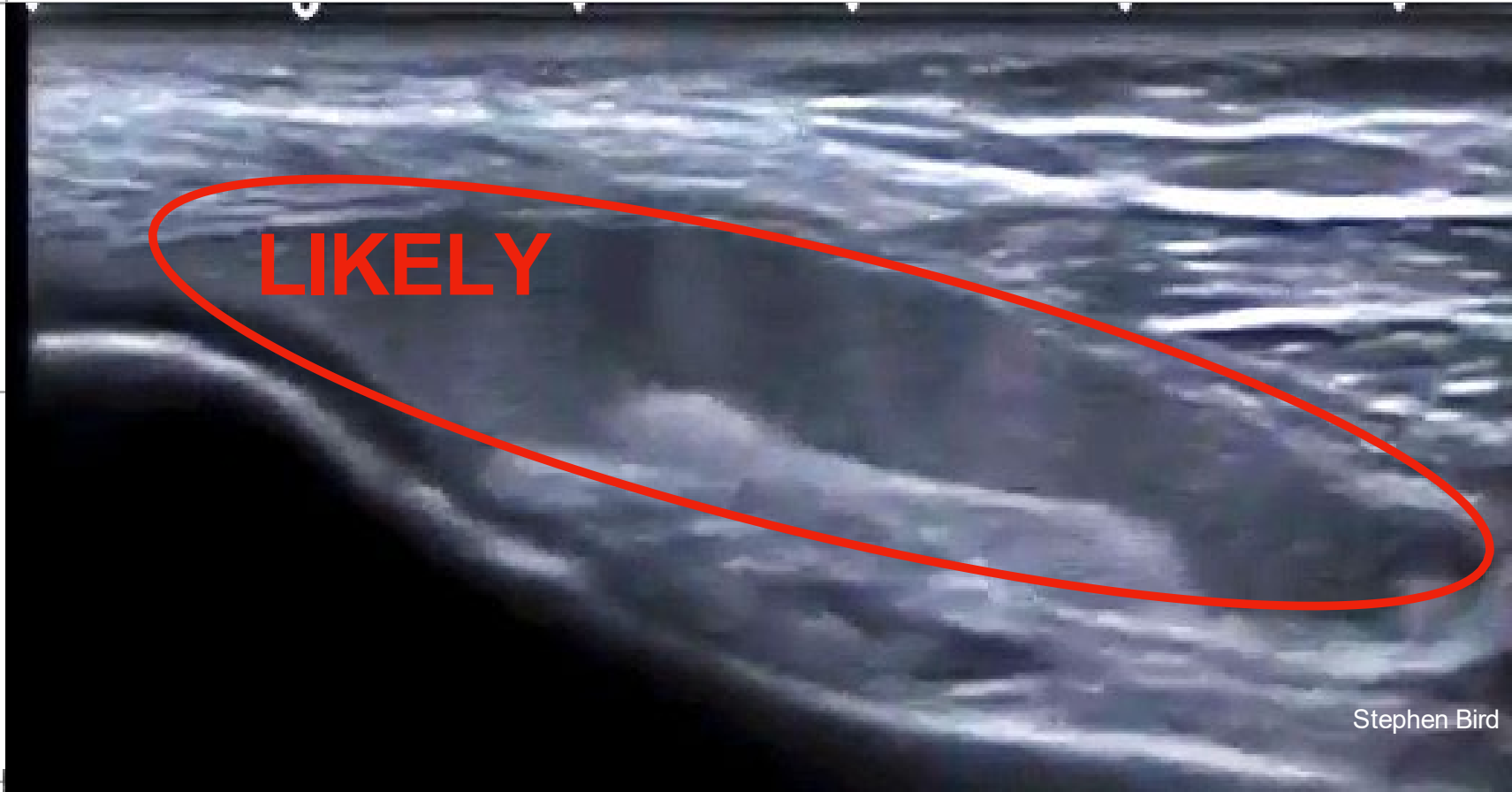KNEE JOINT EFFUSION? / HEMARTHROSIS?	Image KNEE1: Longitudinal on anterior femur at patella		Image KNEE2: Transverse on anterior femur at patella	
QUESTIONS	Question KNEE1: Large black (effusion) or grey fluid (hemarthrosis) collection?		Question KNEE2: Large black (effusion) or grey fluid (hemarthrosis) collection?	
LIKELY	+ Yes large fluid collection: + Effusion/Hemarthrosis LIKELY		+ Yes large fluid collection: + Effusion/Hemarthrosis LIKELY	
UNLIKELY	- No large fluid collection: - Effusion/Hemarthrosis UNLIKELY		- No large fluid collection: - Effusion/Hemarthrosis UNLIKELY	
MCL TEAR?	Image MCL1: Longitudinal on medial femur at proximal to knee joint		Image MCL2: Longitudinal on medial femur at knee joint	
QUESTIONS	Question MCL1: Is MCL absent?		Question MCL2: Is MCL thicker than 5mm?	
LIKELY	+ Yes: + MCL avulsion is LIKELY		+ Yes: + Sprain is MORE LIKELY if MCL is thicker than 6mm	
UNLIKELY	- No - MCL avulsion is UNLIKELY		- No - Sprain is LESS LIKELY if MCL is thinner than 3 mm	
PATELLAR / QUADS TENDON TEAR	Image PAT1 / QUAD1: Longitudinal on entire Patellar/ Quads tendon		Image PAT2 / QUAD2: Transverse on Patellar/Quads tendons at Patella	
QUESTIONS	Question PAT1 / QUAD1: Is Patellar/Quads tendon absent?		Question PAT2 / QUAD2: Are there black or grey areas within the tendon?	
LIKELY	+ Yes: + Total rupture LIKELY		+ Yes: + Partial rupture is LIKELY	
UNLIKELY	- No: - Total rupture UNLIKELY		- No: - Partial rupture is UNLIKELY	

SIDELINE ULTRASOUND CHART NOTE



SITE
PA

KNEE JOINT EFFUSION? / HEMARTHROSIS?	Image KNEE1: Longitudinal on anterior femur at patella
QUESTIONS	Question KNEE1: Large black (effusion) or grey fluid (hemarthrosis) collection?
LIKELY	<ul style="list-style-type: none">+ Yes large fluid collection:+ Effusion/Hemarthrosis LIKELY
UNLIKELY	<ul style="list-style-type: none">- No large fluid collection:- Effusion/Hemarthrosis UNLIKELY





SITE OF
PAIN

NAME: _____
DATE & TIME: _____
FINDINGS: _____
ACTION: _____

Image KNEE2:

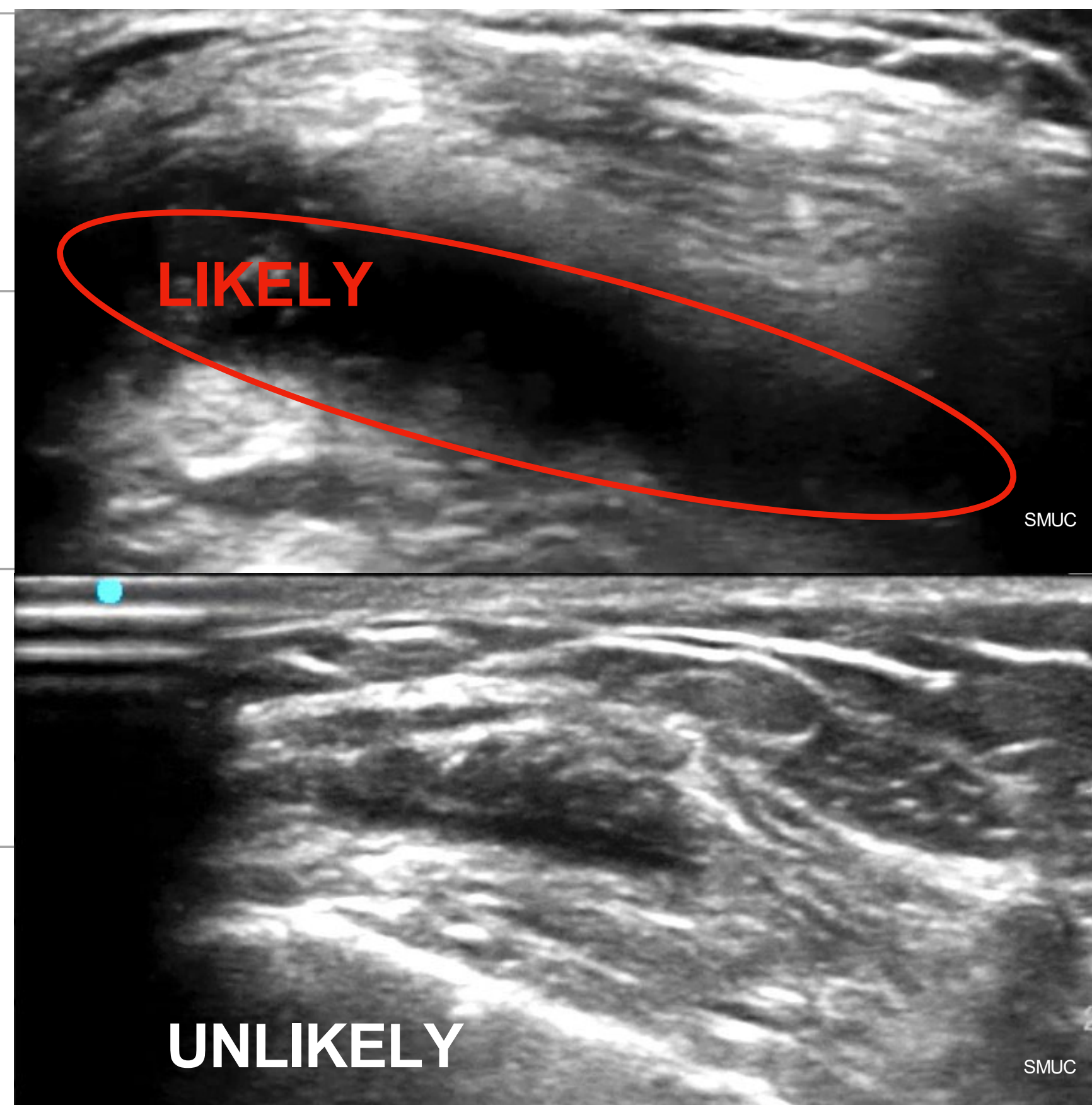
Transverse on anterior femur at
patella

Question KNEE2:

Large black (effusion) or grey
fluid (hemarthrosis) collection?

- + Yes large fluid collection:
- + Effusion/Hemarthrosis **LIKELY**

- No large fluid collection:
- Effusion/Hemarthrosis **UNLIKELY**



MCL TEAR?	Image MCL1: Longitudinal on medial femur at proximal to knee joint
QUESTIONS	Question MCL1: Is MCL absent?
LIKELY	+ Yes: + MCL avulsion is LIKELY
UNLIKELY	- No - MCL avulsion is UNLIKELY

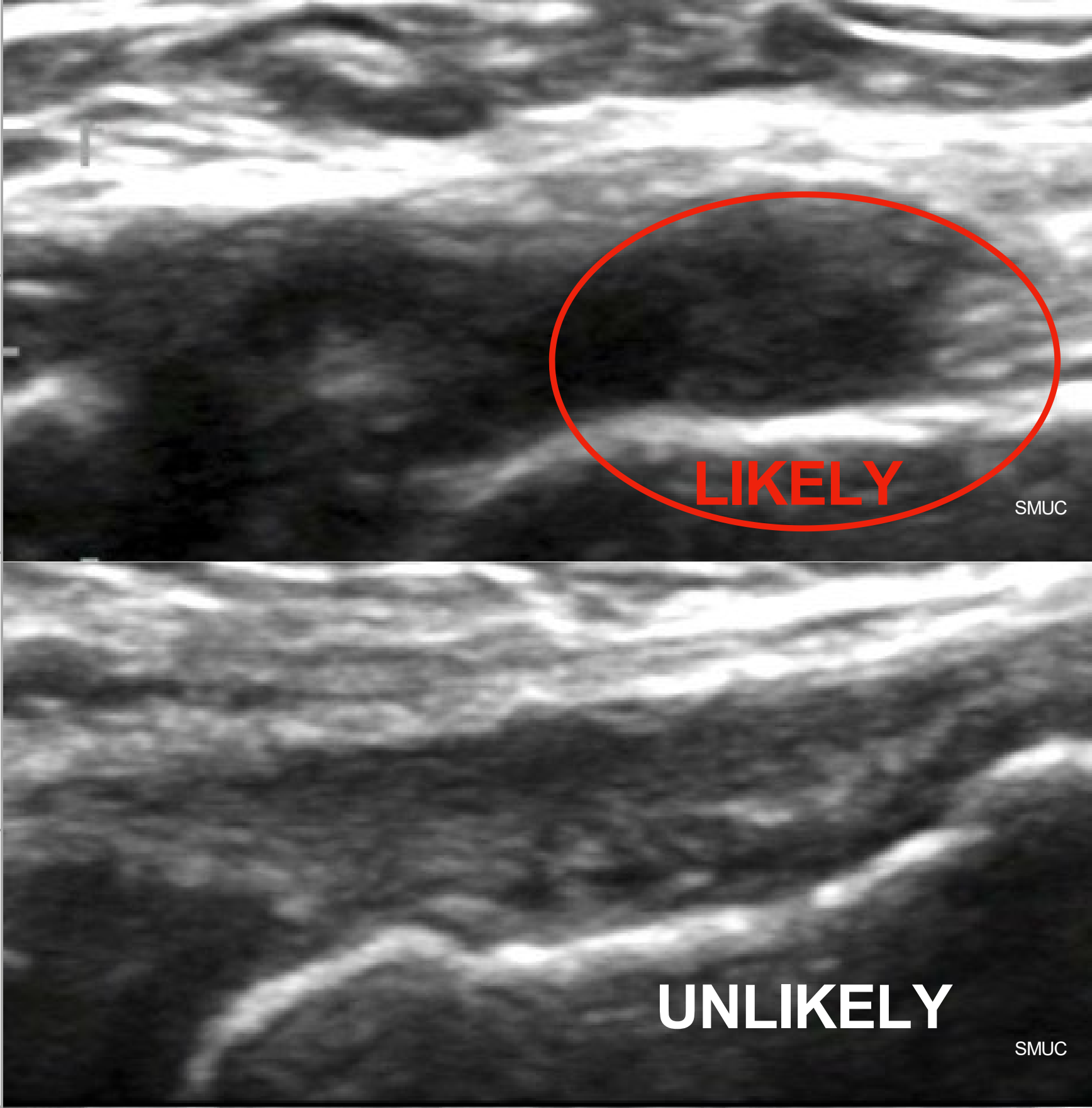


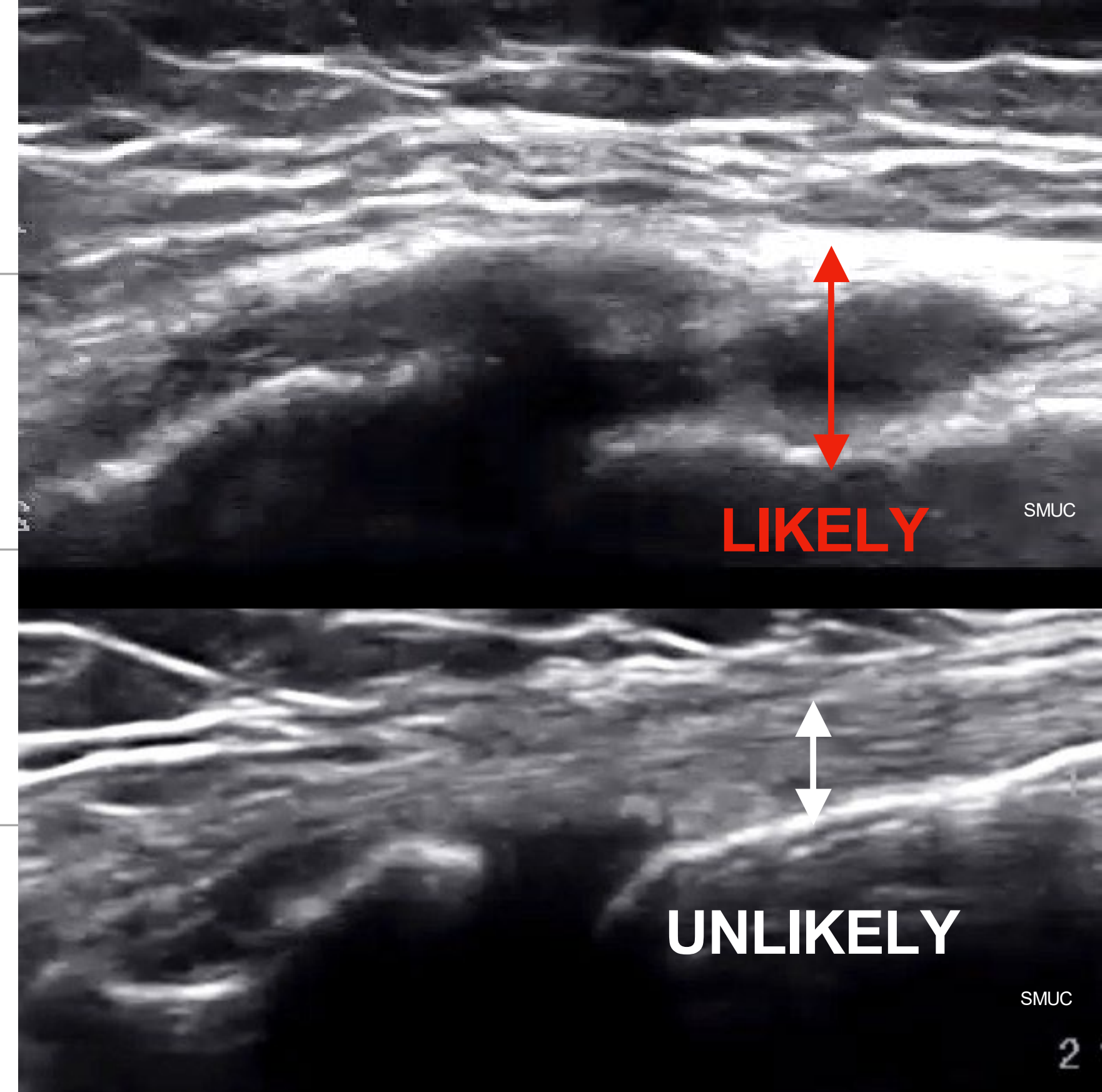
Image MCL2:

Longitudinal on medial femur at knee joint

Question MCL2:

Is MCL thicker than 5mm?

- + Yes:
- + Sprain is MORE LIKELY if MCL is thicker than 6mm
- No
- Sprain is LESS LIKELY if MCL is thinner than 3 mm



PATELLAR / QUADS TENDON TEAR	Image PAT1 / QUAD1: Longitudinal on entire Patellar/ Quads tendon
QUESTIONS	Question PAT1 / QUAD1: Is Patellar/Quads tendon absent?
LIKELY	+ Yes: + Total rupture LIKELY
UNLIKELY	- No: - Total rupture UNLIKELY

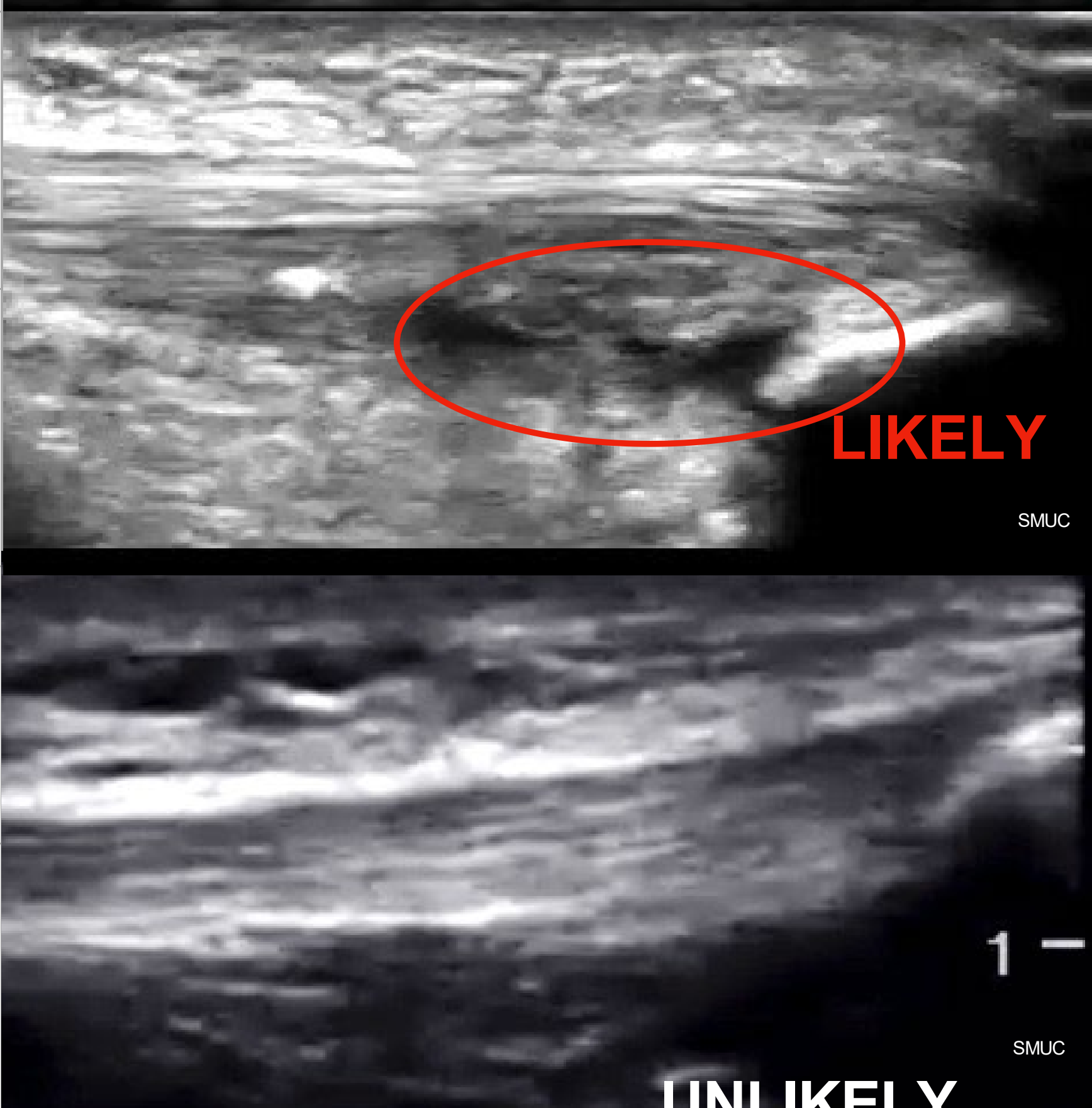
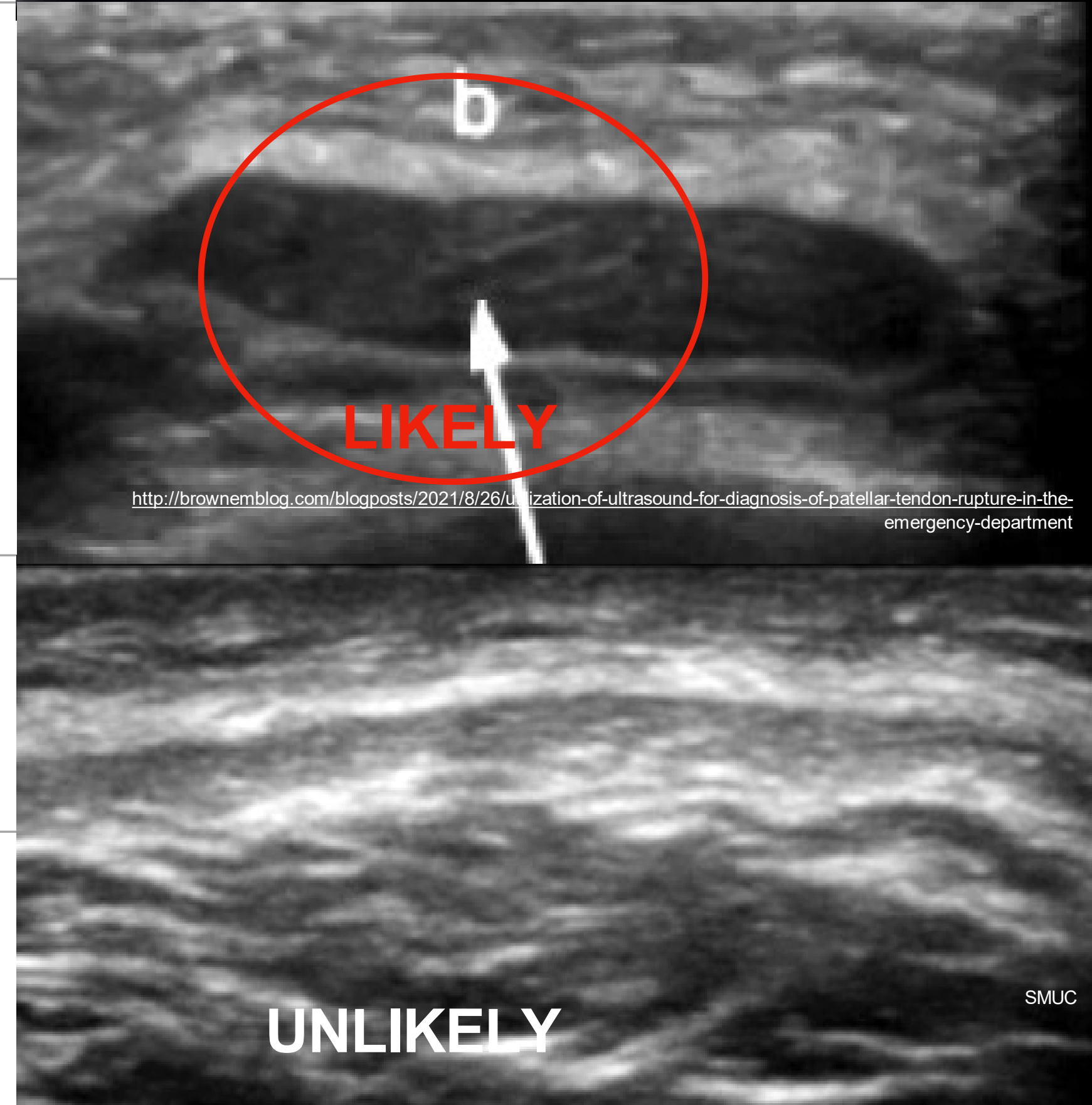


Image PAT2 / QUAD2:
Transverse on Patellar/Quads
tendons at Patella

Question PAT2 / QUAD2:
Are there black or grey areas
within the tendon?

- + Yes:
- + Partial rupture is **LIKELY**

- No:
- Partial rupture is **UNLIKELY**

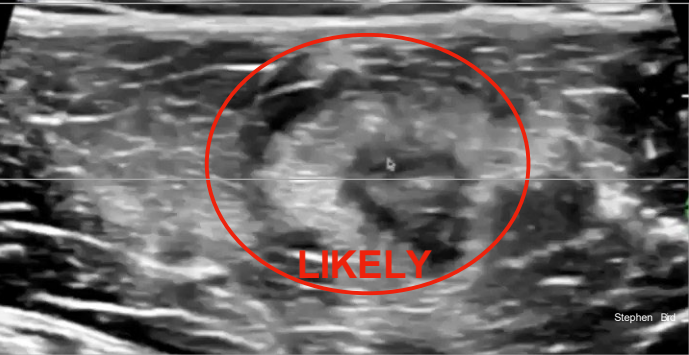

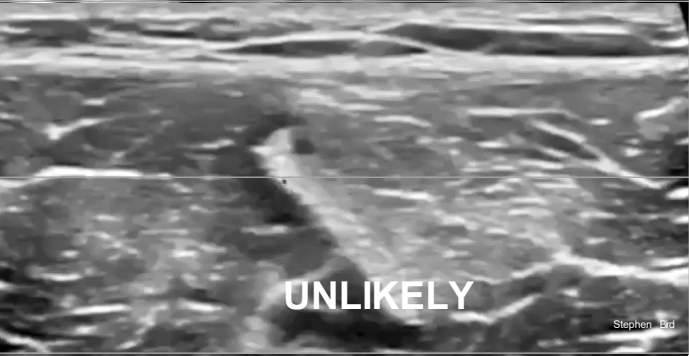

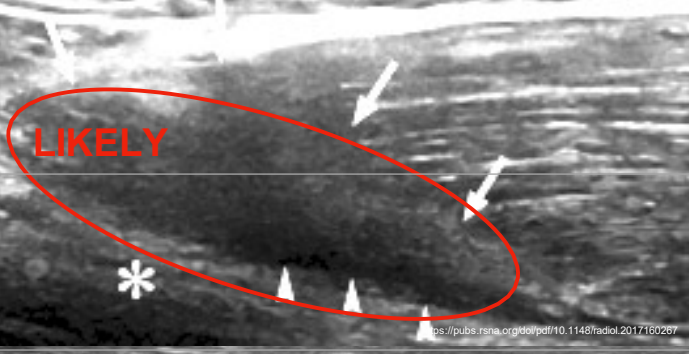

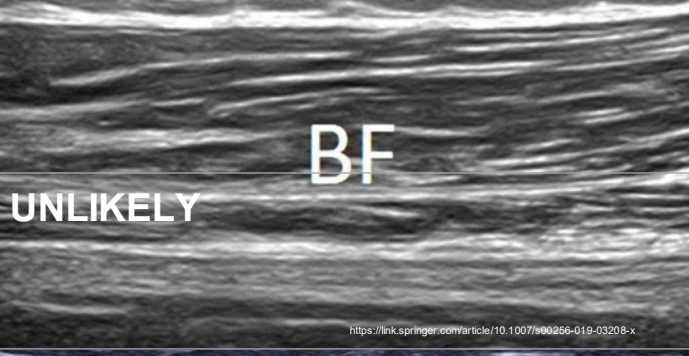


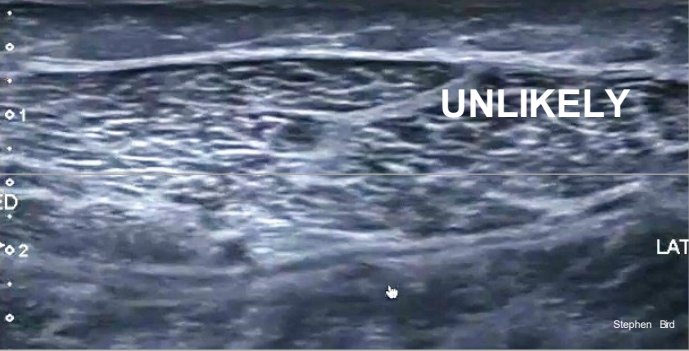
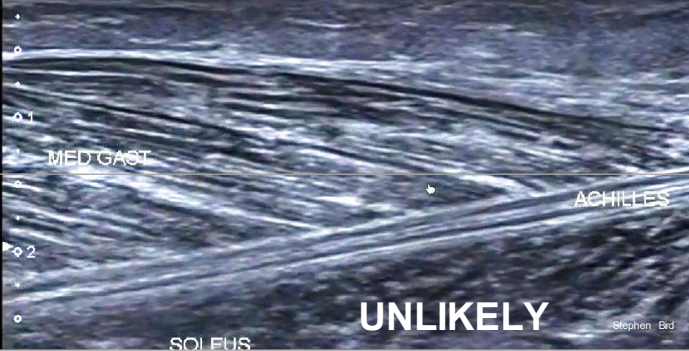


SIDELINE ULTRASOUND
CHART NOTE



SITE OF
PAIN

NAME: _____
DATE & TIME: _____
FINDINGS: _____
ACTION: _____

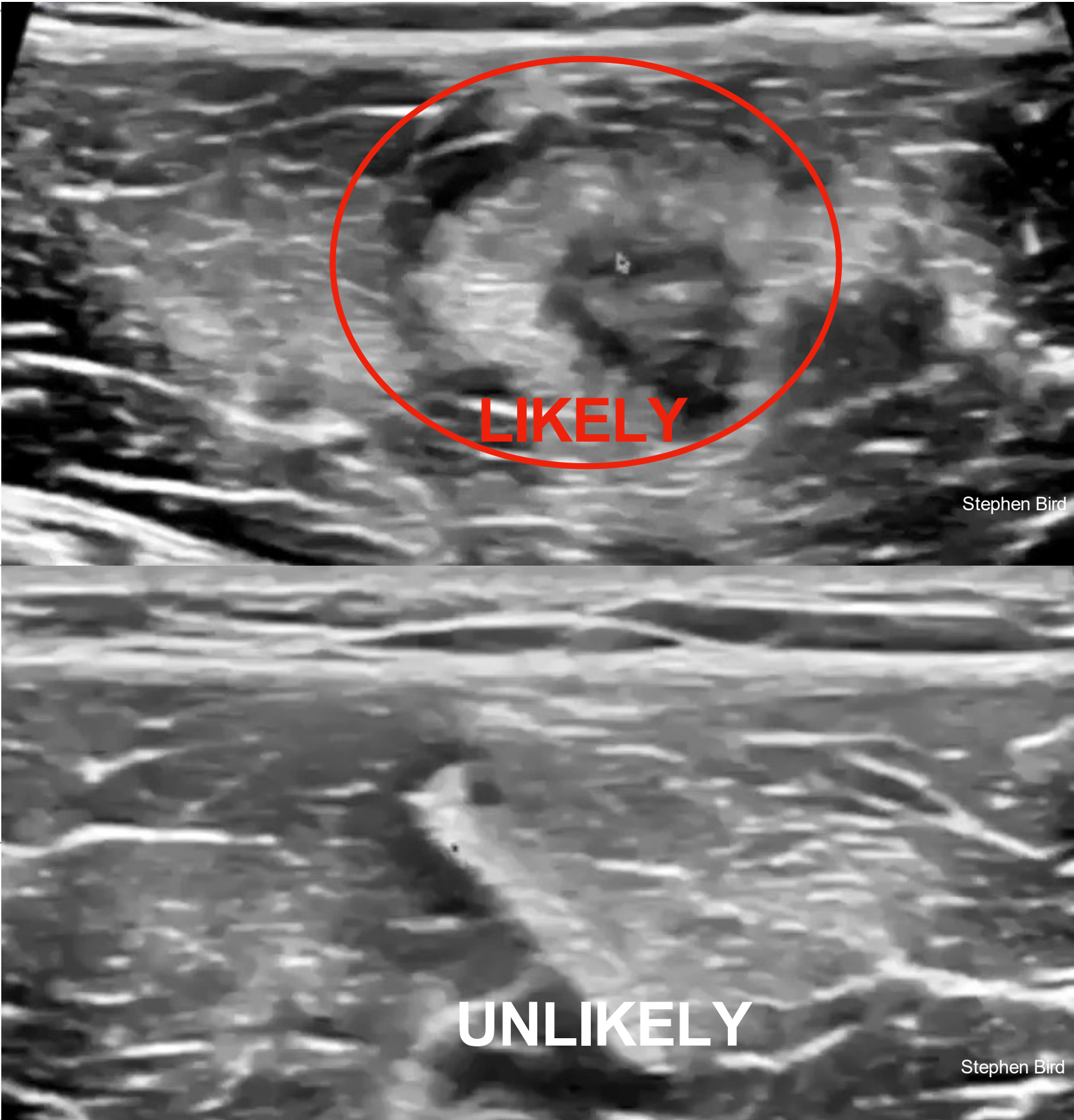
RECTUS FEMORIS MID-PORTION TEAR?	Image RECFEM1: Transverse on mid rectus femoris at area of TTP / swelling		Image RECFEM2: Longitudinal on mid rectus femoris at area of TTP / swelling	
QUESTIONS	Question RECFEM1: Large black (seroma) or grey fluid (hematoma) collection?		Question RECFEM2: Large black (seroma) or grey fluid (hematoma) collection?	
LIKELY	+ Yes large fluid collection: + Seroma/hematoma LIKELY		+ Yes large fluid collection: + Seroma/hematoma LIKELY	
UNLIKELY	- No large fluid collection: - Seroma/hematoma UNLIKELY		- No large fluid collection: - Effusion/Hemarthrosis UNLIKELY	
BICEPS FEMORIS MID-PORTION TEAR?	Image BICEPSFEM1: Transverse on mid biceps femoris at area of TTP / swelling		Image BICEPSFEM2: Longitudinal on mid biceps femoris at area of TTP / swelling	
QUESTIONS	Question BICEPSFEM1: Large black (seroma) or grey fluid (hematoma) collection?		Question BICEPSFEM2: Large black (seroma) or grey fluid (hematoma) collection?	
LIKELY	+ Yes large fluid collection: + Seroma/hematoma LIKELY		+ Yes large fluid collection: + Seroma/hematoma LIKELY	
UNLIKELY	- No large fluid collection: - Seroma/hematoma UNLIKELY		- No large fluid collection: - Seroma/hematoma UNLIKELY	
GASTROC-NEMIUS DISTAL TEAR?	Image GASTROC1: Transverse on medial distal gastroc. at area of TTP / swelling		Image GASTROC2: Longitudinal on medial distal gastroc. at area of TTP / swelling	
QUESTIONS	Question GASTROC1: Large black (seroma) or grey fluid (hematoma) collection?		Question GASTROC2: Large black (seroma) or grey fluid (hematoma) collection?	
LIKELY	+ Yes large fluid collection: + Seroma/hematoma LIKELY		+ Yes large fluid collection: + Seroma/hematoma LIKELY	
UNLIKELY	- No large fluid collection: - Seroma/hematoma UNLIKELY		- No large fluid collection: - Seroma/hematoma UNLIKELY	

SIDELINE ULTRASOUND CHART NOTE



SITE
PA

RECTUS FEMORIS MID-PORTION TEAR?	Image RECFEM1: Transverse on mid rectus femoris at area of TTP / swelling
QUESTIONS	Question RECFEM1: Large black (seroma) or grey fluid (hematoma) collection?
LIKELY	+ Yes large fluid collection: + Seroma/hematoma LIKELY
UNLIKELY	- No large fluid collection: - Seroma/hematoma UNLIKELY





SITE OF
PAIN

NAME: _____
DATE & TIME: _____
FINDINGS: _____
ACTION: _____

Image RECFEM2:

Longitudinal on mid rectus femoris at area of TTP / swelling

Question RECFEM2:

Large black (seroma) or grey fluid (hematoma) collection?

- + Yes large fluid collection:
- + Seroma/hematoma **LIKELY**

- No large fluid collection:
- Effusion/Hemarthrosis **UNLIKELY**



BICEPS FEMORIS MID-PORTION TEAR?	Image BICEPSFEM1: Transverse on mid biceps femoris at area of TTP / swelling
QUESTIONS	Question BICEPSFEM1: Large black (seroma) or grey fluid (hematoma) collection?
LIKELY	+ Yes large fluid collection: + Seroma/hematoma LIKELY
UNLIKELY	- No large fluid collection: - Seroma/hematoma UNLIKELY

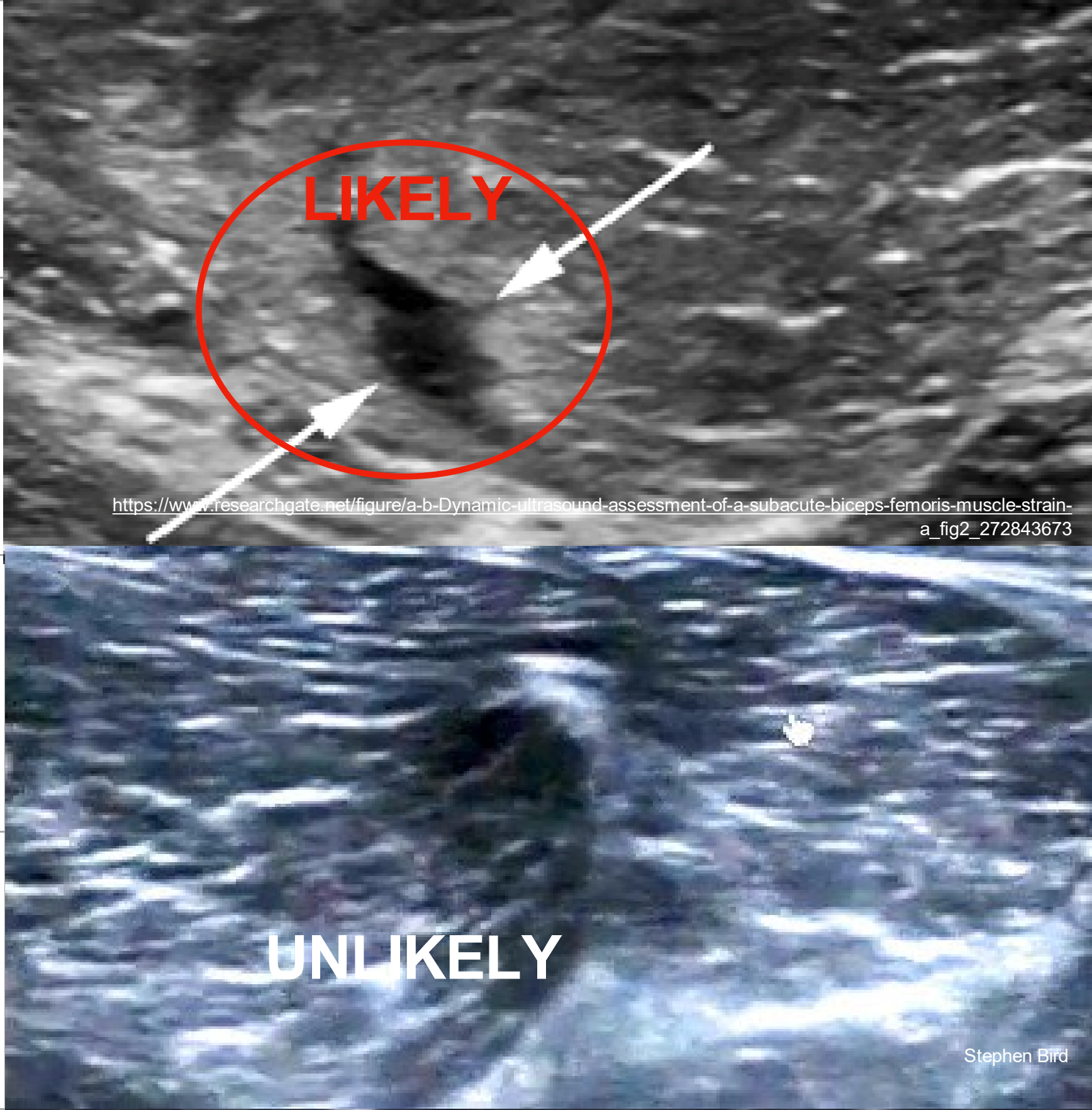


Image BICEPSFEM2:

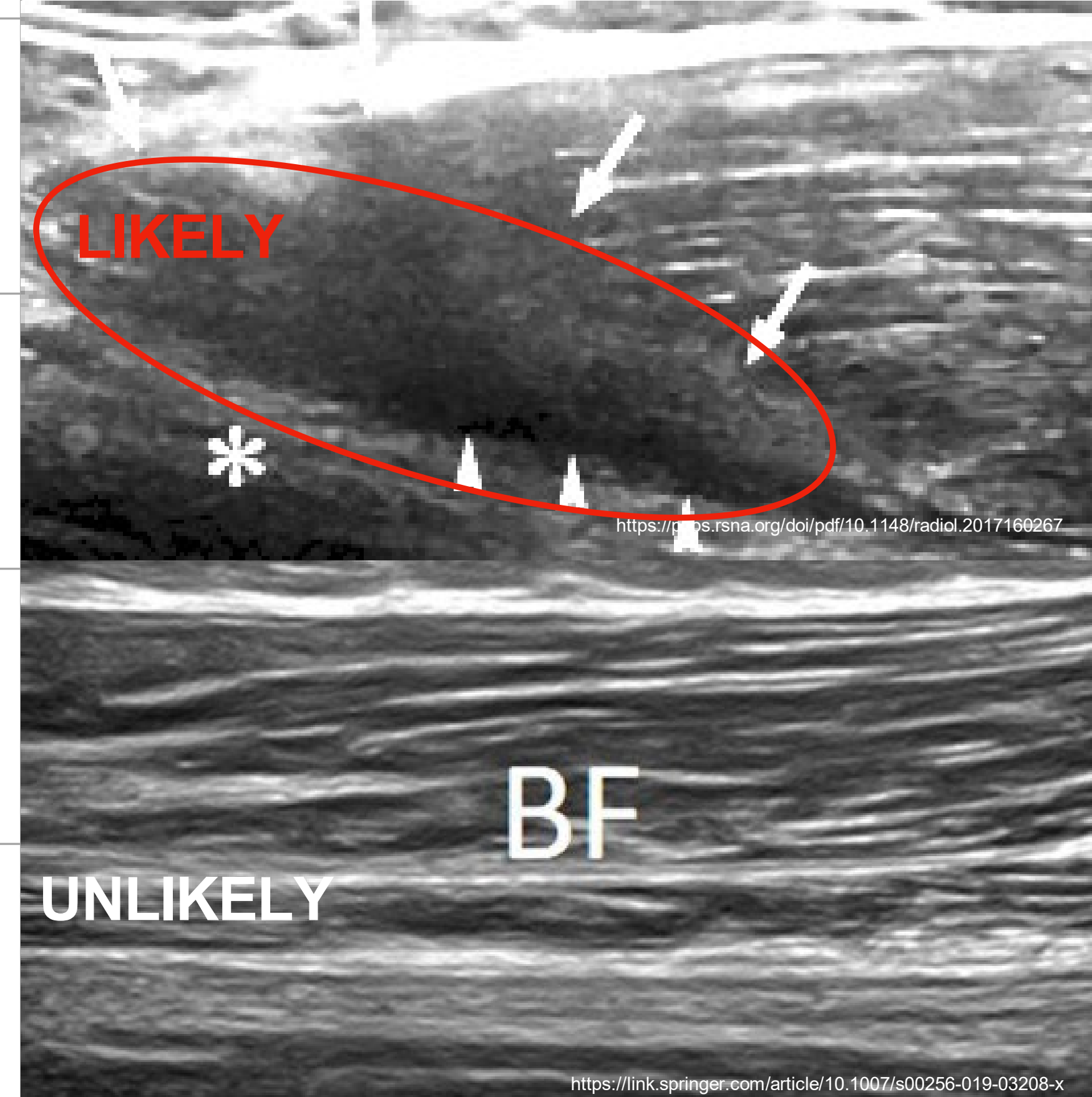
Longitudinal on mid biceps femoris at area of TTP / swelling

Question BICEPSFEM2:

Large black (seroma) or grey fluid (hematoma) collection?

- + Yes large fluid collection:
- + Seroma/hematoma **LIKELY**

- No large fluid collection:
- Seroma/hematoma **UNLIKELY**



GASTROC- NEMIUS DISTAL TEAR?	Image GASTROC1: Transverse on medial distal gastroc. at area of TTP / swelling
QUESTIONS	Question GASTROC1: Large black (seroma) or grey fluid (hematoma) collection?
LIKELY	+ Yes large fluid collection: + Seroma/hematoma LIKELY
UNLIKELY	- No large fluid collection: - Seroma/hematoma UNLIKELY

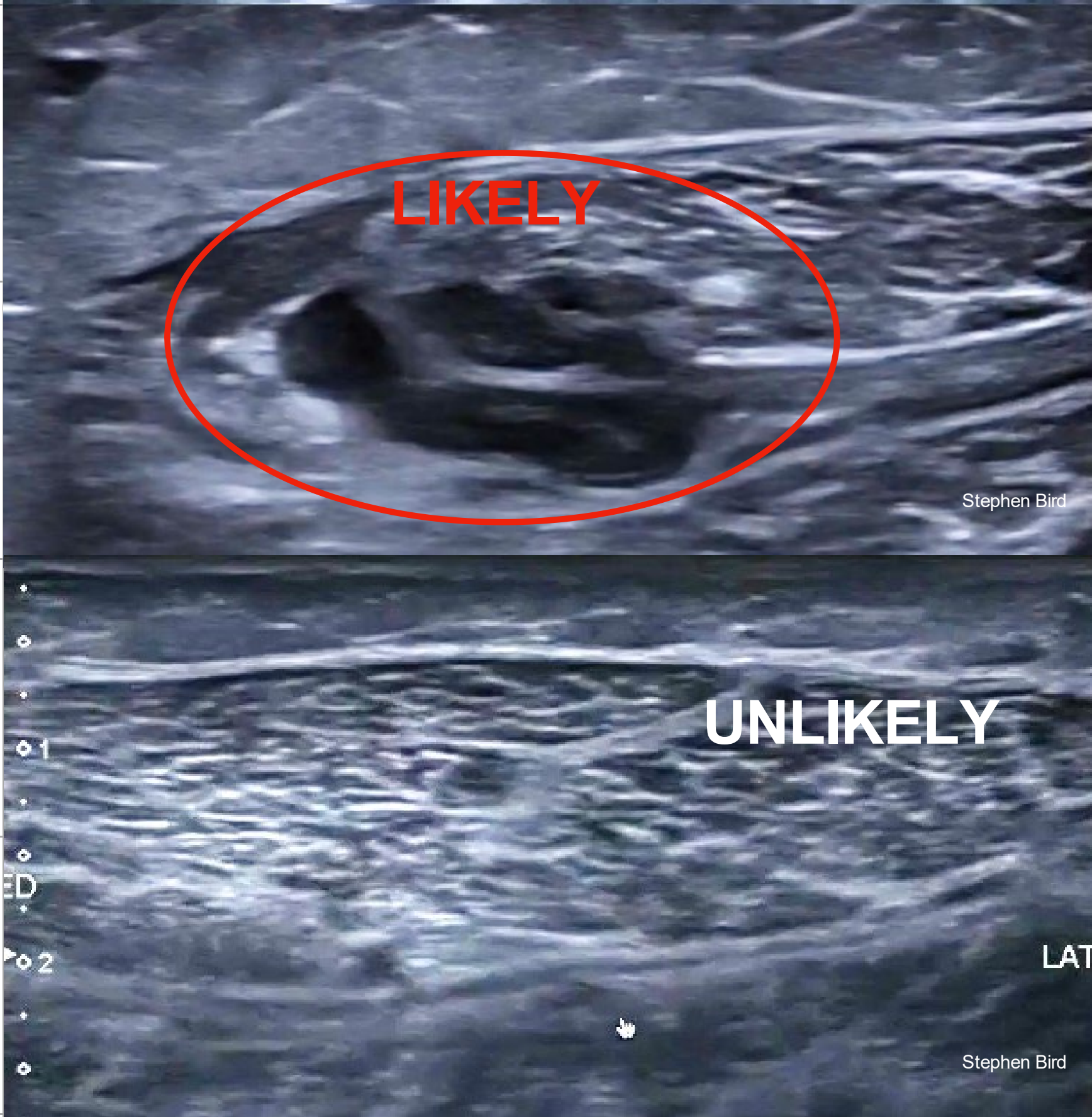


Image GASTROC2:

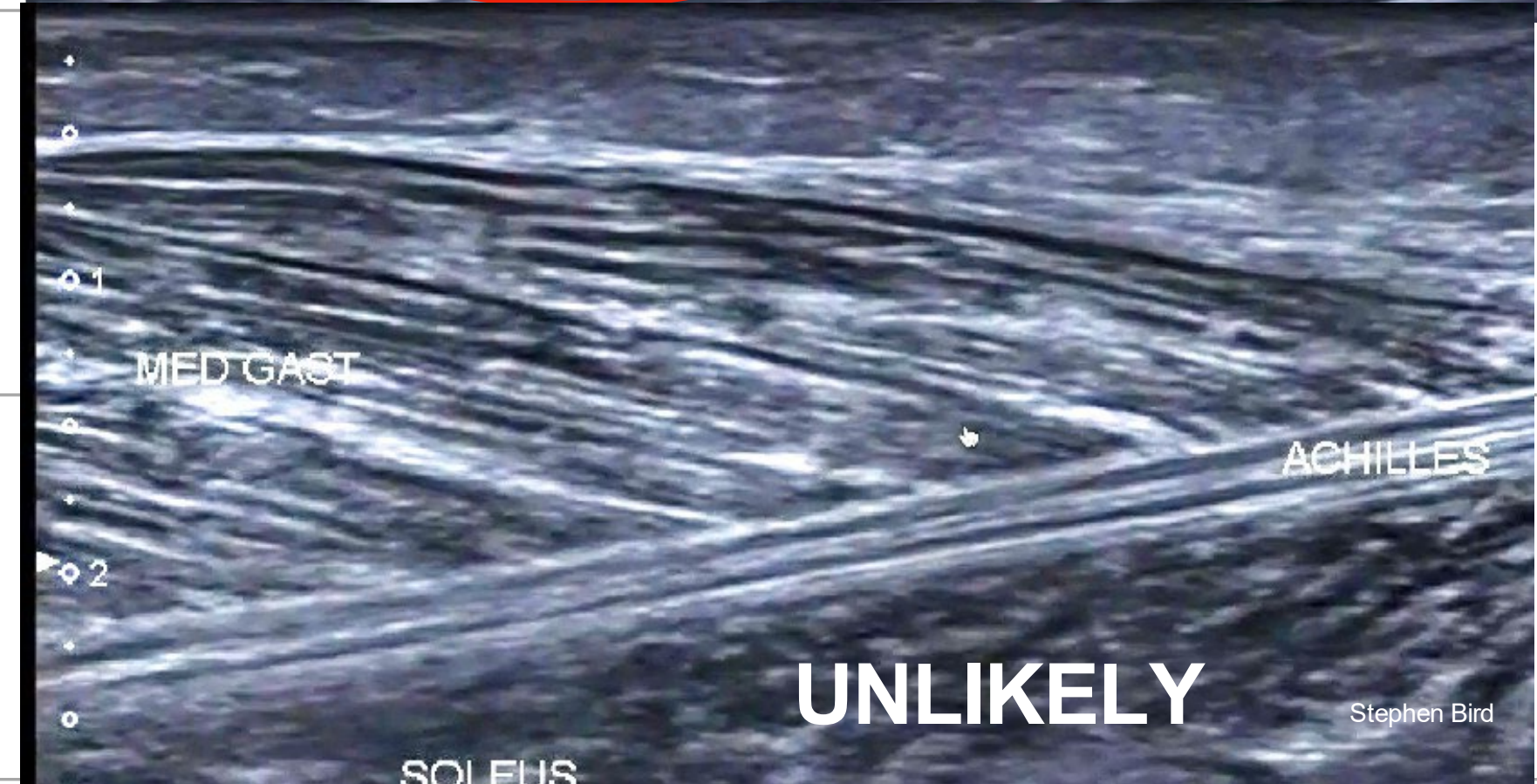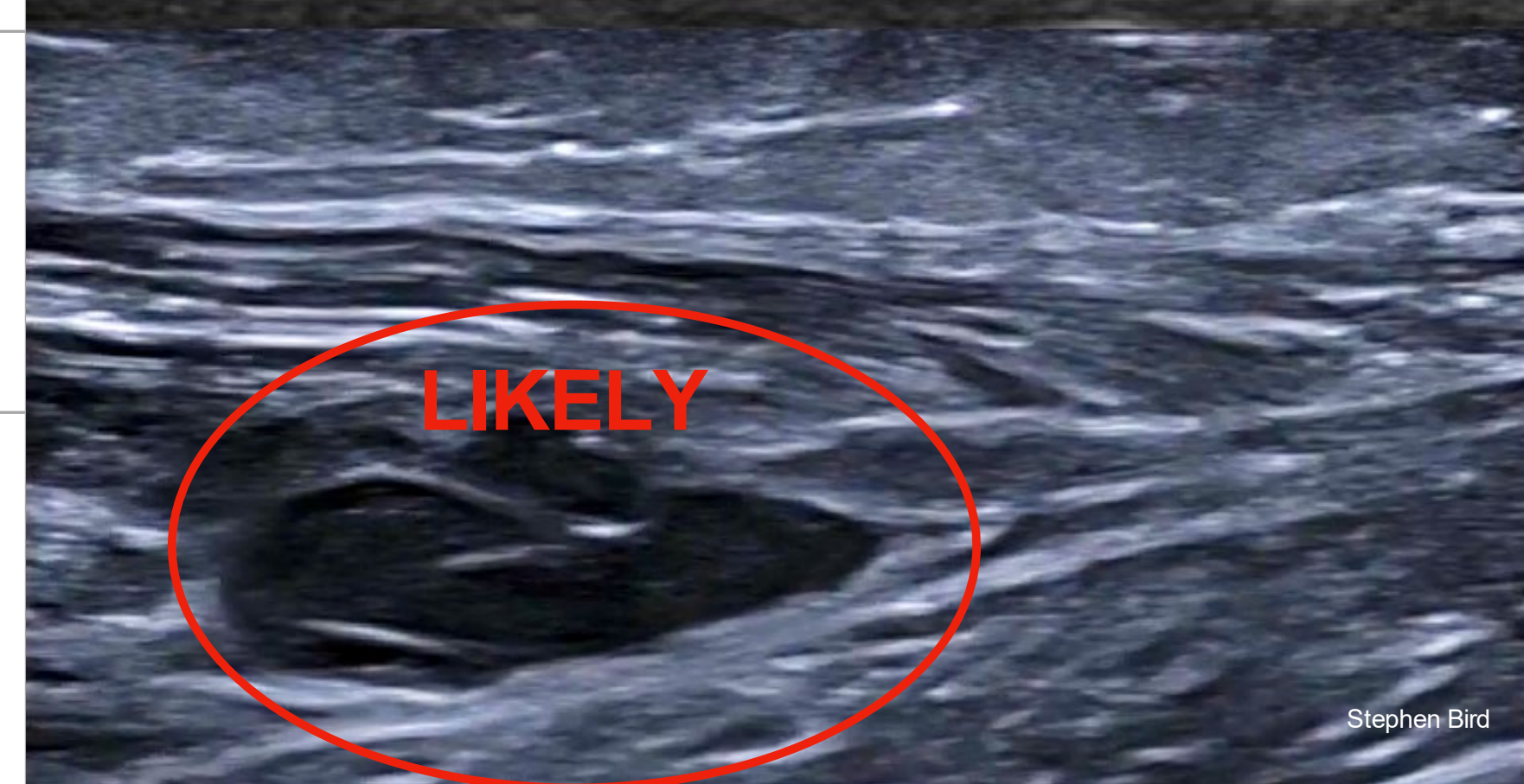Longitudinal on medial distal gastroc. at area of TTP / swelling

Question GASTROC2:

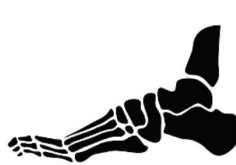Large black (seroma) or grey fluid (hematoma) collection?

- + Yes large fluid collection:
- + Seroma/hematoma **LIKELY**

- No large fluid collection:
- Seroma/hematoma **UNLIKELY**

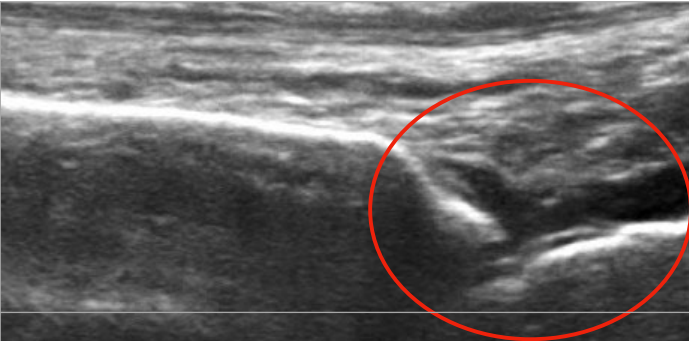
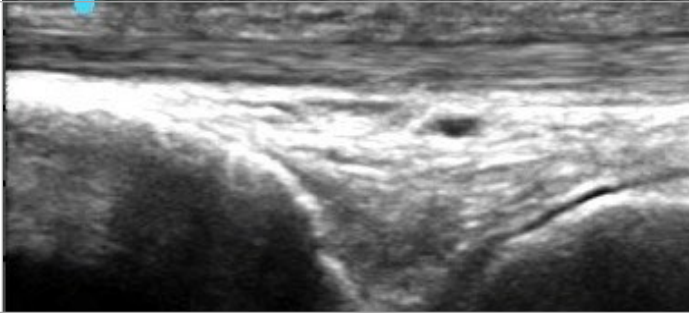



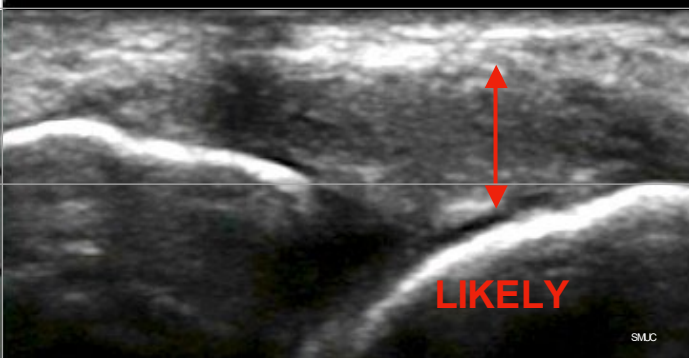


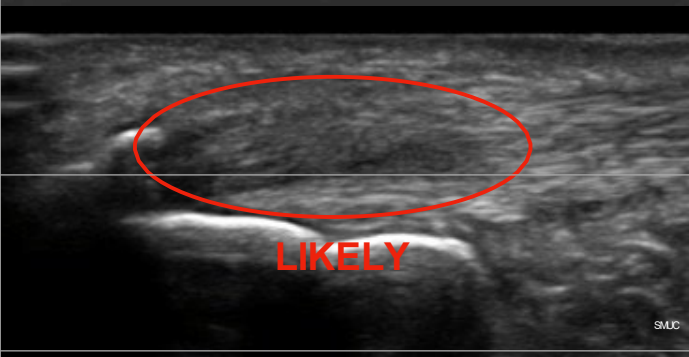
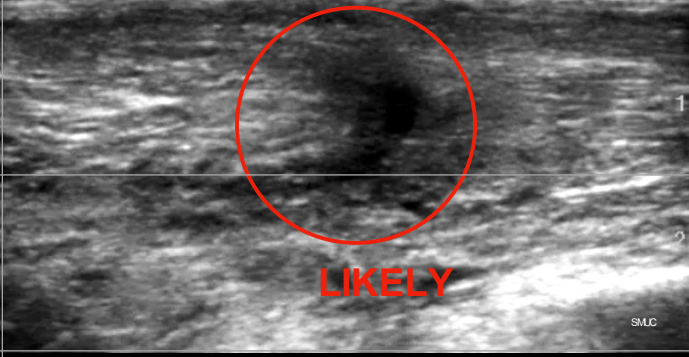


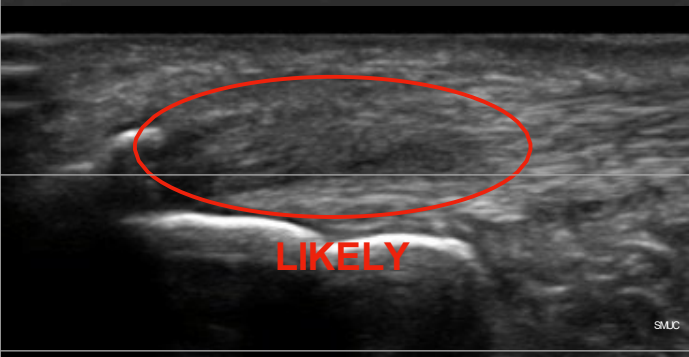
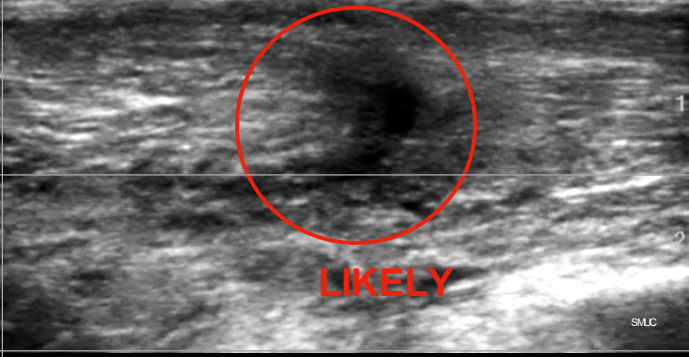







SIDELINE ULTRASOUND
CHART NOTE

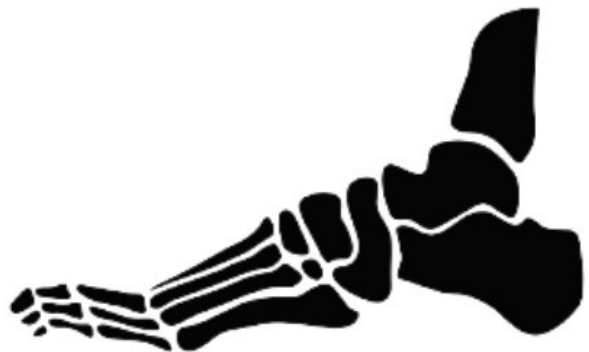

SITE OF
PAIN

NAME: _____
DATE & TIME: _____
FINDINGS: _____
ACTION: _____

ANKLE JOINT EFFUSION? / HEMARTHROSIS?	Image ANKLE1: Longitudinal on anterior tibia at ankle		Question ANKLE1: Large black (effusion) or grey fluid (hemarthrosis) collection?	
	LIKELY + Yes large fluid collection: + Effusion/ Hemarthrosis LIKELY		UNLIKELY - No large fluid collection: - Effusion/ Hemarthrosis UNLIKELY	
				
FIBULAR # ATFL TEAR	Image ATFL1: Transverse on distal fibula at ATFL		Image ATFL2: Longitudinal on ATFL	
QUESTIONS	Question ATFL1: Bony cortex interrupted?		Question ATFL2: Is ATFL more than 5mm thick?	
LIKELY	+ Yes: + Fibular avulsion # LIKELY		+ Yes: + AFTL Injury LIKELY if > 5mm	
UNLIKELY	- No: - Fibular avulsion # UNLIKELY		- No: - AFTL Injury UNLIKELY if < 3mm	
ACHILLES TENDON TEAR	Image ACHILLES1: Longitudinal on achilles tendon with calcaneus on screen		Image ACHILLES2: Longitudinal on achilles tendon without calcaneus on screen	
QUESTIONS	Question ACHILLES1: Are there black or grey areas within the tendon?		Question ACHILLES2: Are there black or grey areas within the tendon?	
LIKELY	+ Yes: + Partial Tear LIKELY		+ Yes: + Partial or Total rupture LIKELY	
UNLIKELY	- No: - Partial Tear UNLIKELY		- No: - Partial or total rupture UNLIKELY	

SIDELINE ULTRASOUND CHART NOTE

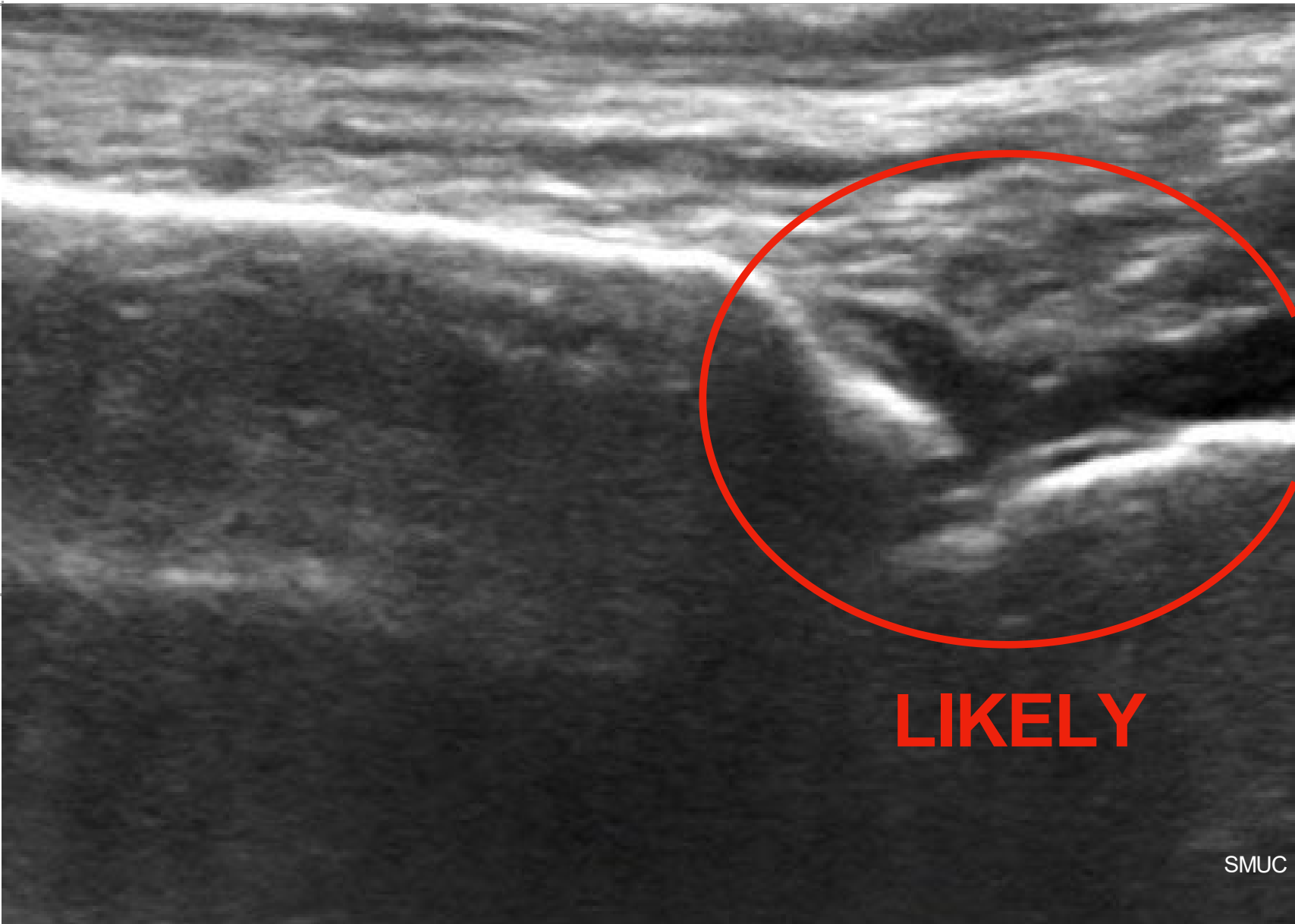


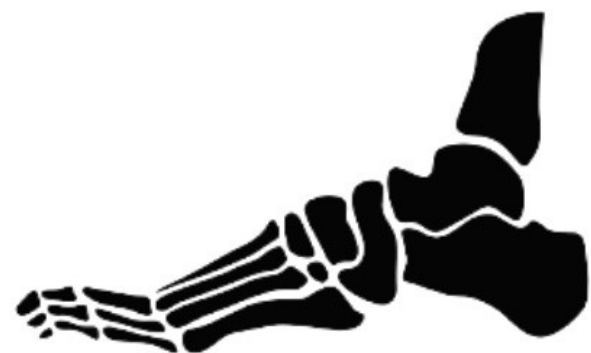SITE
PA

**ANKLE JOINT
EFFUSION?
/ HEMARTHROSIS?**

Image ANKLE1:
Longitudinal on anterior tibia at ankle

LIKELY
+ Yes large fluid
collection:
+ Effusion/
Hemarthrosis
LIKELY





SITE OF
PAIN

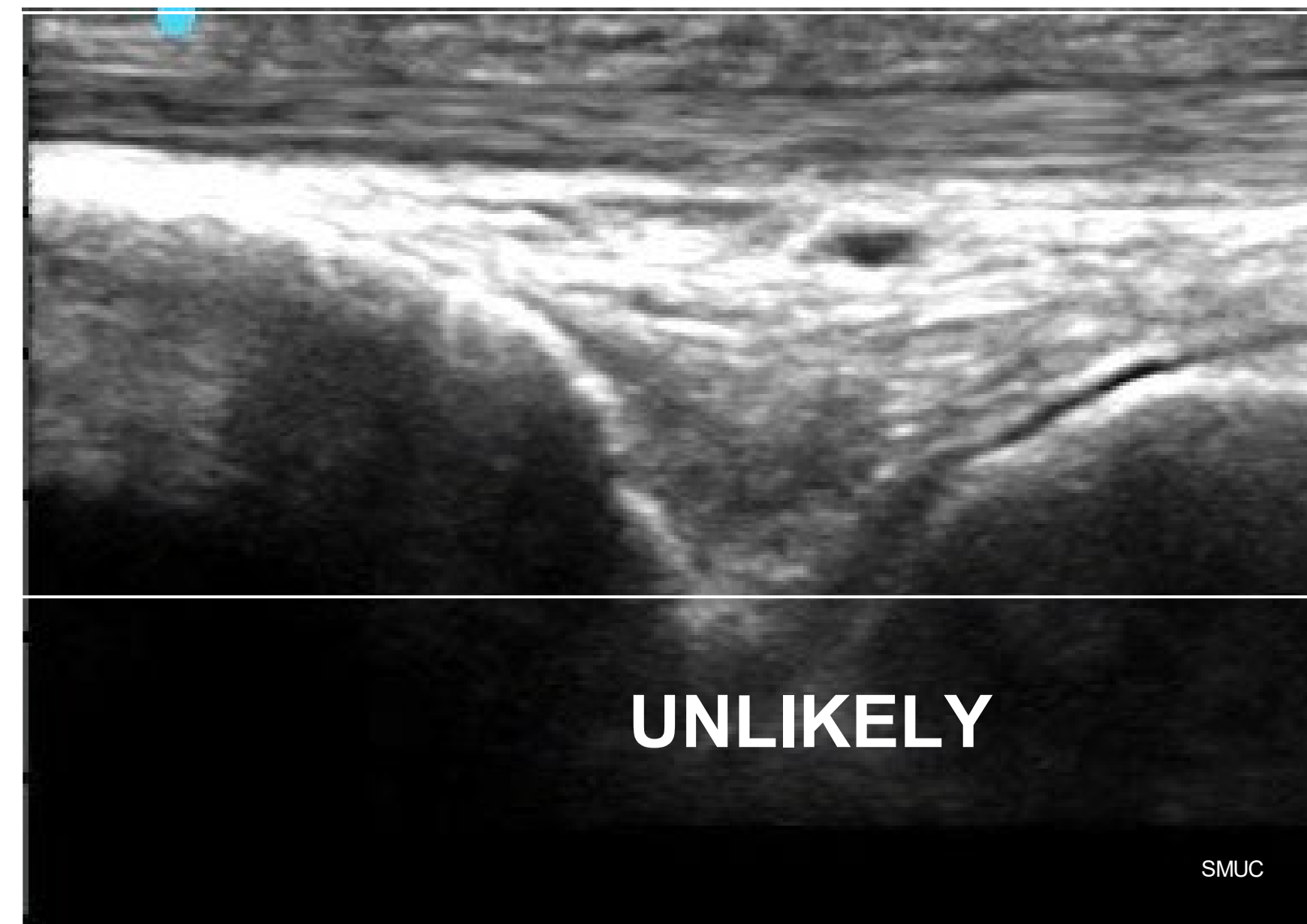
NAME: _____
DATE & TIME: _____
FINDINGS: _____
ACTION: _____

Question ANKLE1:

Large black (effusion) or grey fluid (hemarthrosis) collection?

UNLIKELY

- No large fluid collection:
- Effusion/
Hemarthrosis
UNLIKELY



FIBULAR # ATFL TEAR	Image ATFL1: Transverse on distal fibula at ATFL
QUESTIONS	Question ATFL1: Bony cortex interrupted?
LIKELY	+ Yes: + Fibular avulsion # LIKELY
UNLIKELY	- No: - Fibular avulsion # UNLIKELY

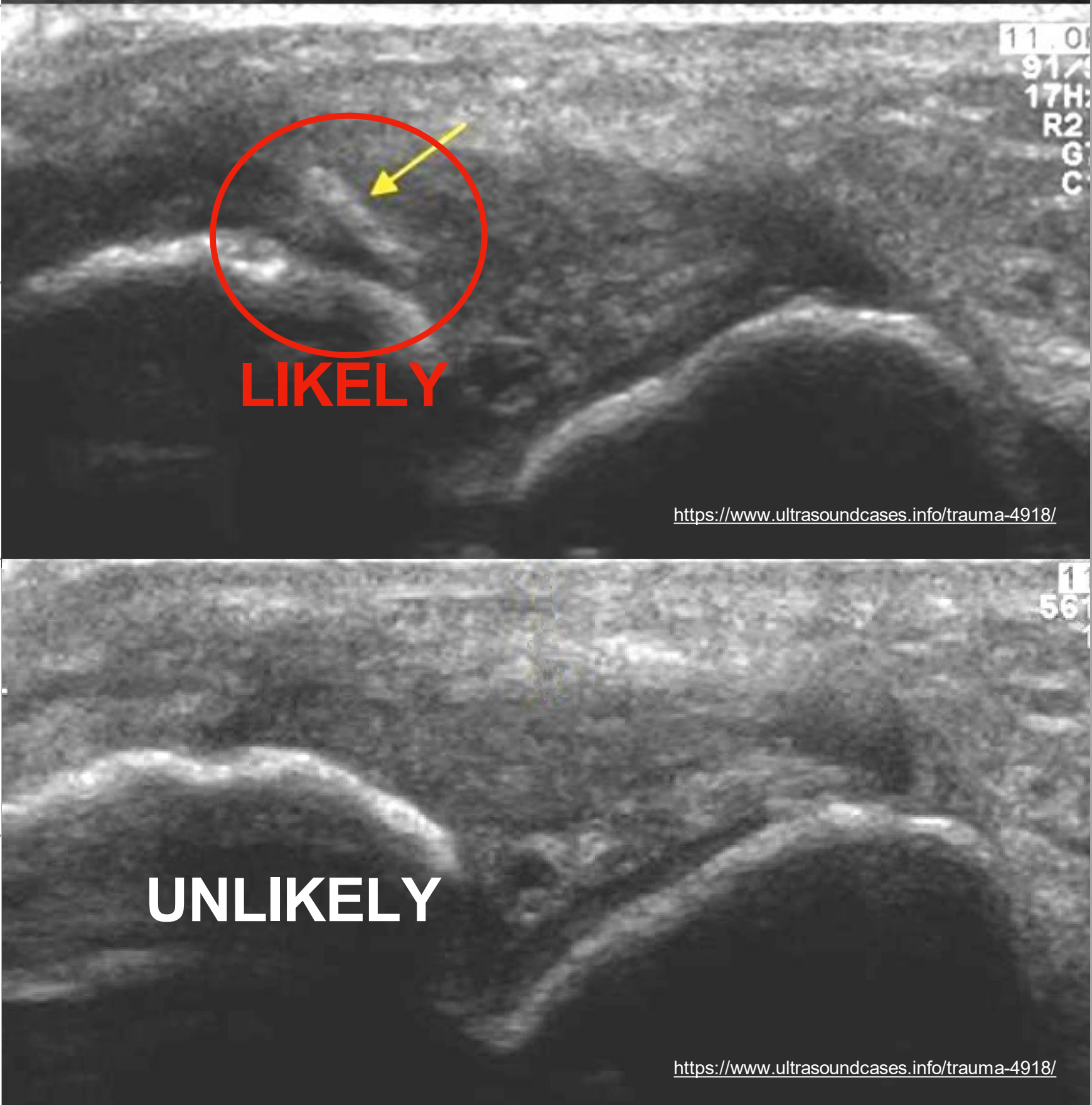
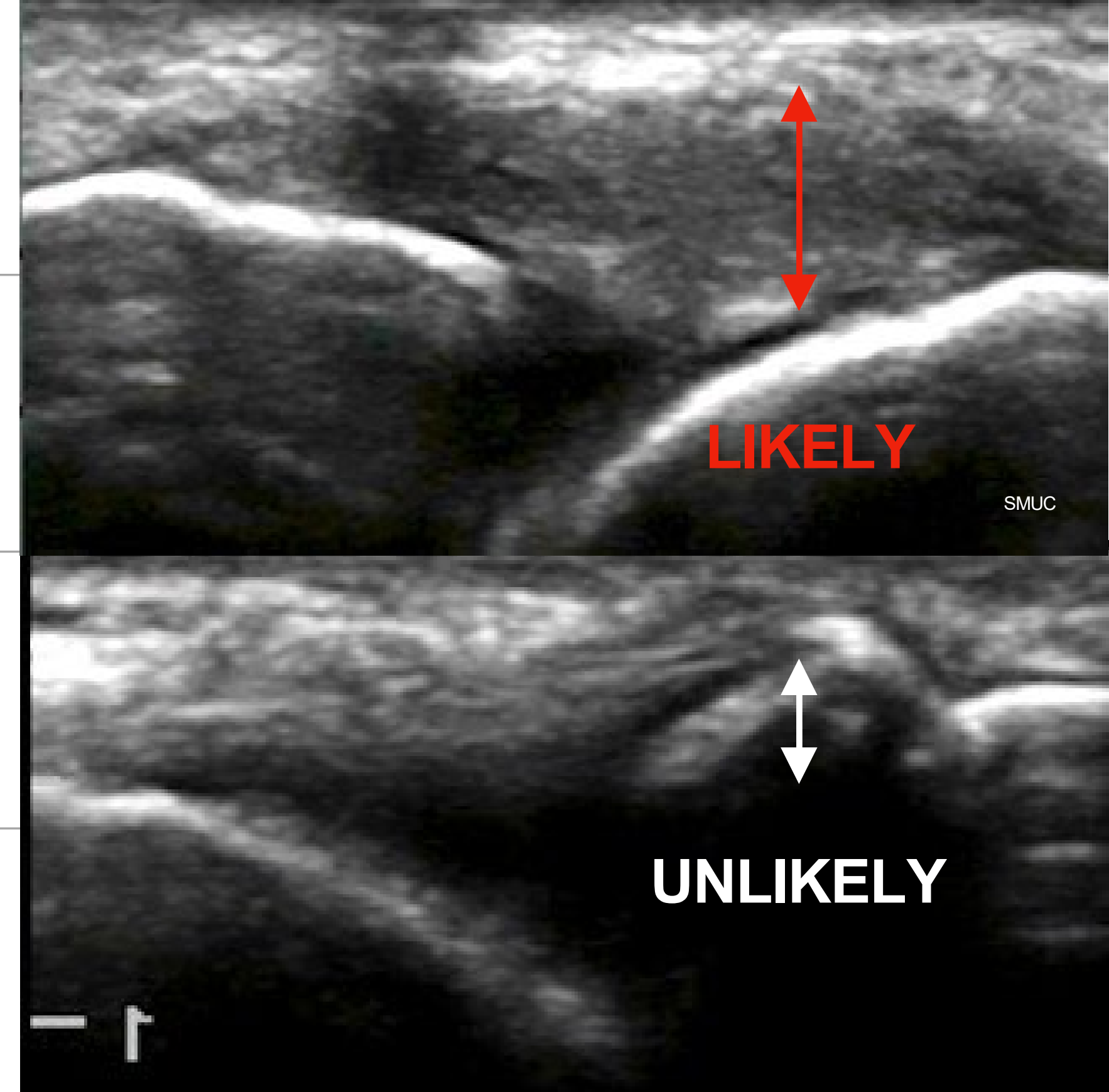


Image ATFL2:
Longitudinal on ATFL

Question ATFL2:
Is ATFL more than 5mm thick?

- + Yes:
- + AFTL Injury **LIKELY** if $> 5\text{mm}$

- No:
- AFTL Injury **UNLIKELY** if $< 3\text{mm}$



**ACHILLES
TENDON TEAR**

Image ACHILLES1:
Longitudinal on achilles tendon
with calcaneus on screen

QUESTIONS

Question ACHILLES1:
Are there black or grey areas
within the tendon?

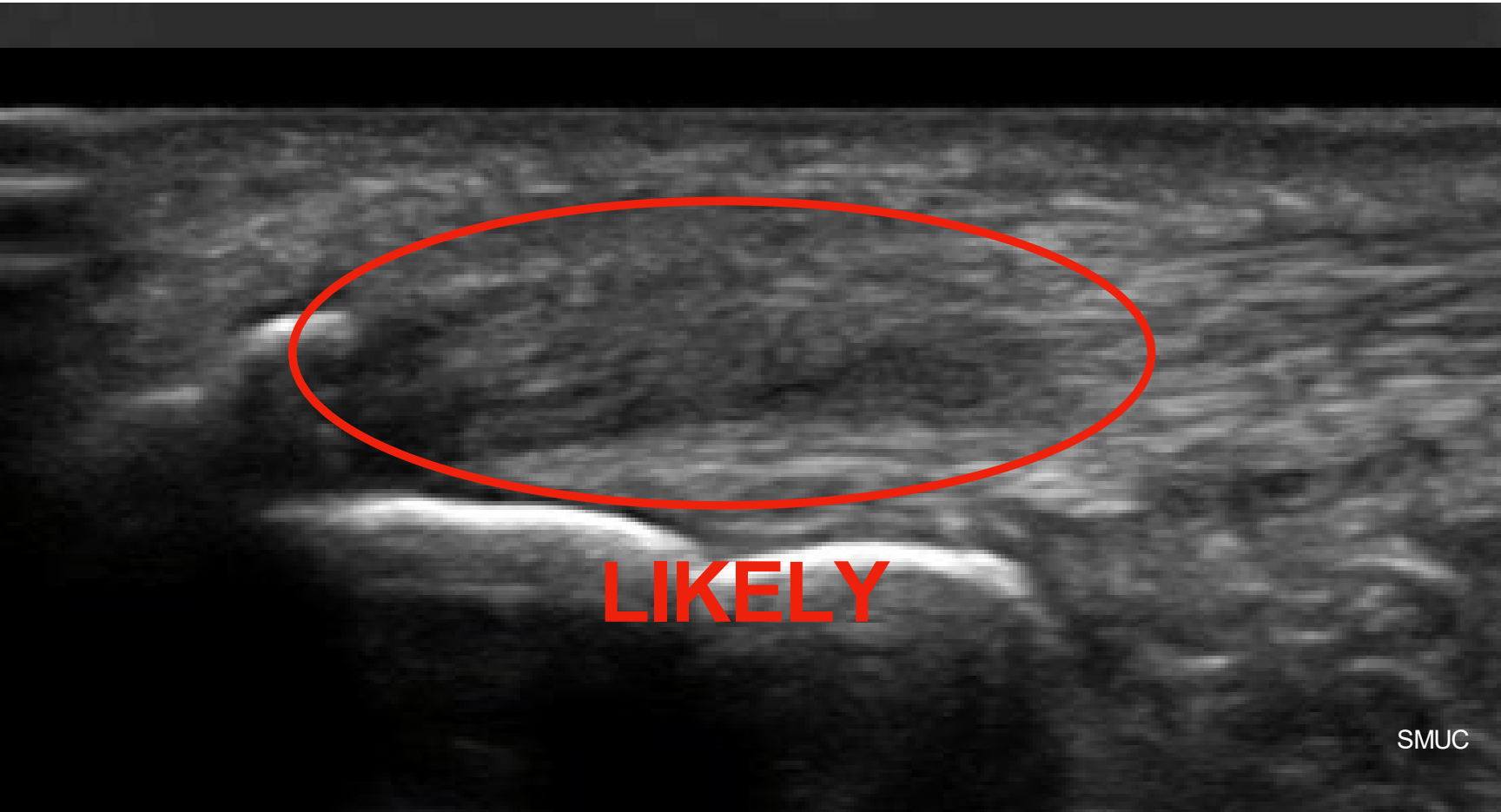
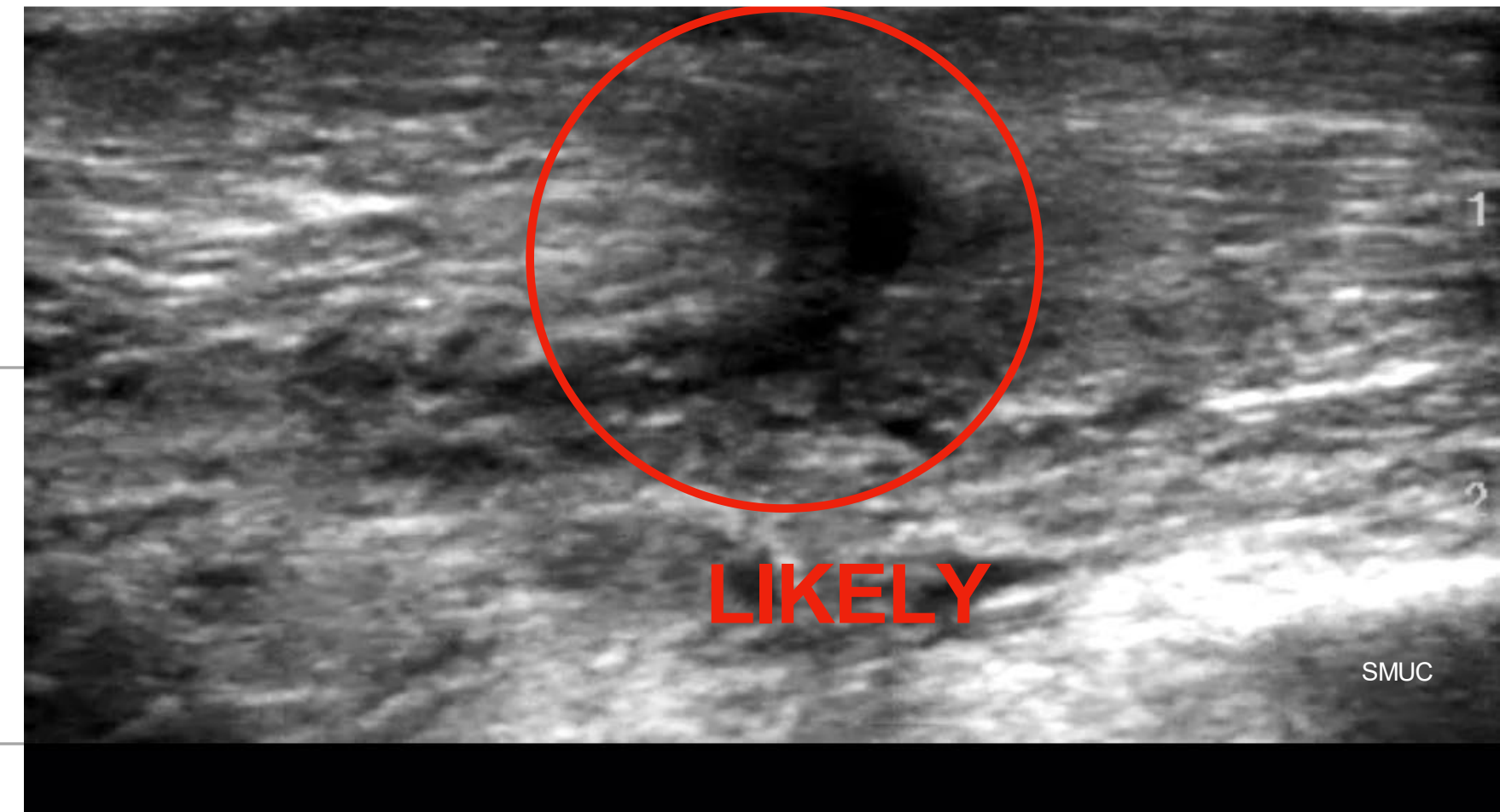


Image ACHILLES2:

Longitudinal on achilles tendon
without calcaneus on screen

Question ACHILLES2:

Are there black or grey areas
within the tendon?



Break

- Is the bone angled?
- Is the bone discontinuous?

Osteophyte

- Is there a bony prominence near an articulation?

uneven cortex/articulation

- Is there a large defect in the bone?
- Is there an abnormal articulation?

Enthesis

- Is there an irregular bony surface where the tendon or ligament attaches?

Hypoechoic/anechoic

Occupying a space

- Is it pushing soft tissue away?
- I.e. stretching a joint capsule or pushing away a fat pad?

2 Questions

1. Is the fluid Free or Contained?
2. Is the fluid Simple or Complex?

Thickness

- Is the tissue thickened or thinned?

Irregular

- Is there an irregular shape of the tendon/ligament?

Same

- Is the tissue the same as the other side?

Signal of doppler

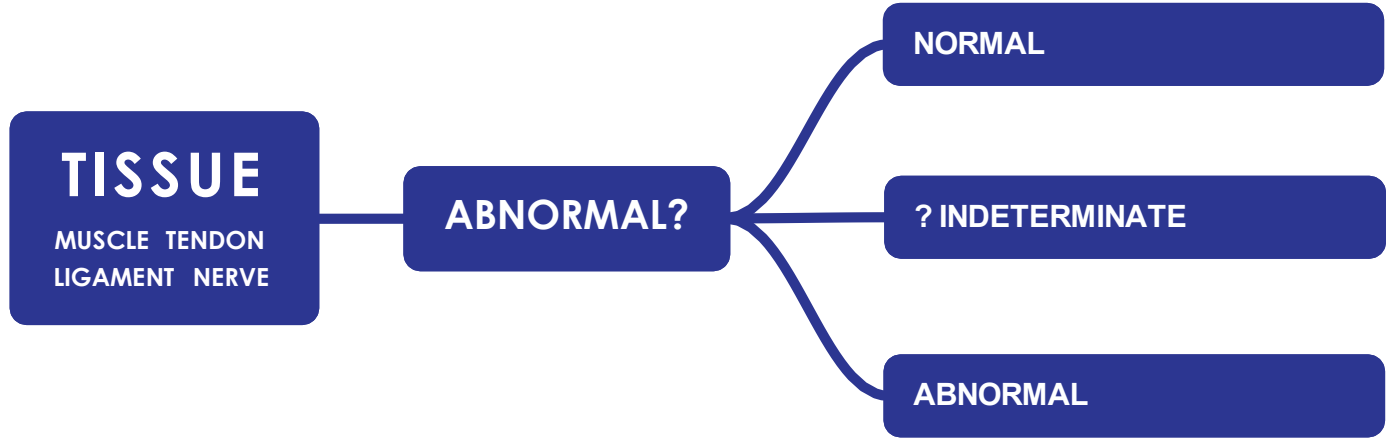
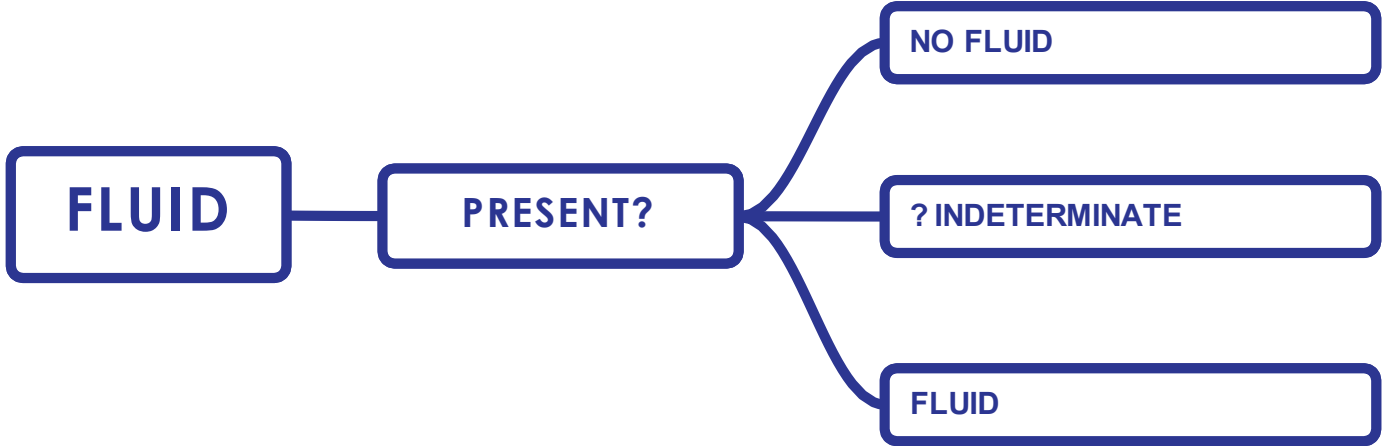
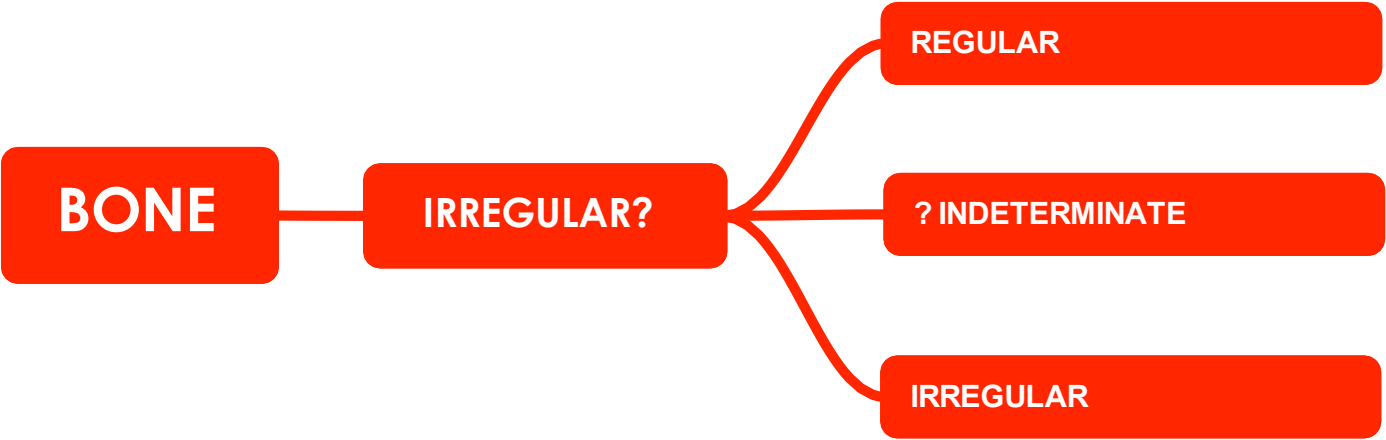
- Is the doppler signal high?

Unusual fibers

- Are the fibers unusual or discontinuous?

Echogenicity

- Is the tissue hyperechoic, hypoechoic or anechoic?



CBD

Calcium

- Linear or pinpoint
- Oval or round
- Dimensions in mm

Bony irregularity

- Small area
- Large area
- Dimensions in mm

Doppler

- Low, medium, or high

THC

Thickness

- Compared to contralateral side
- Dimensions in mm

Heterogeneity

- Homogenous
- Heterogenous

Colour

- Hypo vs Hyperechoic
- Is there anisotropy?

LSD

Location

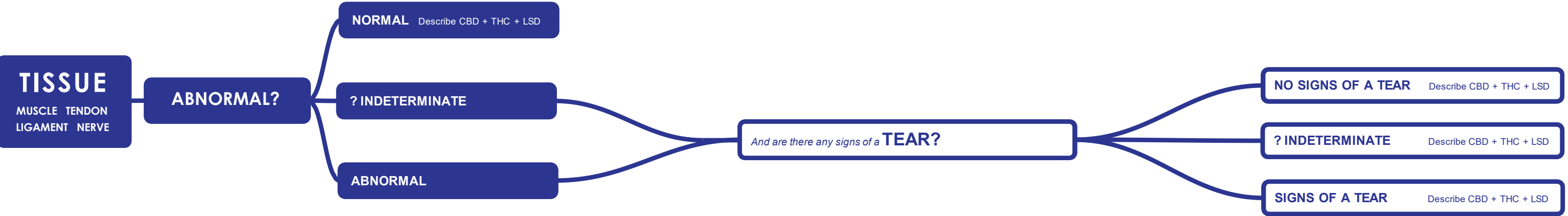
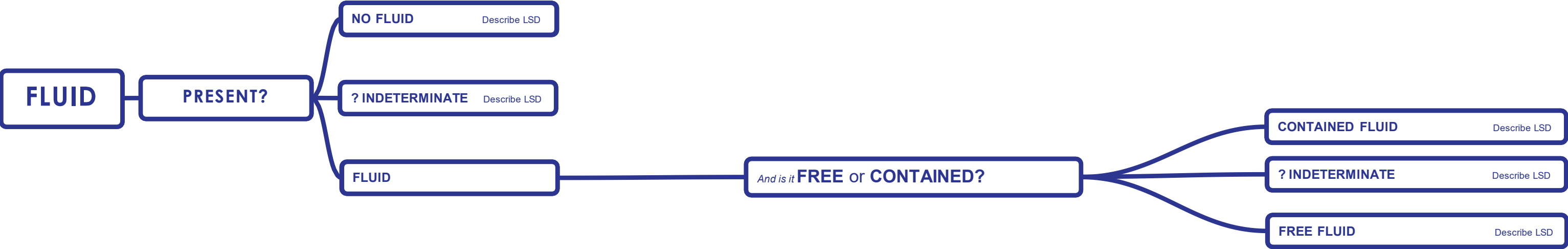
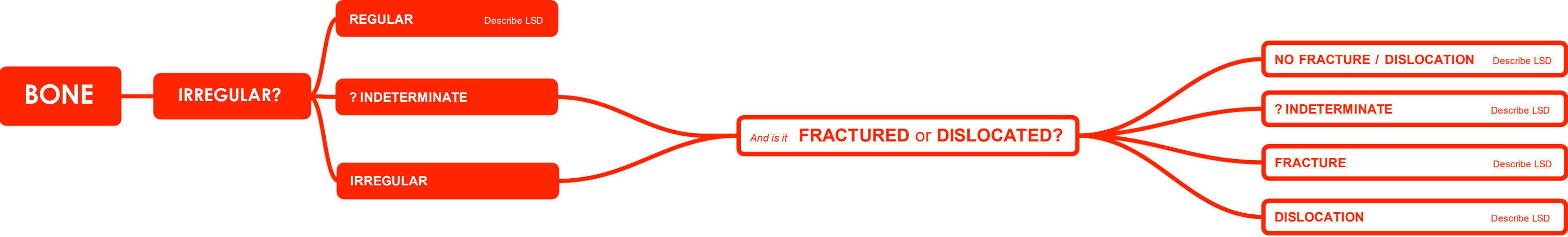
- Superficial or Deep
- Anterior or Posterior
- Medial or Lateral

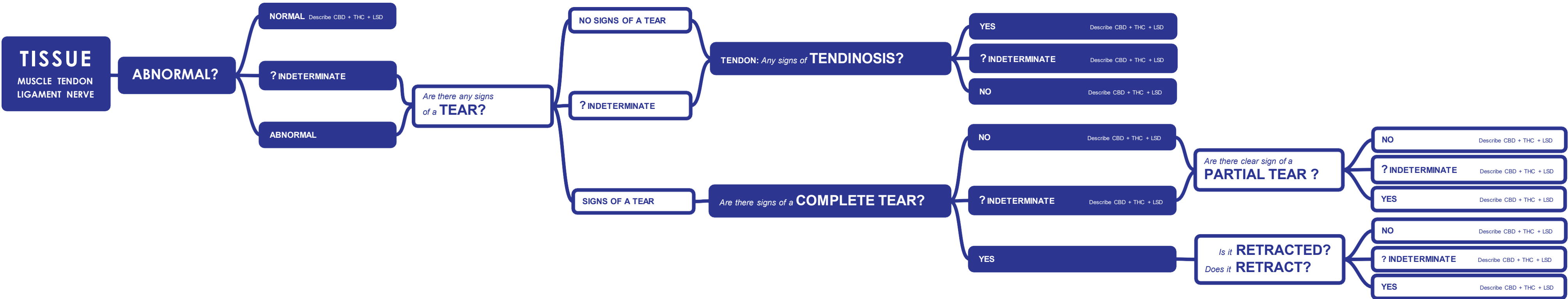
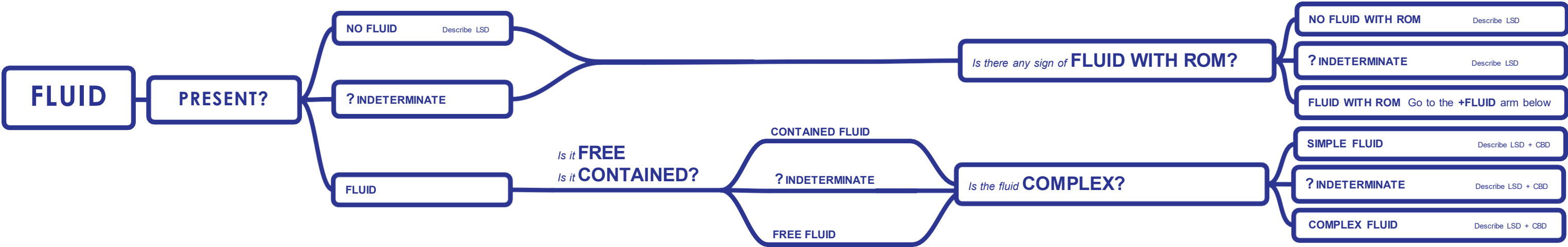
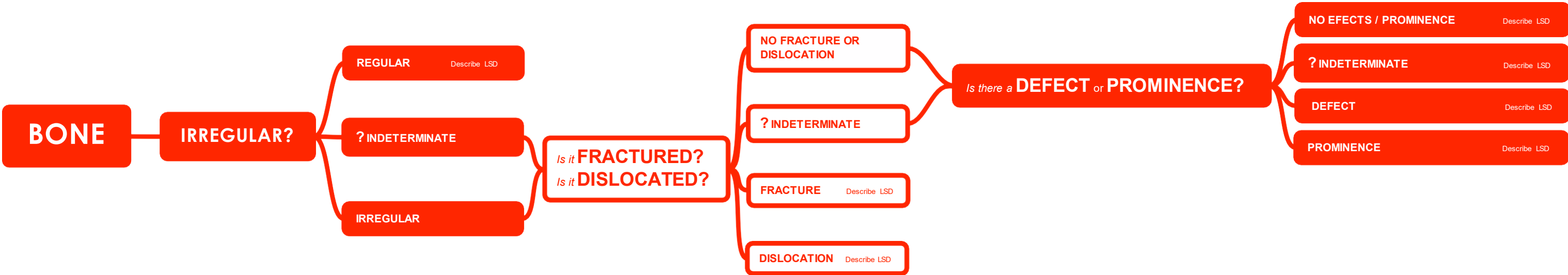
Shape

- Linear
- Curved
- Irregular


Dimensions

- in mm





Msk
L50



1

2

Break

- Is the bone angled?
- Is the bone discontinuous?

Osteophyte

- Is there a bony prominence near an articulation?

Uneven cortex/articulation

- Is there a large defect in the bone?
- Is there an abnormal articulation?

Enthesis

- Is there an irregular bony surface where the tendon or ligament attaches?

Hypoechoic/anechoic

Occupying a space

- Is it pushing soft tissue away?
- I.e. stretching a joint capsule or pushing away a fat pad?

2 Questions

1. Is the fluid Free or Contained?
2. Is the fluid Simple or Complex?

Thickness

- Is the tissue thickened or thinned?

Irregular

- Is there an irregular shape of the tendon/ligament?

Same

- Is the tissue the same as the other side?

Signal of doppler

- Is the doppler signal high?

Unusual fibers

- Are the fibers unusual or discontinuous?

Echogenicity

- Is the tissue hyperechoic, hypoechoic or anechoic?

BONE

IRREGULAR?

REGULAR

? INDETERMINATE

IRREGULAR

FLUID

PRESENT?

NO FLUID

? INDETERMINATE

FLUID

TISSUE

MUSCLE TENDON
LIGAMENT NERVE

ABNORMAL?

NORMAL

? INDETERMINATE

ABNORMAL

CBD

Calcium

- Linear or pinpoint
- Oval or round
- Dimensions in mm

Bony irregularity

- Small area
- Large area
- Dimensions in mm

Doppler

- Low, medium, or high

THC

Thickness

- Compared to contralateral side
- Dimensions in mm

Heterogeneity

- Homogenous
- Heterogenous

Colour

- Hypo vs Hyperechoic
- Is there anisotropy?

LSD

Location

- Superficial or Deep
- Anterior or Posterior
- Medial or Lateral

Shape

- Linear
- Curved
- Irregular

Dimensions

- in mm

Depth

Zoom

SNP

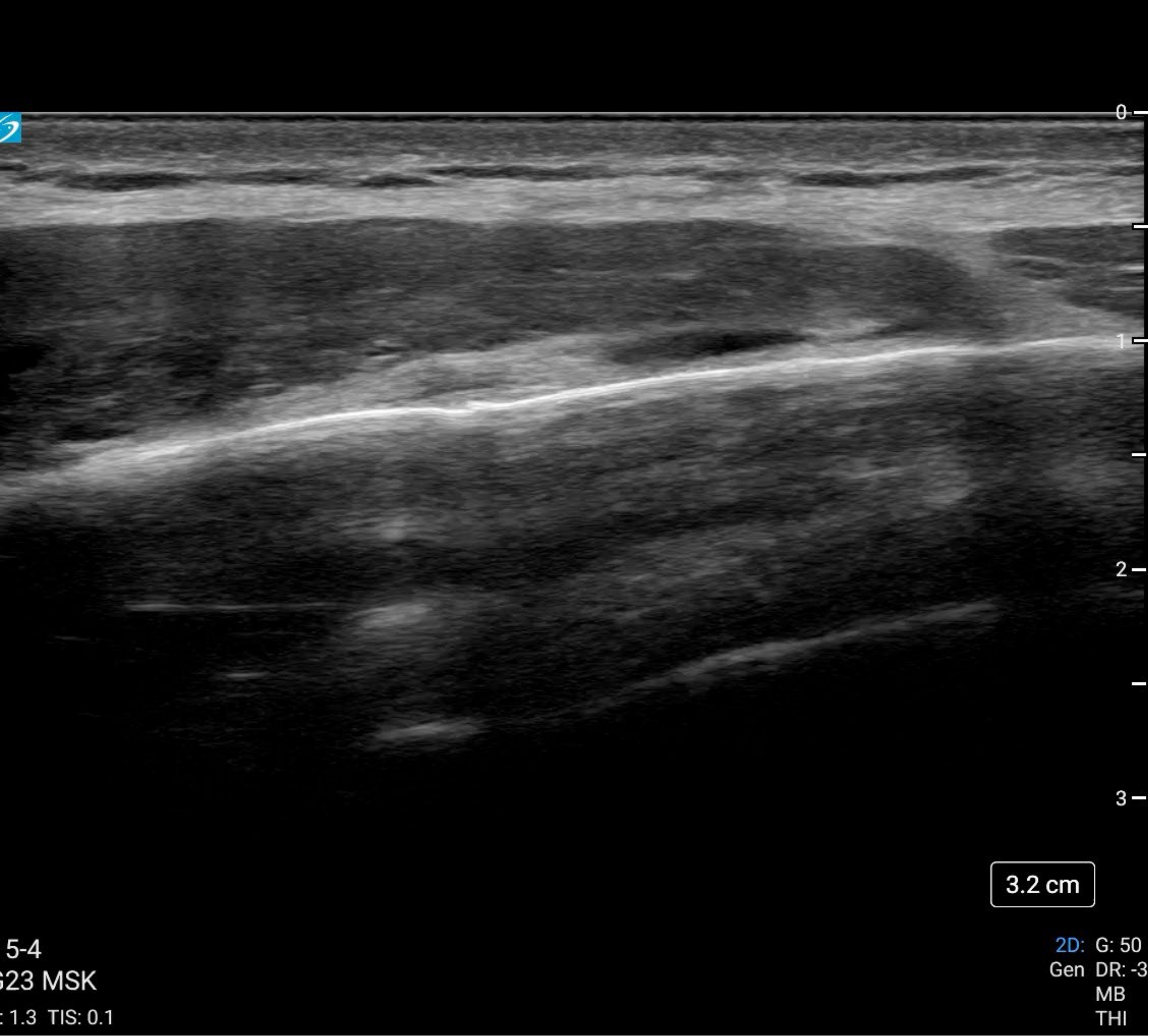

Dual



Centerline





Break

- Is the bone angled?
- Is the bone discontinuous?

Osteophyte

- Is there a bony prominence near an articulation?

Uneven cortex/articulation

- Is there a large defect in the bone?
- Is there an abnormal articulation?

Enthesis

- Is there an irregular bony surface where the tendon or ligament attaches?

Hypoechoic/anechoic

Occupying a space

- Is it pushing soft tissue away?
- I.e. stretching a joint capsule or pushing away a fat pad?

2 Questions

1. Is the fluid Free or Contained?
2. Is the fluid Simple or Complex?

Thickness

- Is the tissue thickened or thinned?

Irregular

- Is there an irregular shape of the tendon/ligament?

Same

- Is the tissue the same as the other side?

Signal of doppler

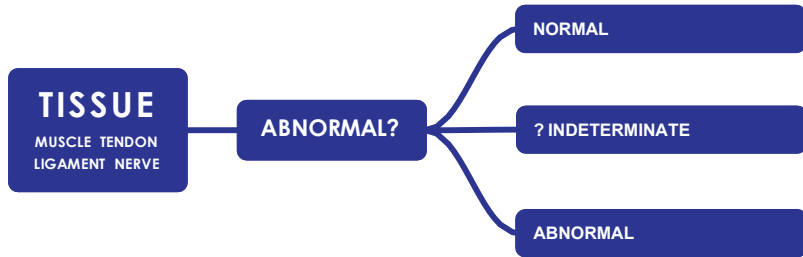
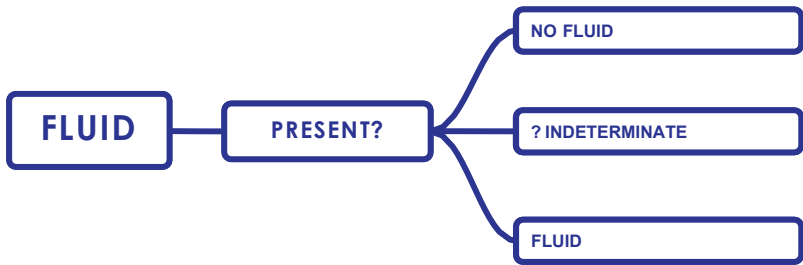
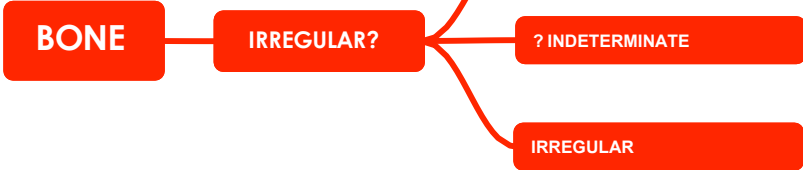
- Is the doppler signal high?

Unusual fibers

- Are the fibers unusual or discontinuous?

Echogenicity

- Is the tissue hyperechoic, hypoechoic or anechoic?



CBD

Calcium

- Linear or pinpoint
- Oval or round
- Dimensions in mm

Bony irregularity

- Small area
- Large area
- Dimensions in mm

Doppler

- Low, medium, or high

THC

Thickness

- Compared to contralateral side
- Dimensions in mm

Heterogeneity

- Homogenous
- Heterogenous

Colour

- Hypo vs Hyperechoic
- Is there anisotropy?

LSD

Location

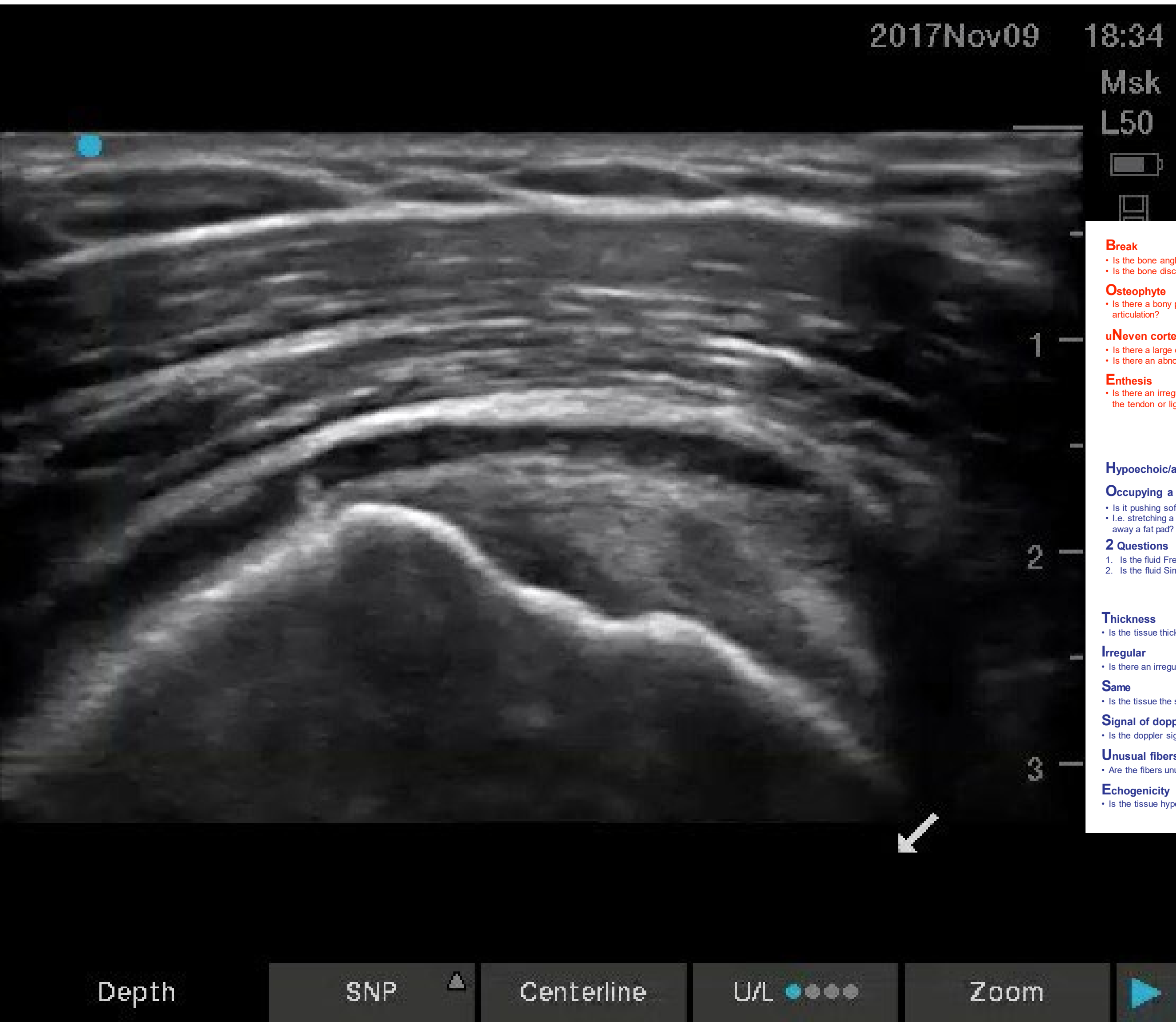- Superficial or Deep
- Anterior or Posterior
- Medial or Lateral

Shape

- Linear
- Curved
- Irregular

Dimensions

- in mm



Break

- Is the bone angled?
- Is the bone discontinuous?

Osteophyte

- Is there a bony prominence near an articulation?

Uneven cortex/articulation

- Is there a large defect in the bone?
- Is there an abnormal articulation?

Enthesis

- Is there an irregular bony surface where the tendon or ligament attaches?

Hypoechoic/anechoic

Occupying a space

- Is it pushing soft tissue away?
- I.e. stretching a joint capsule or pushing away a fat pad?

2 Questions

1. Is the fluid Free or Contained?
2. Is the fluid Simple or Complex?

Thickness

- Is the tissue thickened or thinned?

Irregular

- Is there an irregular shape of the tendon/ligament?

Same

- Is the tissue the same as the other side?

Signal of doppler

- Is the doppler signal high?

Unusual fibers

- Are the fibers unusual or discontinuous?

Echogenicity

- Is the tissue hyperechoic, hypoechoic or anechoic?

BONE

IRREGULAR?

REGULAR

? INDETERMINATE

IRREGULAR

FLUID

PRESENT?

NO FLUID

? INDETERMINATE

FLUID

TISSUE

MUSCLE TENDON
LIGAMENT NERVE

ABNORMAL?

NORMAL

? INDETERMINATE

ABNORMAL

CBD

Calcium

- Linear or pinpoint
- Oval or round
- Dimensions in mm

Bony irregularity

- Small area
- Large area
- Dimensions in mm

Doppler

- Low, medium, or high

THC

Thickness

- Compared to contralateral side
- Dimensions in mm

Heterogeneity

- Homogenous
- Heterogenous

Colour

- Hypo vs Hyperechoic
- Is there anisotropy?

LSD

Location

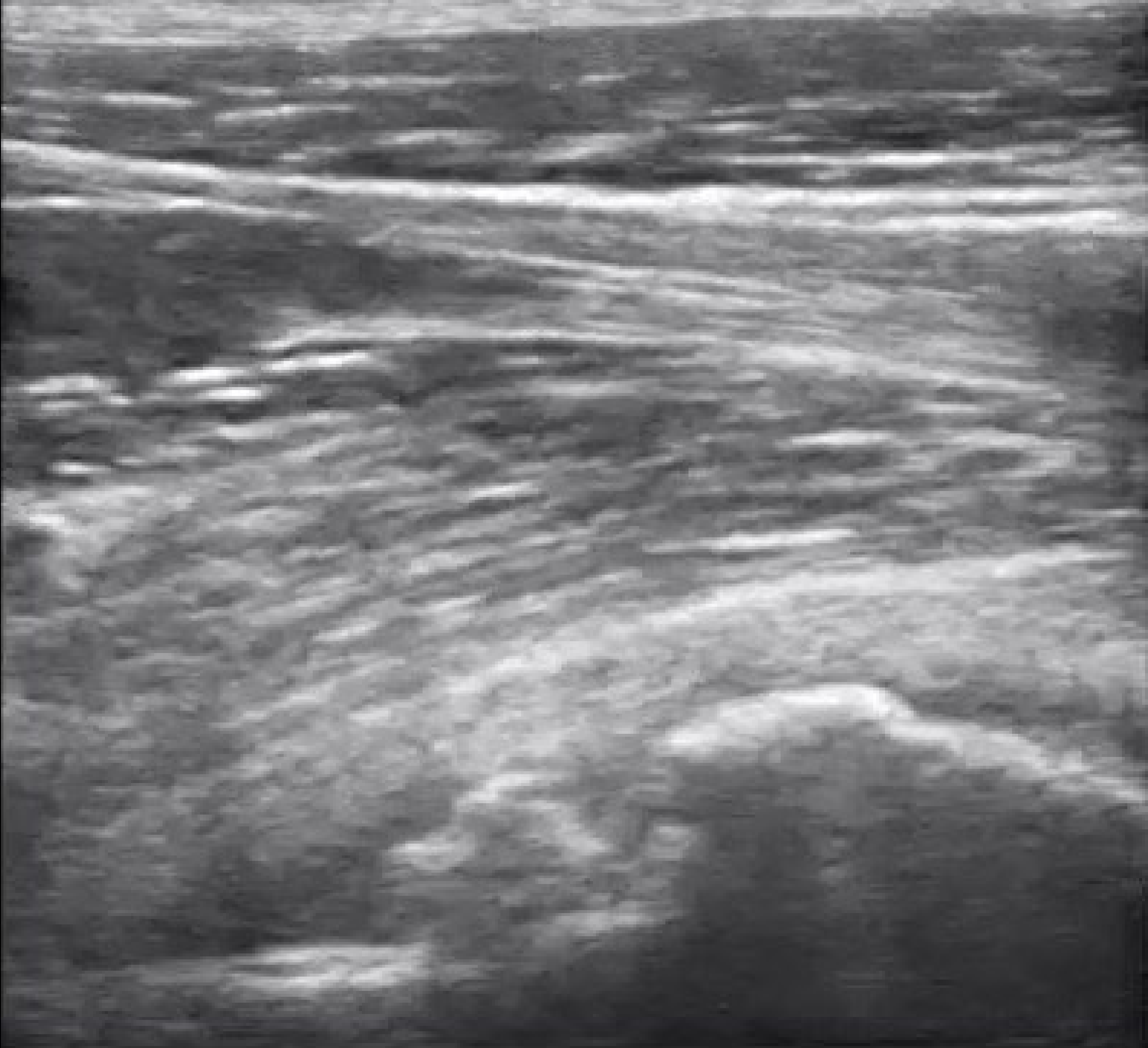
- Superficial or Deep
- Anterior or Posterior
- Medial or Lateral

Shape

- Linear
- Curved
- Irregular

Dimensions

- in mm



Break

- Is the bone angled?
- Is the bone discontinuous?

Osteophyte

- Is there a bony prominence near an articulation?

UnEven cortex/articulation

- Is there a large defect in the bone?
- Is there an abnormal articulation?

Enthesis

- Is there an irregular bony surface where the tendon or ligament attaches?

Hypoechoic/anechoic

Occupying a space

- Is it pushing soft tissue away?
- I.e. stretching a joint capsule or pushing away a fat pad?

2 Questions

1. Is the fluid Free or Contained?
2. Is the fluid Simple or Complex?

Thickness

- Is the tissue thickened or thinned?

Irregular

- Is there an irregular shape of the tendon/ligament?

Same

- Is the tissue the same as the other side?

Signal of doppler

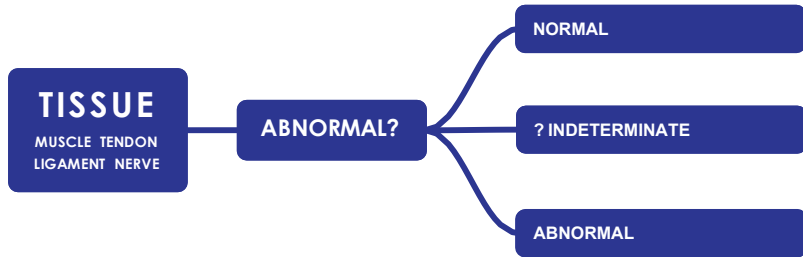
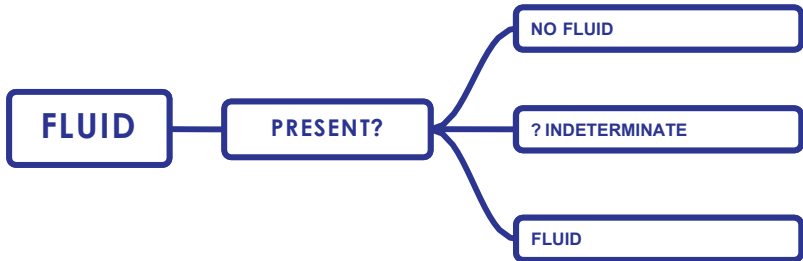
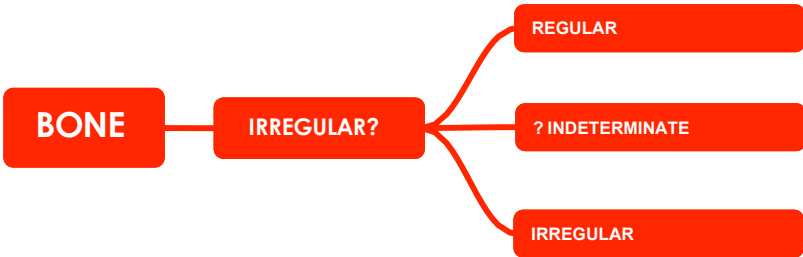
- Is the doppler signal high?

Unusual fibers

- Are the fibers unusual or discontinuous?

Echogenicity

- Is the tissue hyperechoic, hypoechoic or anechoic?



CBD

Calcium

- Linear or pinpoint
- Oval or round
- Dimensions in mm

Bony irregularity

- Small area
- Large area
- Dimensions in mm

Doppler

- Low, medium, or high

THC

Thickness

- Compared to contralateral side
- Dimensions in mm

Heterogeneity

- Homogenous
- Heterogenous

Colour

- Hypo vs Hyperechoic
- Is there anisotropy?

LSD

Location

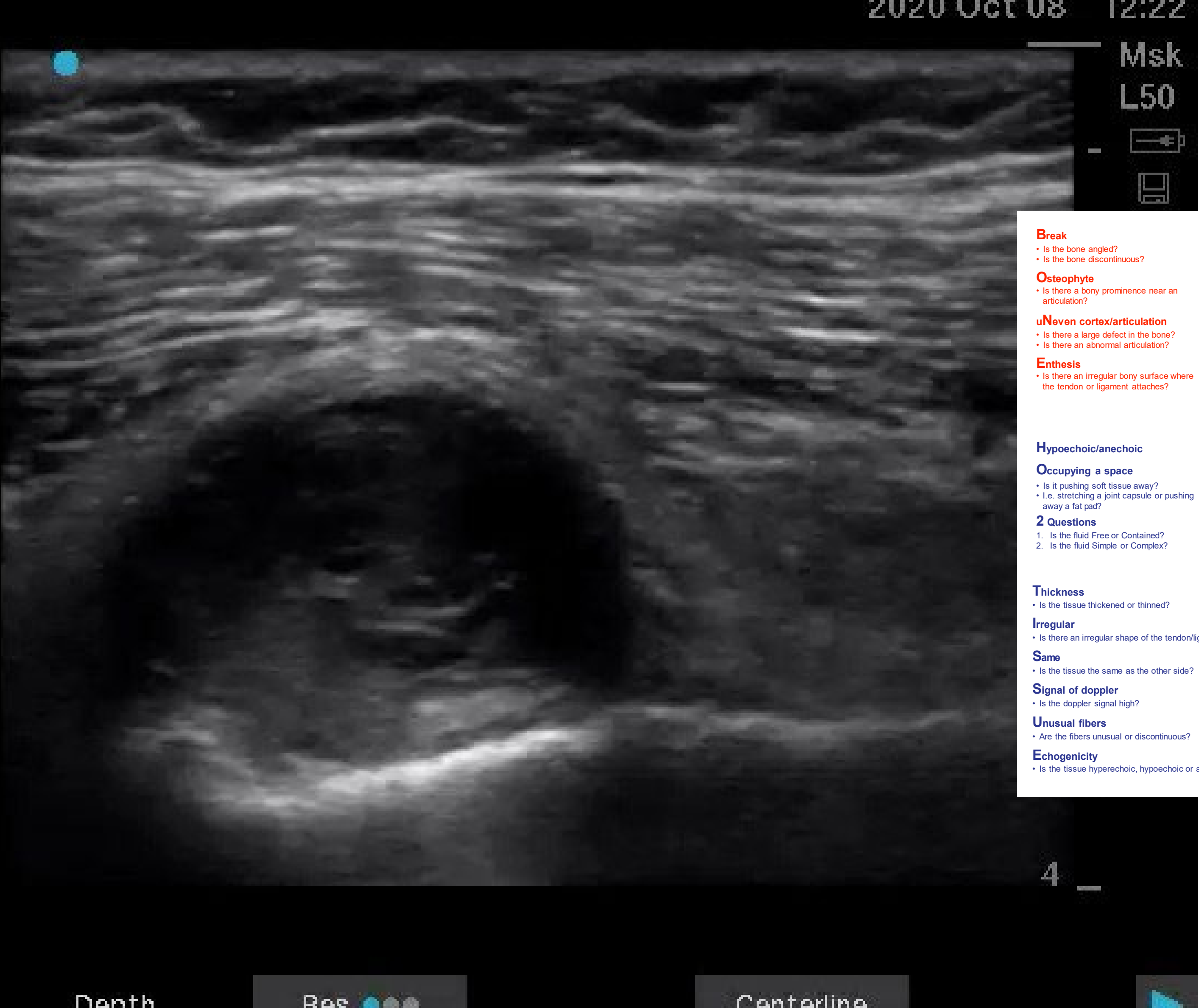
- Superficial or Deep
- Anterior or Posterior
- Medial or Lateral

Shape

- Linear
- Curved
- Irregular

Dimensions

- in mm



Break

- Is the bone angled?
- Is the bone discontinuous?

Osteophyte

- Is there a bony prominence near an articulation?

UnEven cortex/articulation

- Is there a large defect in the bone?
- Is there an abnormal articulation?

Enthesis

- Is there an irregular bony surface where the tendon or ligament attaches?

Hypoechoic/anechoic

Occupying a space

- Is it pushing soft tissue away?
- I.e. stretching a joint capsule or pushing away a fat pad?

2 Questions

1. Is the fluid Free or Contained?
2. Is the fluid Simple or Complex?

Thickness

- Is the tissue thickened or thinned?

Irregular

- Is there an irregular shape of the tendon/ligament?

Same

- Is the tissue the same as the other side?

Signal of doppler

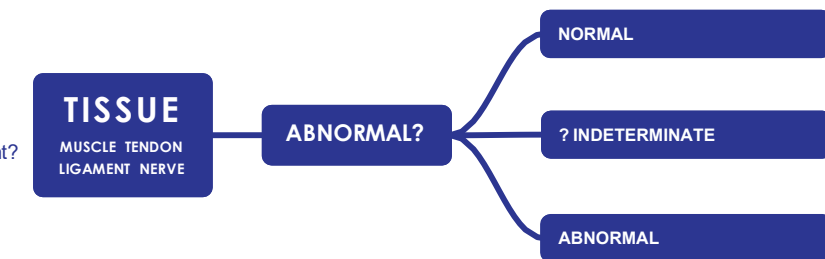
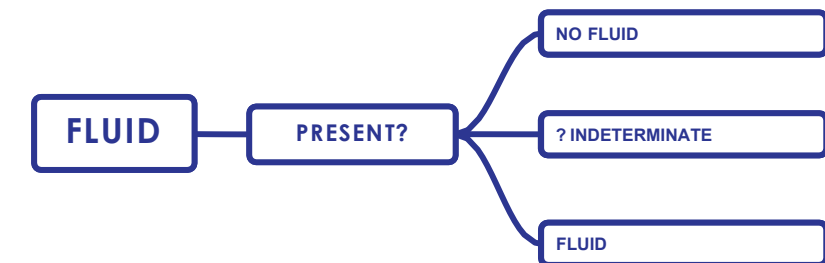
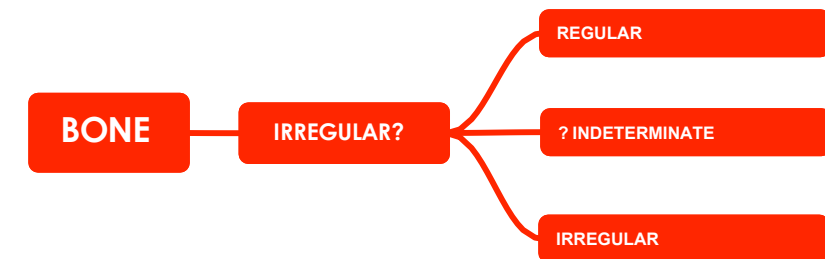
- Is the doppler signal high?

Unusual fibers

- Are the fibers unusual or discontinuous?

Echogenicity

- Is the tissue hyperechoic, hypoechoic or anechoic?



CBD

Calcium

- Linear or pinpoint
- Oval or round
- Dimensions in mm

Bony irregularity

- Small area
- Large area
- Dimensions in mm

Doppler

- Low, medium, or high

THC

Thickness

- Compared to contralateral side
- Dimensions in mm

Heterogeneity

- Homogenous
- Heterogenous

Colour

- Hypo vs Hyperechoic
- Is there anisotropy?

LSD

Location

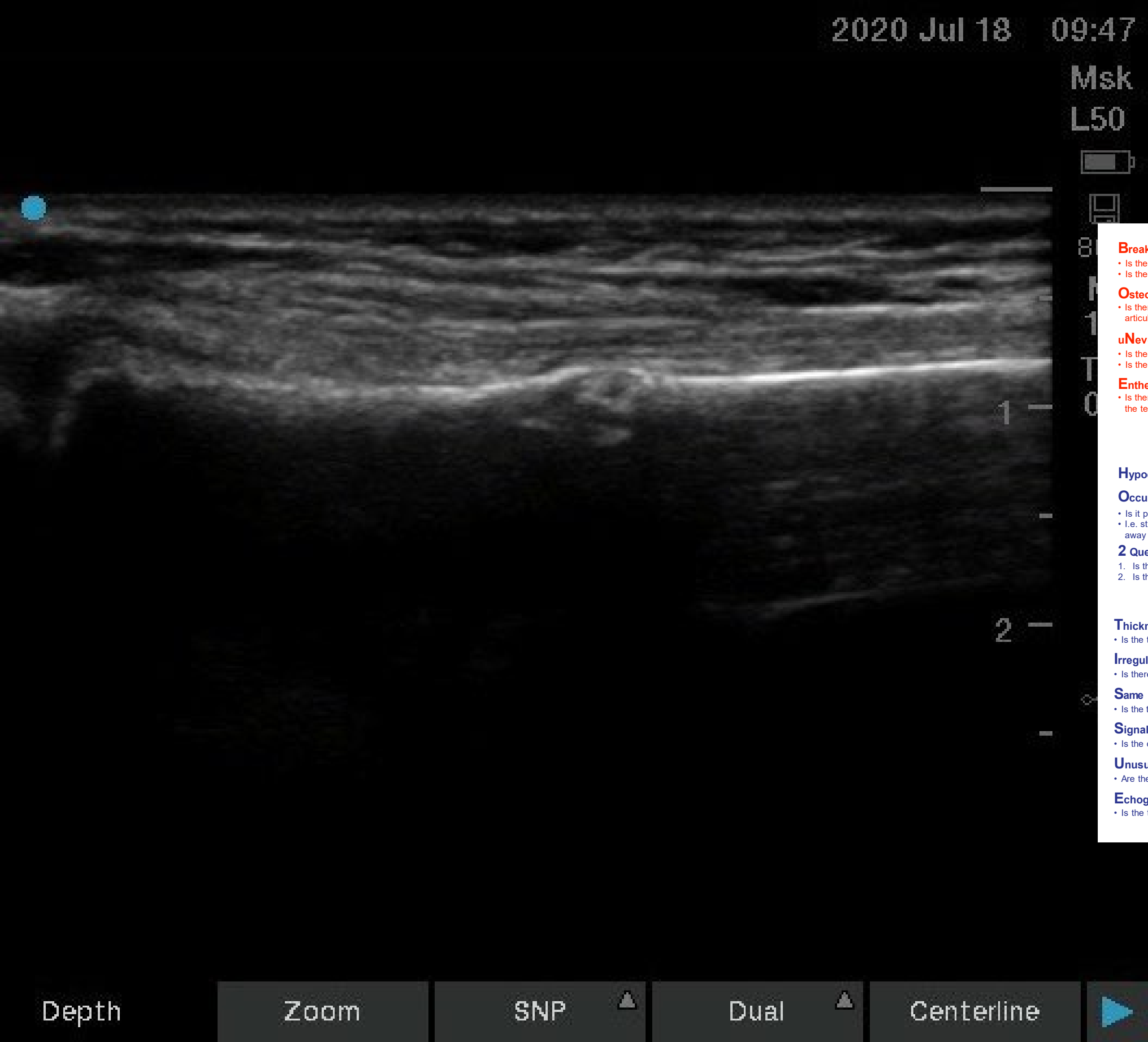- Superficial or Deep
- Anterior or Posterior
- Medial or Lateral

Shape

- Linear
- Curved
- Irregular

Dimensions

- in mm



Break

- Is the bone angled?
- Is the bone discontinuous?

Osteophyte

- Is there a bony prominence near an articulation?

UnEven cortex/articulation

- Is there a large defect in the bone?
- Is there an abnormal articulation?

Enthesis

- Is there an irregular bony surface where the tendon or ligament attaches?

Hypoechoic/anechoic

Occupying a space

- Is it pushing soft tissue away?
- I.e. stretching a joint capsule or pushing away a fat pad?

2 Questions

1. Is the fluid Free or Contained?
2. Is the fluid Simple or Complex?

Thickness

- Is the tissue thickened or thinned?

Irregular

- Is there an irregular shape of the tendon/ligament?

Same

- Is the tissue the same as the other side?

Signal of doppler

- Is the doppler signal high?

Unusual fibers

- Are the fibers unusual or discontinuous?

Echogenicity

- Is the tissue hyperechoic, hypoechoic or anechoic?

BONE

IRREGULAR?

REGULAR

? INDETERMINATE

IRREGULAR

FLUID

PRESENT?

NO FLUID

? INDETERMINATE

FLUID

TISSUE

MUSCLE TENDON
LIGAMENT NERVE

ABNORMAL?

NORMAL

? INDETERMINATE

ABNORMAL

CBD

Calcium

- Linear or pinpoint
- Oval or round
- Dimensions in mm

Bony irregularity

- Small area
- Large area
- Dimensions in mm

Doppler

- Low, medium, or high

THC

Thickness

- Compared to contralateral side
- Dimensions in mm

Heterogeneity

- Homogenous
- Heterogenous

Colour

- Hypo vs Hyperechoic
- Is there anisotropy?

LSD

Location

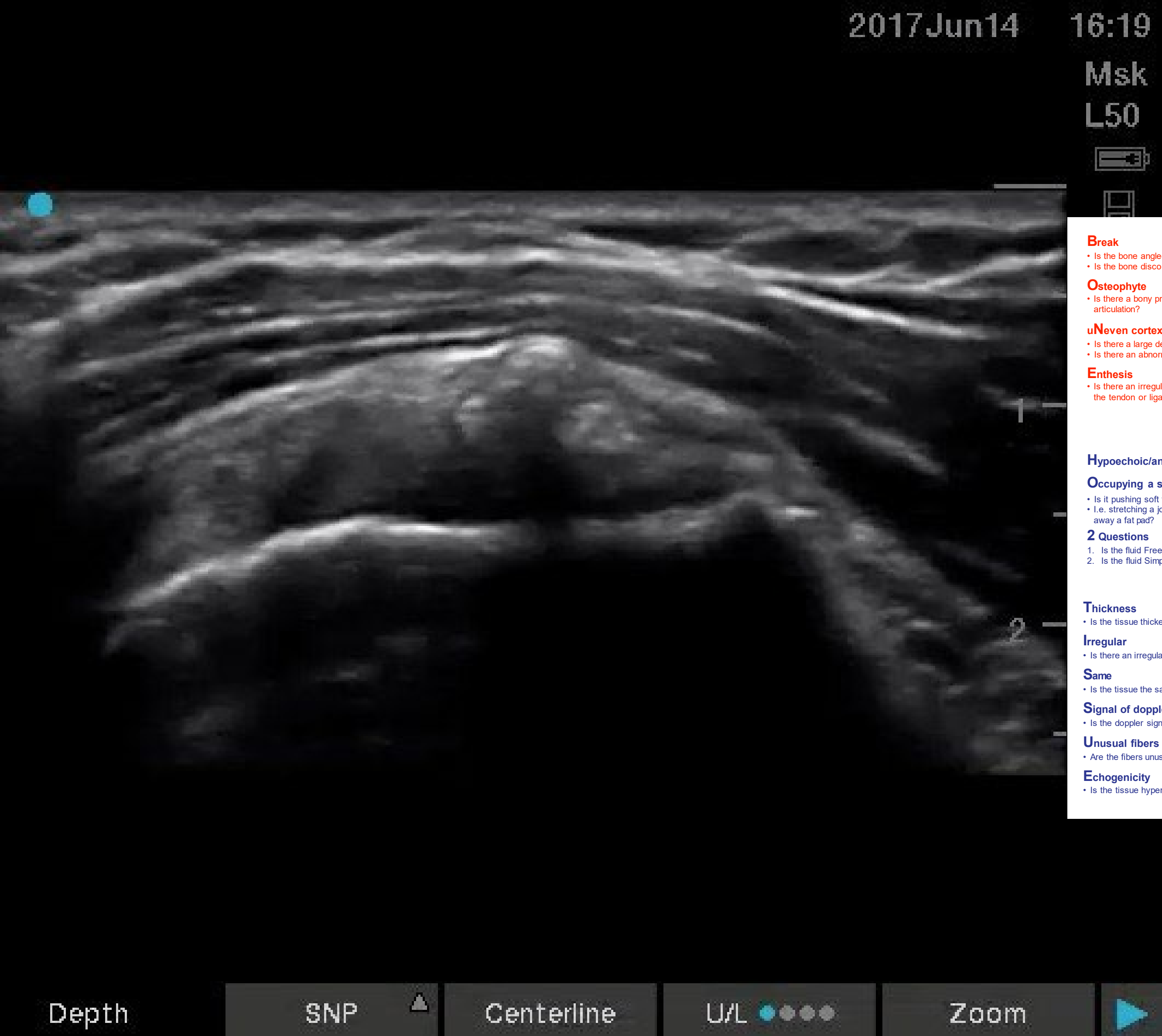- Superficial or Deep
- Anterior or Posterior
- Medial or Lateral

Shape

- Linear
- Curved
- Irregular

Dimensions

- in mm



Break

- Is the bone angled?
- Is the bone discontinuous?

Osteophyte

- Is there a bony prominence near an articulation?

Uneven cortex/articulation

- Is there a large defect in the bone?
- Is there an abnormal articulation?

Enthesis

- Is there an irregular bony surface where the tendon or ligament attaches?

Hypoechoic/anechoic

Occupying a space

- Is it pushing soft tissue away?
- I.e. stretching a joint capsule or pushing away a fat pad?

2 Questions

1. Is the fluid Free or Contained?
2. Is the fluid Simple or Complex?

Thickness

- Is the tissue thickened or thinned?

Irregular

- Is there an irregular shape of the tendon/ligament?

Same

- Is the tissue the same as the other side?

Signal of doppler

- Is the doppler signal high?

Unusual fibers

- Are the fibers unusual or discontinuous?

Echogenicity

- Is the tissue hyperechoic, hypoechoic or anechoic?

BONE

IRREGULAR?

REGULAR

? INDETERMINATE

IRREGULAR

FLUID

PRESENT?

NO FLUID

? INDETERMINATE

FLUID

TISSUE

MUSCLE TENDON
LIGAMENT NERVE

ABNORMAL?

NORMAL

? INDETERMINATE

ABNORMAL

CBD

Calcium

- Linear or pinpoint
- Oval or round
- Dimensions in mm

Bony irregularity

- Small area
- Large area
- Dimensions in mm

Doppler

- Low, medium, or high

THC

Thickness

- Compared to contralateral side
- Dimensions in mm

Heterogeneity

- Homogenous
- Heterogenous

Colour

- Hypo vs Hyperechoic
- Is there anisotropy?

LSD

Location

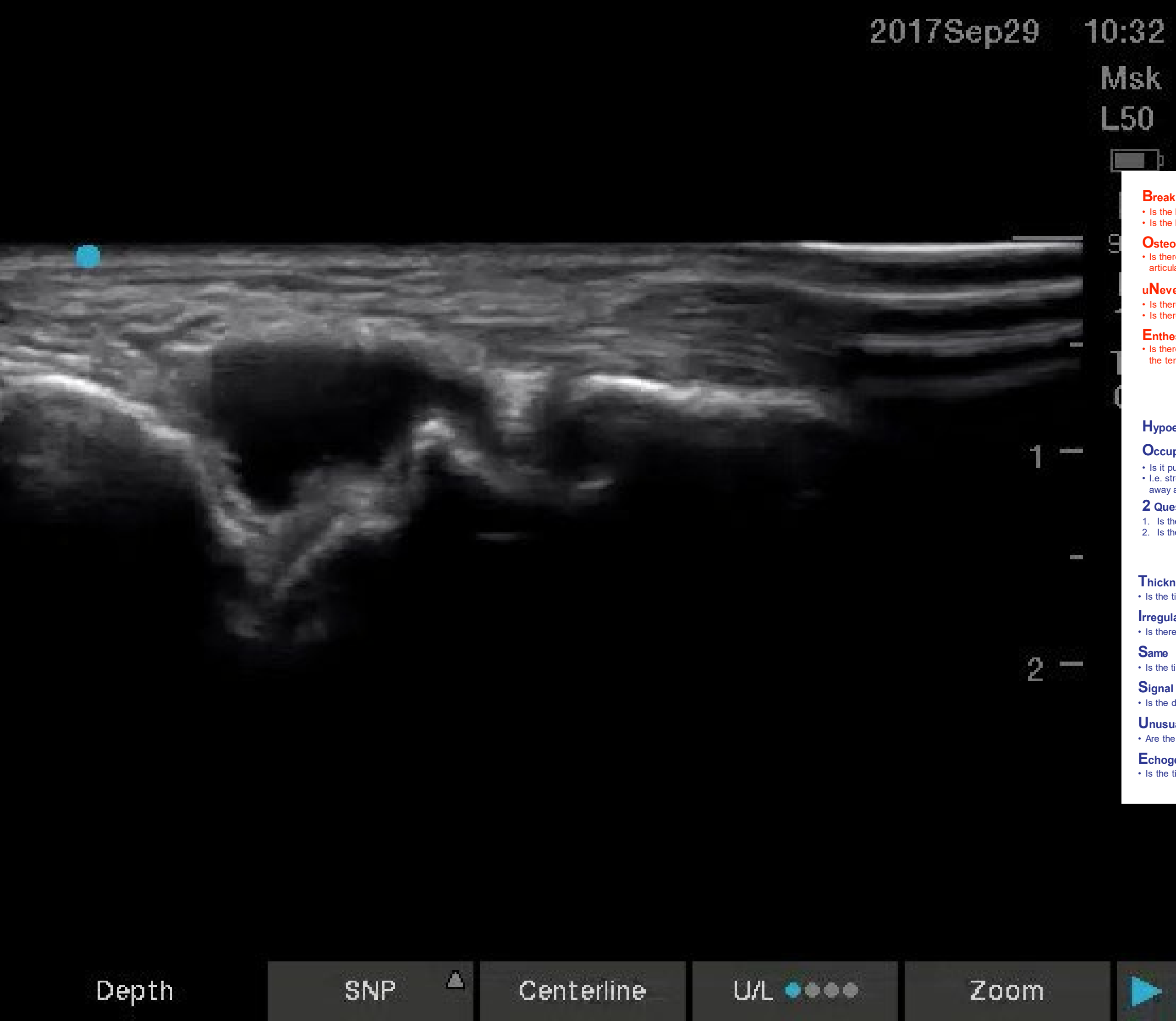- Superficial or Deep
- Anterior or Posterior
- Medial or Lateral

Shape

- Linear
- Curved
- Irregular

Dimensions

- in mm



Break

- Is the bone angled?
- Is the bone discontinuous?

Osteophyte

- Is there a bony prominence near an articulation?

UnEven cortex/articulation

- Is there a large defect in the bone?
- Is there an abnormal articulation?

Enthesis

- Is there an irregular bony surface where the tendon or ligament attaches?

Hypoechoic/anechoic

Occupying a space

- Is it pushing soft tissue away?
- I.e. stretching a joint capsule or pushing away a fat pad?

2 Questions

1. Is the fluid Free or Contained?
2. Is the fluid Simple or Complex?

Thickness

- Is the tissue thickened or thinned?

Irregular

- Is there an irregular shape of the tendon/ligament?

Same

- Is the tissue the same as the other side?

Signal of doppler

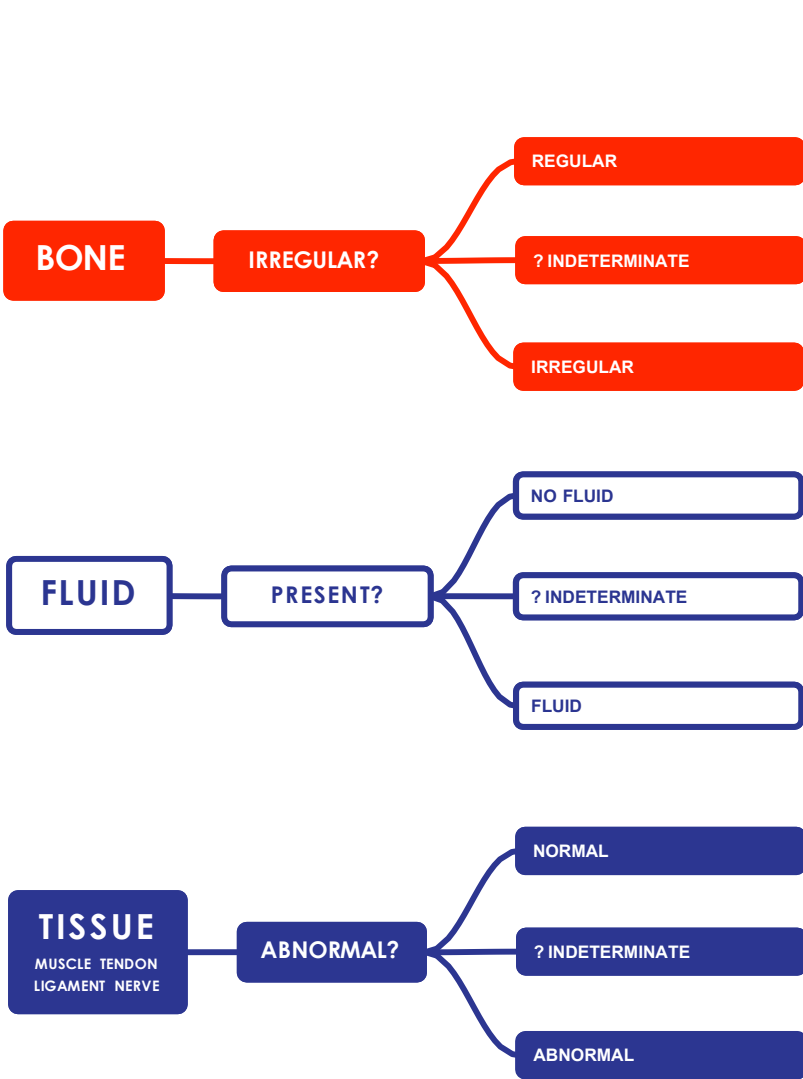
- Is the doppler signal high?

Unusual fibers

- Are the fibers unusual or discontinuous?

Echogenicity

- Is the tissue hyperechoic, hypoechoic or anechoic?



CBD

Calcium

- Linear or pinpoint
- Oval or round
- Dimensions in mm

Bony irregularity

- Small area
- Large area
- Dimensions in mm

Doppler

- Low, medium, or high

THC

Thickness

- Compared to contralateral side
- Dimensions in mm

Heterogeneity

- Homogenous
- Heterogenous

Colour

- Hypo vs Hyperechoic
- Is there anisotropy?

LSD

Location

- Superficial or Deep
- Anterior or Posterior
- Medial or Lateral

Shape

- Linear
- Curved
- Irregular

Dimensions

- in mm



Ultrasound is best
used when there is:

A superficial target

A specific question